

Survey of polycystic kidney disease and other urinary tract abnormalities using ultrasonography in Persian and Persian related cats in Iran

Parinaz Tavasolian¹, Masoud Rajabioun^{2*}, Hamideh Salari Sedigh², Mohammad Azizzadeh²

¹ DVM graduate, Faculty of Veterinary Medicine, Ferdowsi University of Mashhad, Mashhad, Iran; ² Department of Clinical Sciences, Faculty of Veterinary Medicine, Ferdowsi University of Mashhad, Mashhad, Iran.

Article Info

Article history:

Received: 17 October 2016
Accepted: 07 November 2017
Available online: 15 June 2018

Key words:

Iran, Persian cat
Polycystic kidney disease
Ultrasonography
Urinary tract

Abstract

Ultrasonography is an accurate and accessible method for detecting polycystic kidney disease (PKD), an inherited autosomal dominant disease, and other urinary tract diseases. The present work is a preliminary study of PKD and urinary tract abnormalities using ultrasonography in Persian and other long hair cats in Iran. This study was conducted on 83 cats including 68 Persian cats and 15 Persian related cats from December 2013 to March 2015. The age of cats ranged 3 to 72 months. Cats were classified as PKD-positive when at least one renal cyst was observed. Other urinary system abnormalities were recorded ultrasonographically. Association of personal and nutritional characteristics with PKD and other urinary tract disease detected by ultrasonography was statistically analyzed. The prevalence of PKD among Persian cats and in the total population was 33.80% and 31.30%, respectively. PKD was more prevalent among male cats compared to those in female cats. PKD occurrence was significantly more among cats fed by commercial dry foods compared to those fed by homemade foods. There was no significant association between PKD and age, hair color, eye color, related clinical signs and other kidney abnormalities in ultrasonographic findings. The prevalence of renal calculi, urine sediments and bladder calculus were 2.40%, 32.80% and 3.60%, respectively. Urine sediments were significantly raised with increasing age. Screening program is essential for on-time diagnosis of PKD and to plan therapeutic management and control of the disease.

© 2018 Urmia University. All rights reserved.

مطالعه مقدماتی بیماری کلیه پلی کیستیک و دیگر ناهنجاری‌های مجاری ادراری با استفاده از اولتراسونوگرافی در گربه‌های نژاد پرشین و وابسته به پرشین در ایران

چکیده

اولتراسونوگرافی یک روش دقیق و قابل دسترس برای شناسایی بیماری کلیه پلی کیستیک، بیماری اتوزومال غالب توارثی، و دیگر بیماری‌های مجاری ادراری است. مطالعه حاضر، یک بررسی مقدماتی در مورد بیماری کلیه پلی کیستیک و دیگر ناهنجاری‌های دستگاه ادراری قابل شناسایی با اولتراسونوگرافی در گربه‌های نژاد پرشین و دیگر نژادهای گربه مو بلند در ایران می باشد. تعداد ۸۳ قلابه گربه شامل ۶۸ قلابه گربه نژاد پرشین و ۱۵ قلابه گربه نژاد وابسته به پرشین از آذرماه ۱۳۹۲ تا اسفند ماه ۱۳۹۳ مورد بررسی قرار گرفتند. گربه‌ها در دامنه سنی ۳ تا ۷۲ ماه بودند. در صورت شناسایی حداقل یک کیست در کلیه، گربه‌ها از نظر بیماری کلیه پلی کیستیک مثبت در نظر گرفته شدند. دیگر ناهنجاری‌های دستگاه ادراری قابل شناسایی با اولتراسونوگرافی نیز در صورت وجود ثبت گردید. ارتباط بین اطلاعات فردی و تغذیه‌ای با بیماری کلیه پلی کیستیک و دیگر موارد غیرطبیعی قابل شناسایی با اولتراسونوگرافی مورد آنالیز آماری قرار گرفت. شیوع بیماری کلیه پلی کیستیک بین گربه‌های نژاد پرشین و در کل جمعیت مورد مطالعه به ترتیب ۳۳/۸۰ و ۳۱/۳۰ درصد بود. بیماری کلیه پلی کیستیک در بین گربه‌های نر شیوع بالاتری را نشان داد. رخداد بیماری کلیه پلی کیستیک در گربه‌هایی که با غذای تجاری تغذیه می‌شدند بطور معنی داری بیشتر از گربه‌هایی بود که با غذای خانگی تغذیه شده بودند. ارتباط آماری بین حضور کیست در کلیه‌ها با سن، رنگ مو، رنگ چشم و علائم بالینی مرتبط و همچنین دیگر ناهنجاری‌های دستگاه ادراری شناسایی شده با اولتراسونوگرافی مشاهده نشد. فراوانی رخداد سنگ کلیه، رسوب ادراری و سنگ مثانه به ترتیب ۲/۴۰، ۳۲/۸۰ و ۳/۶۰ درصد مشاهده شد. رسوبات ادراری بطور معنی داری با افزایش سن به میزان بیشتری شناسایی شد. برنامه غربالگری بیماری برای تشخیص به موقع، اعمال مدیریت درمانی مناسب یا کنترل بیماری ضروری است.

واژه های کلیدی: ایران، گربه پرشین، بیماری کلیه پلی کیستیک، اولتراسونوگرافی، مجاری ادراری

*Correspondence:

Masoud Rajabioun, DVM, DVSc
Department of Clinical Sciences, Faculty of Veterinary Medicine, Ferdowsi University of Mashhad, Mashhad, Iran.
E-mail: rajabioun@um.ac.ir



This work is licensed under a Creative Commons Attribution-NonCommercial 4.0 International License which allows users to read, copy, distribute and make derivative works for non-commercial purposes from the material, as long as the author of the original work is cited properly.

Introduction

Polycystic kidney disease (PKD), an autosomal dominant hereditary disease, has been mostly recognized in Persian cats and long-haired cats with the prevalence of 37.00% to 49.00%; multiple areas of the parenchymal cysts are presented at the birth which increases with age and depending on the number and size of cysts may result in a significant loss of kidney function.¹⁻³ This condition is often detectable in the kittens aged 6 to 8 weeks, but may also be diagnosed later.⁴ The PKD could be unilateral or bilateral and liver cysts might present at the same time.⁵ Kittens with severe cyst involvement may die at the age of 8 weeks due to the kidney failure; however, the disease is usually subclinical until they are middle-age or older.⁴

Ultrasonography is currently the most useful non-invasive method for the diagnosis of this complication.⁶ The specificity of the ultrasonography for diagnosis of cysts is 100%; however, sensitivity increases with age as it was reported to be 91.00% in cats over nine months. Despite identifiable cysts in ultrasonography, cats in the early stages of the disease do not have any abnormal clinical and laboratory findings. Therefore, using ultrasonography for early detection of PKD is recommended.^{1,7}

Knowing the prevalence and incidence of the disease in the cat population is important in order to identify potential causes, reduce the number of involved cats and ideally eradicate the disease.^{8,9} Several studies have been carried out on the prevalence of PKD all over the world.^{4,8-14} Bonazzi *et al.* identified other complications of urinary tract beside PKD by ultrasonography.⁹

The aim of the present study was to evaluate the prevalence of PKD and other urinary diseases detectable using ultrasonography among Persian and Persian related cats. The possible links between the disease and individual and nutritional characteristics were also investigated.

Materials and Methods

Animals. This cross-sectional study was performed on 83 cats including 68 Persian cats and 15 Persian related cats referred to the Veterinary Teaching Hospital, Faculty of Veterinary Medicine, Ferdowsi University of Mashhad from December 2013 to March 2015 for a routine examination. The study was fully described for the cat owners in order to respect the rights of owners. After taking an informed consent, the animals were included in the study. Cats were physically examined and their clinical signs and medical history were recorded. The breed, age, weight, eye color, hair color and type of diet of examined cats and information about the owners of the animals were also recorded. Cats were divided into Persian and Persian related groups. Based on their age, cats were classified in three age groups: < 1-year, 1 - 2 year, > 2 year.

Type of the diet was recorded as commercial dry food, homemade foods and a combination of commercial dry food and homemade foods. The protocol and procedures employed in this work was conducted in accordance with the National Institutes of Health Guide for the Care and Use of Animals.

Ultrasonography. Ultrasonographic evaluation of urinary tract of cats was performed using ultrasound machine with 7.5 and 10 MHz linear transducer (Mindray DP 6600; Mindray, Szechuan, China). The cats were manually restrained by their owners in dorsal recumbency and their hair coat was clipped. Alcohol and ultrasonic coupling gel applied on the skin and then kidneys echogenicity and echotexture were examined in longitudinal and transverse planes. Cats with one or more clearly defined, spherical, smooth-walled anechoic cysts in one or both kidneys were considered as PKD positive. In cats with one cyst, eight months later ultrasonography was repeated for evaluation the number of cysts. Cyst location, any abnormal echogenicity indicating the presence of renal calculi, calcification and other abnormalities, presence of medullary rim sign (MRS; a hyperechoic band at the corticomedullary junction) and any defect in renal pelvis were recorded. The urinary bladder wall and its content was also evaluated in longitudinal and transverse planes.

Statistical analysis. Data were analyzed using SPSS software version 21 (IBM Corp., Armonk, USA). Chi-Square and Fisher's exact tests were used to examine association between variables with PKD an. A *p* value < 0.05 was considered statistically significant. Odds ratios (ORs) and their 95.00% confidence interval (95.00 % CI) were calculated for each risk factor in univariate analysis.

Results

Characteristics of study population. In this study 83 Persian and Persian related long hair cats were evaluated. A number of 68 cats were Persian (81.93%), 15 cats were Persian related cats (18.07%). Forty-four cats (53.01%) were male and 39 cats (46.99%) were female. The mean age of cats was 21.80 ± 13.05 months, ranged 3 - 72 months); of those 20 (24.10%), 39 (46.99%) and 24 cats (28.91%) were < 1-year, 1 - 2 year and > 2 year, respectively. The weight of cats ranged between 1.70 - 5.65 kg with the mean weight of 3.41 ± 0.80 kg. Based on diet, 13 cats (15.66%), 57 cats (68.68%) and 13 cats (15.66%), were fed by homemade food, commercial dry food and a combination of homemade and commercial foods, respectively.

Prevalence of PKD, individual and nutritional characteristics. The PKD was diagnosed in both kidneys of 26 cats bilaterally (Fig. 1A). The prevalence of PKD was 31.30% among the examined cats (CI: 95% 21.30 - 41.30).

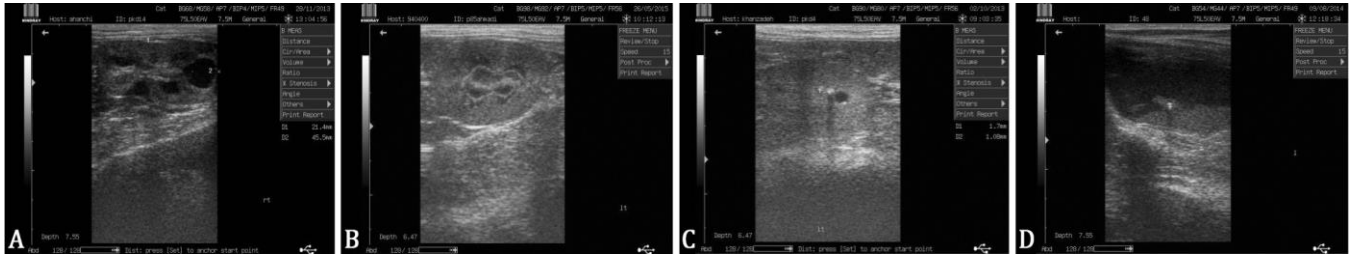


Fig. 1. Ultrasonographic images of urinary system abnormalities in the examined cats. A) Sagittal ultrasonographic image of the right kidney of a cat with PKD, four renal cysts were detected in cortex and medulla; B) Sagittal image of the left kidney represented MRS as a hyperechoic line between cortex and medulla; C) Transverse image of the left kidney, a small hyperechoic area with an apparent distal acoustic shadowing was imaged near the renal pelvic represented renal calculus, one small cyst was seen; D) Sagittal image of the urinary bladder, abnormal floating echogenic particles were seen in the dependent part of the urinary bladder. A small calculus with distal acoustic shadowing was imaged.

A number of 57 (68.70%) cats showed no renal cysts. In total, 22 cats (26.50%) had more than one cyst in their kidneys. Cats with one cyst in kidney was examined ultrasonographically about eight months later and showed more than one cyst in their kidney. The presence of the cysts in the cortex, medulla, and cortex-medulla of PKD positive cats were 40.39%, 1.92% and 57.69%, respectively. The PKD was significantly more prevalent among male cats compared to those in female cats ($p = 0.04$, OR = 2.68). A significant positive association was found between PKD and the type of diet, in which the PKD prevalence was 14.05 times more common among cats fed by commercial dry food than in those fed by homemade foods ($p = 0.03$, OR = 14.05). No significant association was observed between PKD and breed, age, weight, eye color and hair color of cats (Table 1).

Table 1. Analysis of the variables related to the cats with PKD.

Variable	Number (%)	p-value
Age (months)		
< 1 year	9(45.00)	0.305
1 - 2 year	10(25.60)	
> 2 year	7(29.20)	
Gender		
Male	18(40.90)	0.046*
Female	8(20.50)	
Breed of cat		
Persian	23(33.80)	0.695
Persian related	3(20.00)	
Type of diet		
Homemade food	0(0.00)	0.036*
Commercial dry food	20(35.10)	
Commercial + homemade foods	6(46.20)	
Cyst location		
Cortex	21(40.39)	0.036*
Medulla	1(1.92)	
Cortex-medulla	30(57.69)	
Related clinical sign		
Positive	1(3.85)	0.046*
Negative	25(95.15)	
Uni/bilateral		
Bilateral	26(100)	0.046*
Unilateral	0(0.00)	

* Asterisk represents statistically significant difference ($p < 0.05$).

Clinical signs. A total of 81 cats (97.60%) had no clinical manifestations, whereas only two cats (2.40%) were referred with clinical signs and the renal cysts were detected in only one case. Clinical signs in eight months old male Persian cat with PKD were vomiting and weight loss. However, the second cat with difficulty in passing urine was a 41 months old male Persian with no renal cysts in ultrasound examination. Renal calculi and urinary bladder crystals were diagnosed in this cat.

The MRS, renal calculus and urinary bladder sediment. The MRS was detected in three cats (3.81%) (Fig. 1B). Two cats had both renal cysts and MRS. However, no significant association was found between the presence of renal cysts and MRS ($p = 0.23$). Renal calculi were detected in two cats (2.40%) and there was no significant association between the presence of renal cysts and renal calculi (Fig. 1C). No statistical significant association was found between the presence of renal calculi and gender, breed, age, eye color, hair color, type of diet, clinical signs, MRS, bladder calculus and urine sediment in the examined cats.

Urine sediments were observed in 32 cats (38.55%). Urine sediments was observed in 38.50% of cats with renal cyst and 38.60% of cats without renal cysts (Fig. 1D). No significant association was observed between PKD and urine sediments. However, urine sediments were significantly associated with age of cats, in which urine sediments were more detectable in cats over two years old than those < 1-year-old ($p = 0.004$). Moreover, a higher percentage of cats aged 1 - 2 years had urine sediments compared to those aged less than 1 year ($p = 0.005$). 10%, 2.46% and 50.00% of cats less than 1 year, 1 - 2 years and more than 2 years showed urine sediments, respectively. No significant association was observed between urine sediments and breed, gender, type of diet, eye color and hair color of the examined cats.

Urinary bladder calculus was present in three cats (3.60%), none of them had PKD. There was no significant association between the presence of renal cysts and bladder calculus. The bladder wall was normal in all 83 cats.

Discussion

The PKD was first described as a familial disease of Persian cats by Crowell *et al.* in 1979.¹⁵ The disease may detect as kidney enlargement on physical examination or radiographic evaluation which is not specific for diagnosis of PKD. Ultrasound is an imaging modality of choice for evaluation of renal cysts.¹⁶ One cyst on in at least one kidney represented PKD positive cat.^{8,10,14} This criterion also has been used by the other similar studies and also was used in human studies.¹⁷ In the present study, the prevalence of PKD among Persian cats was 33.80%. Similar studies have been performed to estimate the prevalence of PKD over the world. The prevalence of PKD in cats of the United Kingdom, Germany, France, Italy, Slovenia and Australia were reported to be 49.20%, 43.00%, 41.80%, 41.00%, 36.00%, 43.00% and 45.00%, respectively.^{4,8-12,14} The PKD prevalence has been reported to be likely similar in different countries which could be due to the international movements of cats for the purposes of breeding.⁸ The prevalence of PKD could be affected by the false negative and false positive results. Detection of very small cysts is difficult even in ideal conditions. Moreover, due to the low echogenicity of the medulla compared to the cortex, detection of the cysts in medulla is more difficult than in cortex.^{4,10} The sensitivity of the ultrasound for the diagnosis of PKD in cats rises with increasing the age of cat due to cyst enlargement.^{4,8,10,18,19} It is recommended that cats less than 10 months old without any cysts in the ultrasound examination should be considered as PKD negative.⁴

In the present study, the prevalence of PKD was lower than other studies. The majority of PKD positive cats (84.61%) had more than one cyst in their kidneys at the time of examination. Cysts were observed in both kidneys of all PKD positive cats, mostly within both cortex and medulla of the kidneys. Bonazzi *et al.*, reported bilateral PKD in 98.50% of PKD-positive Persian and exotic shorthair cats in Italy. More than one cyst were detected in all PKD positive cases and most of the cysts were observed within cortex, medulla and between them.⁹ Two studies conducted on Persian cats in Australia revealed that the most of cats with PKD had several cysts in their kidneys.^{4,14}

In the present study, it was found that PKD was significantly more prevalent among male cats compared to females. This finding was not in agreement with the previous studies reporting no significant association between PKD prevalence and gender in the examined cats.^{4,9,11,14} Age of male cat was more than of the female cat in this study, it can be the possible cause because the cyst can be detected more easily in aged cat; Although this finding need to be investigated in large population.

The prevalence of PKD in cats fed by commercial dry foods was significantly higher than those fed by homemade foods. This factor should be studied in a larger

sample size of cats with more type of diets. The association between PKD in cats and diet has not been investigated in the published studies.

The prevalence of PKD did not differ among the age groups defined in this study. Cannon *et al.* demonstrated an inverse relationship between age and the prevalence of PKD. They pointed out that the death of cats in older ages because of the chronic renal failure reduces the older cat population involved with the disease and also on the other hand, lack of appropriate screening could increase the spread of disease at an early age because it is an inherited autosomal dominant disease.¹⁰ Bonazzi *et al.* reported that the prevalence of PKD among two age groups of Persian and exotic short-hair cats was not statistically significant.⁹

In the present study, 81 cats did not show any clinical symptoms associated with kidney disease except two cats with related clinical symptoms, of which one cat had PKD. In Beck *et al.* study in 2001, among 100 PKD positive cats, only one cat showed clinical symptoms related to the disease.¹⁴ Similarly, in a study on 22 cats with PKD, only a 10-year-old cat had symptoms associated with PKD.²⁰ In a study by Domanjko-Petrič *et al.*, among a total of 47 cats with PKD, 10 cats with the mean age of 12.20 years had clinical signs of the disease. Most of the PKD positive cats remain clinically normal until chronic renal failure was developed years later.¹¹ The average age of renal failure in Persian cats with PKD is seven years. Although cysts grow with increasing age, the cyst size is not associated with the degree of pressure on the connective tissue.²¹ Besides the absence of disease progression, the low age of study population could be the reason for why the large numbers of PKD positive cases have no clinical symptoms. Also, the rate of disease progression and clinical complications in patients with PKD could be different and unpredictable.¹⁰

The MRS is a hyperechoic line parallel to the corticomedullary junction that can be seen in some normal cats and as a nonspecific finding that can be a symptom of several pathological conditions.^{4,21,22} In the current study, MRS was reported in three cats (3.81%, one cat bilaterally and two cats unilaterally affected). In a study conducted on 332 cats, the prevalence of bilateral MRS was 12.30%. Among 41 cats with MRS, 14 cats were PKD positive and one cat (0.30%) had renal pelvic stones.⁹

The prevalence of renal calculus in the present study (2.40%) was higher than renal calculus prevalence reported in the study by Bonazzi *et al.*⁹

Urine sediments were found in 32.80% of the cats in the present study. It was more prevalent among cats over two years of age compared to those < 1 year. In Bonazzi *et al.* study, urine sediments were detected in 98 cats (29.51%) and no significant association was observed between the presence of sediment in bladder and the age groups. PKD was not significantly associated with the presence of urine sediment.⁹ In the present study, similar to the results of Bonazzi *et al.*, urine sediments were more

detectable in ultrasonography examination with increasing the age; however, the association between urine sediments and the age was not statistically significant. Urinary bladder calculus was detected in three cats (3.60%) in the present study, which it was more than the frequency of urinary bladder calculus in cats (0.60%) reported by Bonazzi *et al.* The bladder wall was normal in all of the examined cats in our study, but Bonazzi *et al.* reported mild thickened urinary bladder wall in two cats (0.60%).

The high prevalence of PKD and the progressive nature of the renal cysts which lead to irreversible kidney failure have attracted the attention of veterinarians and cat breeders.^{4,8} In conclusion, PKD prevalence was relatively high in the cats examined, however, it was lower than PKD prevalence in cats reported in the similar studies from other countries. Because of asymptomatic nature of the disease for long period of time, rapid diagnosis of disease by ultrasonography as an accurate and accessible method is necessary. This will help to eliminate the disease, and to implement health management programs and improve the life quality of affected animals.

Acknowledgments

This research was supported by the research council of the Ferdowsi University of Mashhad (grant No. 29161).

Conflict of Interest

The authors do not have any potential conflicts of interest to declare.

References

1. Bonazzi M, Volta A, Gnudi G, et al. Comparison between ultrasound and genetic testing for the early diagnosis of polycystic kidney disease in Persian and exotic shorthair cats. *J Feline Med Surg* 2009; 11(6):430-434.
2. Lee YJ, Chen HY, Ou CM, Diagnosis of feline polycystic kidney disease by a combination of ultrasonographic examination and PKD1 gene analysis. *Vet Rec* 2010; 167(16):614-618.
3. Volta A, Manfredi S, Gnudi G, et al. Polycystic kidney disease in a Chartreux cat. *J Feline Med Surg* 2010; 12(2):138-140.
4. Barrs VR, Gunew M, Foster SF, et al. Prevalence of autosomal dominant polycystic kidney disease in Persian cats and related-breeds in Sydney and Brisbane. *Aust Vet J* 2001; 79(4):257-259.
5. Debruyne K, Haers H, Combes A, et al. Ultrasonography of the feline kidney: Technique, anatomy and changes associated with disease. *J Feline Med Surg* 2012; 14(11):794-803.
6. Konde LJ, Park RD, Wrigley RH, et al. Comparison of radiography and ultrasonography in the evaluation of renal lesions in the dog. *J Am Vet Med Assoc* 1986; 188(12):1420-1425.
7. Norsworthy GD, Grace SF, Crystal MA, et al. The feline patient. 4th ed. Iowa, USA: Willey 2011, 418-419.
8. Barthez PY, Rivier P, Begon D. Prevalence of polycystic kidney disease in Persian and Persian related cats in France. *J Feline Med Surg* 2003; 5(6):345-347.
9. Bonazzi M, Volta A, Gnudi G, et al. Prevalence of the polycystic kidney disease and renal and urinary bladder ultrasonographic abnormalities in Persian and exotic shorthair cats in Italy. *J Feline Med Surg* 2007; 9(5):387-391.
10. Cannon MJ, MacKay AD, Barr FJ, et al. Prevalence of polycystic kidney disease in Persian cats in the United Kingdom. *Vet Rec* 2001; 149(14):409-411.
11. Domanjko-Petric A, Cernec D, Cotman M. Polycystic kidney disease: A review and occurrence in Slovenia with comparison between ultrasound and genetic testing. *J Feline Med Surg* 2008;10(2):115-119.
12. Gerwing M, Michele M, et al. PKD (polycystic kidney disease) - Polyzystisches Syndrom. *Praktische Tierarzt* 1999; 80:374-396.
13. DiBartola S. Autosomal dominant polycystic kidney disease. In *Proceedings: The 18th Annual veterinary medical forum of the American college of veterinary internal medicine*. Seattle, USA. 2000; 438-440.
14. Beck C, Lavelle RB. Feline polycystic kidney disease in Persian and other cats: A prospective study using ultrasonography. *Aust Vet J* 2001; 79(3):181-184.
15. Battershell D, Garcia JP. Polycystic kidney in a cat. *J Am Vet Med Assoc* 1969; 154(6):665-666.
16. Walter PA, Johnston GR, Feeney DA, et al. Applications of ultrasonography in the diagnosis of parenchymal kidney disease in cats: 24 cases (1981-1986). *J Am Vet Med Assoc* 1988; 192(1): 92-98.
17. Ravine D, Sheffield LJ, Danks DM, et al. Evaluation of ultrasonographic diagnostic criteria for autosomal dominant polycystic kidney disease 1. *The Lancet* 1994; 343(8901):824-827.
18. Biller DS, DiBartola SP, Eaton KA, et al. Inheritance of polycystic kidney disease in Persian cats. *J Heredity* 1996; 87(1):1-5.
19. Testault I. Polycystic disease of Persian cat [French]. *Le Point Ve'terinaire* 2003; 32:88-90.
20. Eaton KA, Biller DS, DiBartola SP, et al. Autosomal dominant polycystic kidney disease in Persian and Persian-cross cats. *Vet Pathol Online* 1997; 34(2):117-126.
21. Choukroun G, Itakura Y, Man NK, et al. The rate of progression of renal failure in ADPKD. *Contrib Nephrol* 1994; 115: 28-32.
22. Dennis R. *Handbook of small animal radiology and ultrasound: Techniques and differential diagnoses*. 2nd ed. Edinburgh, UK: Elsevier 2010; 297-330.