

## Comparative study of semen traits and histomorphometric features of testes of broiler breeder males with different phenotypic traits

Alireza Talebi<sup>1\*</sup>, Manoochehr Alimehr<sup>1</sup>, Mohammad Hossein Alavi<sup>1</sup>, Gholamreza Najafi<sup>2</sup>, Naeimeh Simaei<sup>2</sup>

<sup>1</sup> Department of Poultry Health and Diseases, Faculty of Veterinary Medicine, Urmia University, Urmia, Iran; <sup>2</sup> Department of Basic Sciences, Faculty of Veterinary Medicine, Urmia University, Urmia, Iran.

### Article Info

#### Article history:

Received: 29 April 2017

Accepted: 11 July 2017

Available online: 15 March 2018

#### Key words:

Breeder male  
Histomorphometry  
Phenotype  
Semen  
Testis

### Abstract

Fertility reduction due to sub-fertile males is a major concern in breeder flocks. Phenotypic traits of broiler breeder males and their relationships with fertility can be used as reliable indicators for identification and removal of sub-fertile males from the breeder flocks. This study was conducted to investigate semen traits (semen volume, sperm motility, sperm viability and sperm count) and testes histomorphometric features including tubule differentiation index (TDI), spermiation index (SPI), Sertoli cell index (SCI) and mitotic index (MI) of broiler breeder males with the same age but different phenotypic traits. According to phenotypic traits, 12 broiler breeder males (Ross-308 strain) were classified into three equal groups. Group 1: roosters with fertile phenotypic traits (fertile), group 2: roosters with the lowest fertile phenotypic traits (sub-fertile) and group 3: roosters with moderate fertile phenotypic traits (moderate). The results confirmed potential relationship between phenotypic traits and fertility in broiler breeder males. Semen traits and histomorphometric features of broiler breeder males' testis of the group 3 were more similar to those of the fertile roosters. Therefore, it can be concluded that exclusion of these roosters from the breeder flock may have undesirable effects on flock fertility.

© 2018 Urmia University. All rights reserved.

### مطالعه مقایسه‌ای ویژگی‌های منی و خصوصیات هیستومورفومتریک بافت بیضه خروس‌های مولد گوشتی با ویژگی‌های فنوتیپی متفاوت

#### چکیده

کاهش باروری در گله‌های مادر به دلیل خروس‌های نابارور، یکی از مشکلات عمده بشمار می‌رود. ارتباط بین ویژگی‌های فنوتیپی خروس‌های مولد گوشتی و باروری می‌تواند بعنوان شاخص‌های قابل اعتماد برای شناسایی و حذف خروس‌های نابارور از گله‌های مادر باشد. مطالعه حاضر به منظور ارزیابی ویژگی‌های منی (حجم منی، تحرک اسپرم، زنده‌مانی اسپرم و غلظت اسپرم) و خصوصیات هیستومورفومتریک بافت بیضه (شاخص تمایز لوله‌ای، شاخص اسپرمانتوزن، شاخص سلولهای سرتولی و شاخص میتوزی) در خروس‌های مولد گوشتی که دارای سن یکسان ولی ویژگی‌های فنوتیپی متفاوتی بودند صورت گرفت. براساس ویژگی‌های فنوتیپی، تعداد ۱۲ قطعه خروس مولد نژاد راس ۳۰۸ در سه گروه مساوی تقسیم‌بندی شدند. گروه ۱: خروس‌های با ویژگی‌های فنوتیپی بارور، گروه ۲: خروس‌های فاقد ویژگی‌های فنوتیپی بارور و گروه ۳: خروس‌های با ویژگی‌های فنوتیپی متوسط باروری (بین گروه ۱ و ۲). نتایج این مطالعه ارتباط بین ویژگی‌های فنوتیپی با باروری را در خروس‌های مولد گوشتی تأیید کرد و نشان داد خروس‌هایی که از لحاظ ویژگی‌های فنوتیپی ما بین خروس‌های بارور و غیر بارور قرار دارند در ارتباط با ویژگی‌های منی و خصوصیات هیستومورفومتریک بافت بیضه، بیشتر شبیه خروس‌های بارور هستند و در نتیجه حذف این خروس‌ها از گله مادر می‌تواند اثرات نامطلوبی را در باروری ایجاد نماید.

**واژه‌های کلیدی:** بیضه، خروس مولد گوشتی، فنوتیپ، منی، هیستومورفومتري

#### \*Correspondence:

Alireza Talebi. DVM, MVM, PhD

Department of Poultry Health and Diseases, Faculty of Veterinary Medicine, Urmia University, Urmia, Iran.

E-mail: a.talebi@urmia.ac.ir



This work is licensed under a Creative Commons Attribution-NonCommercial 4.0 International License which allows users to read, copy, distribute and make derivative works for non-commercial purposes from the material, as long as the author of the original work is cited properly.

## Introduction

Reproduction is the most important requisite of livestock breeding and fertile eggs play a dominant role in assessment of their performance. It is well known that breeder males' phenotypes have a great impact on the percent of fertile eggs and the genetic of breeder males has also a major influence on their progeny performance.<sup>1</sup> In commercial flocks, fertility of broiler breeders typically peaks between 30 to 40 weeks of age<sup>2-4</sup> and routinely declines after 45-50 weeks of age.<sup>4</sup> It is now well documented that low fertility could be largely due to the males' features in broiler breeder flocks. As the breeder males age increases, there is a reduction in the number of spermatozoa, volume of semen<sup>2,3,5,6</sup> and libido as well as changes in the body conformation that inhibit mating and affecting sperm quality.<sup>6</sup> Observable secondary sex features are used not only as a criterion for reproductive maturity and health status in breeder flocks,<sup>7</sup> but also can be used as the indicators for high semen physical traits.<sup>8</sup> Moreover, there are positive genetic correlations between phenotypic characteristics (mostly comb and wattle measurements) with semen traits which can be used as reliable indices to facilitate the identification and removal of sub-fertile males from the breeder flocks.<sup>9</sup>

The degree of development of the secondary sexual features could also affect the reproductive vigor of an individual.<sup>10-12</sup> The size and color of comb are significant predictors of sperm viability<sup>13</sup> as males with larger combs were likely to have higher fertility.<sup>9</sup> In naturally mated broiler breeder flocks, the reduction of fertility is mostly due to sub-fertile males in which their behavior, physiological (i.e. development of testes and hormonal secretion) and physical (i.e. size of comb and wattles) characteristics affect their fertility.<sup>14</sup> In general, hens may mate with several roosters and choose males based on multiple secondary sexual characteristics.<sup>9,13,15,16</sup> As the assessment of semen quality characteristics of roosters give an excellent indicator of their reproductive potentials<sup>17</sup> therefore, this study was conducted to investigate the semen traits (semen volume, sperm motility, sperm viability and sperm count) and testis histomorphometric features including tubule differentiation index (TDI), spermiation index (SPI), Sertoli cell index (SCI) and mitotic index (MI) of broiler breeder males with almost the same weights and the same age, but with different phenotypic traits in order to predict the fertility in broiler breeder flocks.

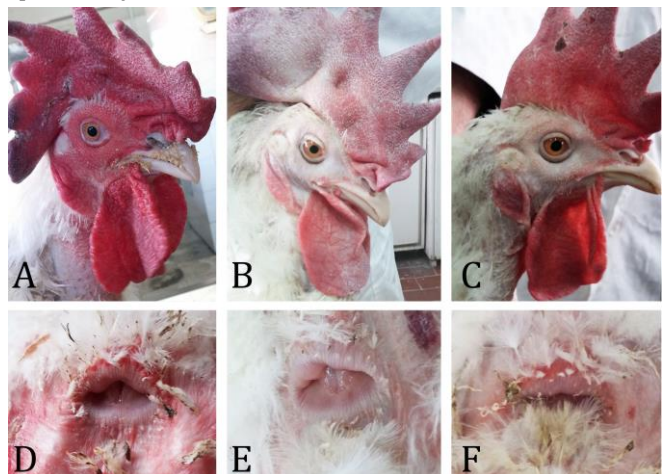## Materials and Methods

**Chickens.** Twelve broiler breeder males (Ross-308 strain) at 42 weeks of age but with different phenotypic characteristics were selected from a broiler breeder flock and divided into three equal groups according to their

phenotypic features including alertness and activity, body condition (shape and softness or hardness of breast muscle tone), head (uniform, intense red color around the comb, wattle and eye area), feathering (partial feather loss, especially around the shoulders and thighs) and vent (some feather wear, be large and moist, with red coloration) as shown in Figure 1.<sup>18</sup> Accordingly, roosters with the best phenotypic features were placed in group 1 (fertile group), while roosters with the lowest phenotypic features were placed in group 2 (sub-fertile group), and roosters with moderate phenotypic features were placed in group 3 (moderate group). All roosters were housed in individual pens and were fed with a recommended breeder diet (2700 kcal kg<sup>-1</sup> diet, 11.50% crude protein, 0.70% calcium and 0.35% phosphorous) according to Ross 308 parent stock nutritional specification manual 2016.<sup>19</sup>

**Semen collection.** In order to collect semen, the roosters were trained for 10 days before semen collection began. Semen collection was performed by abdominal massage as previously described.<sup>20</sup> Briefly, semen was obtained by gently massaging (stroking) the back of roosters with the palm of the hand while the abdomen was massaged towards the tail with the other hand. Two people were involved in performing the semen collection, one holding the rooster by the thigh and the other massaging for collecting the semen. After excitation of the roosters with abdominal massage, the male organ becomes swell and protrude while white semen can be seen in the central furrow of the organ. The semen was milked down by firm finger pressure either side of the vent into the collection tube. Immediately after collection, each ejaculate was evaluated for volume, motility, concentration and live-dead ratio of sperm.

**Semen volume.** Semen volume (mL) from each rooster using graduated centrifuge tubes was measured as previously described.<sup>21</sup>



**Fig. 1.** Head and vent features in different groups of the examined roosters. A and D: head and vent of group 1 (fertile roosters), B and E: head and vent of group 2 (Sub-fertile roosters). C and F: head and vent of group 3 (roosters between groups 1 and 2).

**Sperm motility.** Immediately after collection, semen was diluted (1:200) in modified ringer solution (NaCl: 68 g, KCl: 17.33 g, CaCl: 6.42 g, MgSO<sub>4</sub>: 2.50 g, NaHCO<sub>3</sub>: 24.50 g and distilled water 10000 mL) as previously described.<sup>22</sup> For evaluation of motility, one drop of the diluted semen was placed on a slide and covered with a cover slide, then sperm motility was estimated by microscopic observation (400× magnification). Motility was expressed as the percentage of motile spermatozoa with moderate to rapid progressive movement. A minimum of five microscopic fields were assessed to evaluate sperm motility on at least 200 sperm for each sample and percentage of motile sperms were calculated as previously described.<sup>21-25</sup>

**Sperm viability.** A 20 µL of sperm suspension (1:10) was mixed with an equal volume of 0.05% eosin-Y on a slide. After 20-30 sec, 20 µL nigrosin was added. Slides were examined using light microscope with 400× magnification following 2 min incubation at room temperature. Dead sperms appeared to be pink and live sperms were not stained. In each sample, 200 sperms were counted and their viability (%) were recorded.<sup>26</sup>

**Sperm count.** Sperm concentration was determined using the standard hemocytometric method as previously described.<sup>24,27,28</sup> Briefly, approximately 10 µL of sperm suspension (1:200) was transferred to each of the counting chambers of the Neubauer hemocytometer (HBG, Berlin, Germany), and was allowed to stand for five min in a humid condition in order to prevent drying. The cells were counted using a light microscope (400× magnification). The counted sperms were expressed as number of sperm per mL.

**Histological analysis.** At the end of the study, the males were euthanized (cervical dislocation) according to American Veterinary Medical Association guideline<sup>29,30</sup> and specimens from testis were collected for histological evaluation as previously described.<sup>31</sup> Briefly, after tissue fixation in 10% buffered formalin, specimens were processed through paraffin embedding and cut into 6 µm sections, stained with periodic acid-Schiff (PAS) technique. All specimens were studied under 400× and 1000× magnifications. Tubule differentiation index (TDI: the percentage of seminiferous tubules containing at least three differentiated germ cells)<sup>32</sup> and spermiation index (SPI: the percentage of seminiferous tubules with normal spermiation) were calculated.<sup>33</sup> Two hundred cross-sections of seminiferous tubules were randomly analyzed (one hundred per testis) for calculation of TDI and SPI. For the estimation of Sertoli cell index (SCI: the ratio of the number of germ cells to the number of Sertoli cells identified by a characteristic nucleus in all seminiferous tubules) and mitotic index (MI: the number of round spermatids for each pachytene primary spermatocytes, was calculated for determination of cell loss percentage during cell division), sixty seminiferous tubules per group were randomly examined.<sup>34,35</sup>

**Statistical analysis.** The results are expressed as the mean ± standard error (Mean ± SE). Differences among the groups were assessed by one-way analysis of variance using SPSS software package for Windows (version 23.0; IBM Corp., Armonk, USA). Statistical significance among the groups was determined by Tukey multiple comparison post-hoc test and the *p*-values < 0.05 were considered to be statistically.

## Results

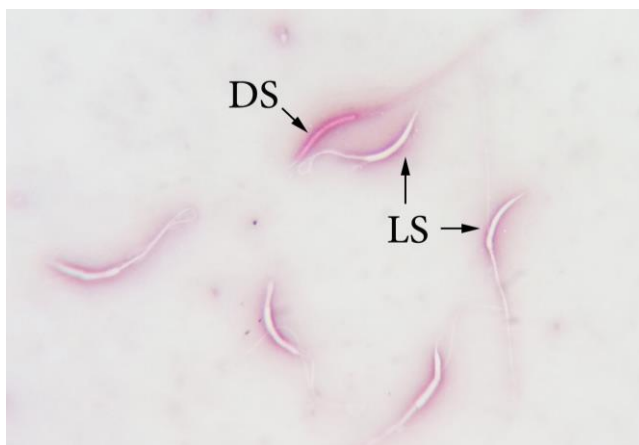Sperm traits (sperm viability, sperm motility and sperm count) of the examined roosters are shown in Table 1. There was no significant difference in sperm volume among the roosters. As shown in Table 1, the percent of sperm motility in group 1 was significantly (*p* < 0.05) higher than that of group 2. There was also a significant difference (*p* < 0.05) in sperm motility between group 2 and group 3. Evaluation of sperm viability among the groups showed that sperm viability rate differed among the groups but the difference was not significant (Fig. 2). Sperm count was significantly higher in group 1 roosters in comparison with those in group 2 (*p* < 0.05).

Average weights of right and left testes and histomorphometric features of the testes in different groups are presented in Tables 2 and 3. Weight of both testicles (right and left) of the roosters of group 1 was significantly higher than those of group 2 and 3 (*p* < 0.05), while there was no significant difference in testes' weight of roosters belonged to groups 2 and 3 (Table 2).

**Table 1.** Sperm properties of the examined broiler breeder males. Data are presented as mean ± SE.

Parameters	Group 1	Group 2	Group 3
Motility (%)	78.00 ± 8.87 <sup>a</sup>	13.70 ± 8.00 <sup>b</sup>	57.75 ± 10.00 <sup>a</sup>
Viability (%)	96.97 ± 1.04 <sup>a</sup>	44.37 ± 5.62 <sup>a</sup>	90.97 ± 2.43 <sup>a</sup>
Count (10 <sup>9</sup> mL <sup>-1</sup> )	2.62 ± 0.23 <sup>a</sup>	0.59 ± 0.34 <sup>b</sup>	1.68 ± 0.37 <sup>ab</sup>

<sup>ab</sup> Different superscripts indicate significant difference in each row (*p* < 0.05).



**Fig. 2.** Live and dead sperm cells. Dead sperm appeared to be pink (DS) and live sperms were not stained (LS) (eosin-nigrosin 1000×).



**Table 2.** Histomorphometric features of right testes in the examined broilers. Data are presented as mean  $\pm$  SE.

Parameters	Group 1	Group 2	Group 3
Testis weight (g)	13.12 $\pm$ 1.11 <sup>a</sup>	4.78 $\pm$ 1.26 <sup>b</sup>	6.88 $\pm$ 1.14 <sup>b</sup>
Spermiation index (%)	75.86 $\pm$ 6.11 <sup>a</sup>	11.55 $\pm$ 1.9 <sup>b</sup>	55.45 $\pm$ 9.56 <sup>a</sup>
Tubule differentiation index (%)	86.80 $\pm$ 1.90 <sup>a</sup>	23.38 $\pm$ 1.44 <sup>b</sup>	77.12 $\pm$ 5.18 <sup>a</sup>
Sertoli cell index	27.90 $\pm$ 5.27 <sup>a</sup>	4.90 $\pm$ 0.49 <sup>b</sup>	18.74 $\pm$ 0.63 <sup>ab</sup>
Mitotic index	4.33 $\pm$ 0.61 <sup>a</sup>	0.72 $\pm$ 0.14 <sup>b</sup>	2.64 $\pm$ 0.21 <sup>a</sup>

<sup>ab</sup> Different superscripts indicate significant difference in each row ( $p < 0.05$ ).

**Table 3.** Histomorphometric features of left testes in the examined broilers. Data are presented as mean  $\pm$  SE.

Parameters	Group 1	Group 2	Group 3
Testis weight (g)	14.65 $\pm$ 1.55 <sup>a</sup>	4.35 $\pm$ 1.15 <sup>b</sup>	7.09 $\pm$ 1.33 <sup>b</sup>
Spermiation index (%)	83.47 $\pm$ 4.70 <sup>a</sup>	2.50 $\pm$ 0.25 <sup>b</sup>	54.87 $\pm$ 6.26 <sup>c</sup>
Tubule differentiation index (%)	88.65 $\pm$ 2.50 <sup>a</sup>	14.42 $\pm$ 0.85 <sup>b</sup>	84.87 $\pm$ 2.44 <sup>a</sup>
Sertoli cell index	31.34 $\pm$ 3.14 <sup>a</sup>	5.02 $\pm$ 0.52 <sup>b</sup>	17.98 $\pm$ 1.98 <sup>ab</sup>
Mitotic index	4.53 $\pm$ 0.34 <sup>a</sup>	0.55 $\pm$ 0.13 <sup>b</sup>	2.07 $\pm$ 0.54 <sup>b</sup>

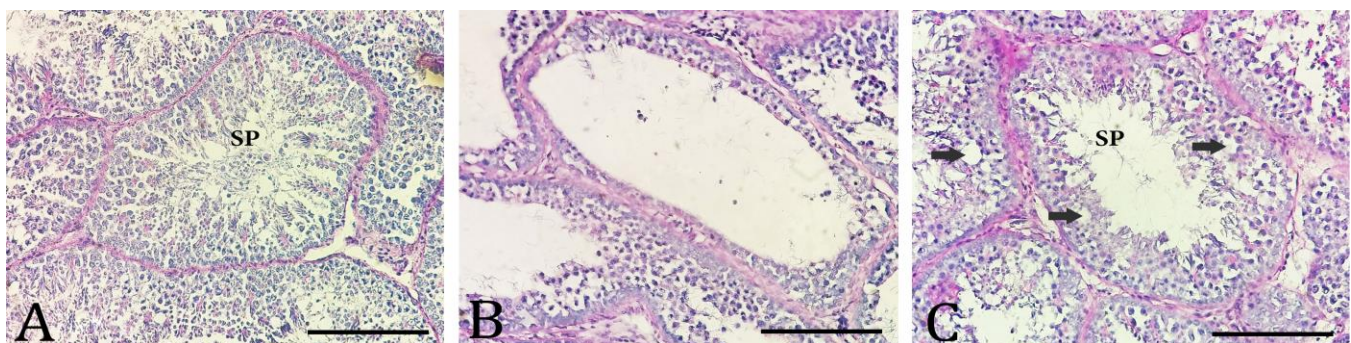
<sup>abc</sup> Different superscripts indicate significant difference in each row ( $p < 0.05$ ).

The SPI, TDI, SCI and MI of both testes in group 1 was significantly higher than those of group 2 ( $p < 0.05$ ; Tables 2 and 3). Regarding to TDI, SCI and MI, difference were not significant between groups 1 and 3. The histological section of right and left testes in different groups are illustrated in Figure 3. The SPI of the left testes were significantly different between groups 1 and 3 ( $p < 0.05$ ), however, SPI of the right testes were not significantly different between groups 1 and 3 ( $p > 0.05$ ). The SPI and TDI calculated for groups 2 and 3 were significantly different ( $p < 0.05$ ), however, SCI did not differ between these two groups. The results showed that MI of right testes were significantly different between groups 2 and 3 ( $p < 0.05$ ).

## Discussion

Fertility problems have a direct effects on performance and profitability of breeder flocks and infertility are mostly contributed to cockles' failure in birds. On the other hand, semen analysis is the most common way of accessing infertility in males. Previous studies indicated that reduced sperm concentration and semen volume in aging broiler breeder males contributed to reduction of fertility.<sup>2,33,34</sup>

As in broiler breeder flocks, fertile eggs are the main products which are used to produce one-day old chicks, therefore reduced fertility leads to infertile eggs and finally less chicks. Tabatabaei *et al.* reported that sperm mobility and viability are reduced in aging roosters.<sup>37</sup> Hence, identification and removal of infertile roosters are one of the main goals of aged breeder flocks' management. Unfortunately, identification of sub-fertile males which also have a negative impact on flock fertility is a vital issue, too. Relationships between phenotypic characteristics with fertilization (semen trait and histomorphometric features of testes) in aged roosters provided practically acceptable features to boost the recognition and elimination of sub-fertile males from the breeder flock. As shown in Table 1, roosters of the group 1 had higher sperm motility (almost six folds), sperm viability (almost two folds) and sperm count (almost 5 folds) in comparison with roosters of the group 2, while differences of these features between group 1 and group 3 were not significant ( $p > 0.05$ ). Regarding to testis histomorphometric features as shown in Tables 2 and 3, there is a significant ( $p < 0.05$ ) difference between group 1 and group 2 but differences between group 1 and group 3 was not significant ( $p > 0.05$ ). Also, Figure 3 confirms the



**Fig. 3.** Photomicrographs of testicular sections of the roosters. A) Testes of group 1 roosters exhibit relatively normal features of seminiferous tubules with active spermatogenesis and presence of sperms (SP) in lumen. B) Testes of group 2 roosters had germ cells depletion and impaired spermatogenesis. In some tubules, small numbers of sperms are present in lumen. C) Testes of group 3 roosters showed partial disorganizations and vacuoles (black arrows) in seminiferous tubules (PAS, Bar = 100  $\mu$ m).

results of histomorphometric evaluations and consistent with the data of Tables 2 and 3. Furthermore, the results of this study (Tables 1, 2, 3 and Figs. 2, 3) had a good relation with phenotypic traits as shown in Figure 1 and confirms that the roosters of group 1 had higher fertility rate when compared with roosters that do not have these features (group 2 and 3). Our results are in agreement with the results of previous studies reporting that the size and color of comb in roosters could be used as significant predictors of their sperm viability, quality<sup>13</sup> and sperms ability to reach and hydrolyze the perivitelline membrane of the ovum.<sup>9</sup> Reportedly, the reproductive potentials of an individual male could be affected by the degree of development of the secondary sexual characters,<sup>20,38,39</sup> and testosterone is essential not only for their development but also for normal mating behavior.<sup>40</sup> Moreover, it has been reported that sperm quality of roosters will be improve by the presence of hens<sup>41</sup> and breeding females crouch and mate more frequently with males possessing large comb and wattle.<sup>38</sup> Overall, our results support the hypotheses of correlation between phenotypic aspects with fertility and could be used for maintain of a good fertility management in broiler breeder flocks.

In conclusion the results of this study indicated that the roosters of the group 3 which were placed between fertile and sub-fertile groups, based on semen traits and histomorphometric features of testes, were more similar to fertile roosters and their exclusion may be resulted in lower fertility in the flock.

### Acknowledgements

The authors are thankful to all staff at the Department of Poultry Health and Diseases and Department of Basic Sciences, Faculty of Veterinary Medicine, for their kind cooperation in conducting this study.

### Conflict of interest

The authors declare no potential competing conflict of interest.

### References

1. Fiser PS, Chambers JR. Determination of male fertility in thirteen commercial lines of broiler parents. *Poult Sci* 1981; 60(10): 2316-2321.
2. Sexton KJ, Renden JA, Marple DN, et al. Effects of dietary energy on semen production, fertility, plasma testosterone and carcass composition of broiler-breeder males in cages. *Poult Sci* 1989; 68(12): 1688-1694.
3. Renden JA, Oates SS, West MS. Performance of two male broiler breeder strains raised and maintained on various constant photoschedules. *Poult Sci* 1991; 70(7): 1602-1609.
4. Hocking PM, Bernard R. Effects of dietary crude protein content and food intake on the production of semen in 2 lines of broiler breeder males. *Br Poult Sci* 1997; 38(2): 199-202.
5. Rosenstrauch A, Allan Degen A, Friedlander M. Spermatozoa retention by Sertoli cells during the decline in fertility in aging roosters. *Biol Reprod* 1994; 50(1): 129-136.
6. Brillard JP, McDaniel GR. Influence of spermatozoa numbers and insemination frequency on fertility in dwarf broiler breeder hens. *Poult Sci* 1986; 65(12): 2330-2334.
7. Lowry MM. Compensatory testicular adjustments following injection of small quantities of androgen into unilaterally castrated White Leghorn cockerels. *Poult Sci* 1958; 37(5): 1129-1136.
8. Gebriel GM, Kalamah MA, El Fiky AA, et al. Some factors affecting semen quality traits in Norfa cocks. *Egypt Poult Sci* 2009; 29(II): 677-693.
9. McGary S, Estevez I, Bakst MR, et al. Phenotypic traits as reliable indicators of fertility in male broiler breeders. *Poult Sci* 2002; 81(1): 102-111.
10. Dorfman RI. The relative reactivity of the comb of various breeds of chicks to androgens. Studies on the bioassay of hormones. *Endocrinology* 1948; 42(1): 7-14.
11. Zeller FJ. The effect of testosterone and dihydro-testosterone in the comb, testes, and pituitary gland of the male fowl. *J Reprod Fertil* 1971; 25(1): 125-127.
12. Hamilton WD, Zuk M. Heritable true fitness and bright birds: A role for parasites? *Science* 1982; 218(4570): 384-387.
13. Navara KJ, Anderson EM, Edwards ML. Comb size and color relate to sperm quality: A test of the phenotype-linked fertility hypothesis. *Behav Ecol* 2012; 23(5): 1036-1041.
14. Rahimpoor M, Khosravinia H, Khaldari M. Rooster phenotypic traits influence on the reproductive performance of the broiler parents. *Ind J Fund Appl Life Sci* 2016; 6(2): 7-12.
15. Zuk M, Johnson K, Thornhill R, et al. Mechanisms of female choice in red jungle fowl. *Evolution* 1990; 44(3): 477-485.
16. Zuk M, Thornhill R, Ligon JD, et al. The role of male ornaments and courtship behavior in female mate choice of red jungle fowl. *Am Nat* 1990; 136: 459-473.
17. Ajayi FO, Agaviezor BO, Ajuogu PK. Semen characteristics of three strains of local cocks in the humid tropical environment of Nigeria. *Int J Anim Vet Adv* 2011; 3(3): 125-127.
18. Ross parent stock management pocket guide. Available at: [http://en.aviagen.com/assets/Tech\\_Center/BB\\_Resources\\_Tools/Pocket\\_Guides/Ross-PS-Pocket-Guide2013EN.pdf](http://en.aviagen.com/assets/Tech_Center/BB_Resources_Tools/Pocket_Guides/Ross-PS-Pocket-Guide2013EN.pdf). Accessed Feb 18, 2016.

19. Ross 308 parent stock nutritional specification. Available at: [http://eu.aviagen.com/assets/Tech\\_Center/Ross\\_PS/Ross308-PS-NS-2016EN.pdf](http://eu.aviagen.com/assets/Tech_Center/Ross_PS/Ross308-PS-NS-2016EN.pdf). Accessed Feb 18, 2016.
20. Ibrahim AA, Alade NK, Aliyu J, et al. Relationship between phenotypic sexual characters and semen characteristics in four strains of cocks in northern Nigeria. *Iran J Appl Anim Sci* 2014; 4(3): 603-608.
21. Tabatabaei S, Batavani RA, Talebi AR. Comparison of semen quality in indigenous and Ross broiler breeder roosters. *J Anim Vet Adv* 2009; 8(1): 90-93.
22. Jalali AS, Hasanzadeh S. *Crataegus monogyna* fruit aqueous extract as a protective agent against doxorubicin-induced reproductive toxicity in male rats. *Avic J Phytomed* 2013; 3(2): 159-170.
23. Zemjanis R. Diagnostic and therapeutic technique in animal reproduction. 2<sup>nd</sup> ed. Baltimore, USA: Williams & Wilkins 1970; 139-155.
24. Zambrano E, Rodriguez-Gonzalez GL, Guzman C, et al. A maternal low protein diet during pregnancy and lactation in the rat impairs male reproductive development. *J Physiol* 2005; 563(1): 275-284.
25. Breininger E, Beorlegui NB, O'Flaherty CM, et al. Alpha-tocopherol improves biochemical and dynamic parameters in cryopreserved boar semen. *Theriogenology* 2004; 63(8): 2126-2135.
26. Armand Z, Najafi Gh, Farokhi F, et al. Attenuation of cyclosporine-induced sperm impairment and embryo toxicity by *Crataegus monogyna* fruit aqueous extract. *Cell J* 2013; 15(3): 198-205.
27. Jalali AS, Hasanzadeh S, Malekinejad H. *Achillea millefolium* inflorescence aqueous extract ameliorates cyclophosphamide-induced toxicity in rat testis: stereological evidences. *Chin J Nat Med* 2012; 10(4): 247-254.
28. Liu SJ, Zheng JX, Yang N. Semen quality factor as an indicator of fertilizing ability for Geese. *Poult Sci* 2008; 87(1): 155-159.
29. Collett SR. Principles of disease prevention, diagnosis, and control introduction. In: Swayne DE (Ed). *Diseases of poultry*. 13<sup>th</sup> ed. Ames, USA: Wiley-Blackwell 2013; 4-60.
30. Degernes L, Hess L, Marshall K, et al. American veterinary medical association guidelines for the euthanasia of animals. Schaumburg, USA: AVMA 2013; 60-63.
31. Najafi GH, Nejati V, Jalali AS, et al. Protective role of royal jelly in oxymetholone-induced oxidative injury in mouse testis. *Iran J Toxicol* 2014; 8(25): 1073-1080.
32. Porter KL, Shetty G, Meistrich ML. Testicular edema is associated with spermatogonial arrest in irradiated rats. *Endocrinology* 2006; 147(3): 1297-1305.
33. Rezvanfar M, Sadrkhanlou R, Ahmadi A, et al. Protection of cyclophosphamide induced toxicity in reproductive tract histology, sperm characteristics, and DNA damage by an herbal source; evidence for role of free-radical toxic stress. *Hum Exp Toxicol* 2008; 27(12): 901-910.
34. Kang J, Lee Y, No K, et al. Ginseng intestinal metabolite-I (GIM-I) reduces doxorubicin toxicity in the mouse testis. *Reprod Toxicol* 2002; 16(3): 291-298.
35. Sexton TJ. Relationship of the number of spermatozoa inseminated to fertility of turkey semen stored 6 h at 5 degrees C. *Br. Poult Sci* 1986; 27(2): 237-245.
36. Sexton TJ. Effect of semen treatments and age of tom on fertility of unstored semen and semen held 18 hours. *Poult Sci* 1987; 66(10): 1721-1726.
37. Tabatabaei S, Chaji M, Mohammadabadi T. Correlation between Age of Rooster and semen quality in Iranian indigenous Broiler chickens. *J Anim Vet Adv* 2010; 9(1): 195-198.
38. Galal M. Predicting semen attributes of naked and normally feathered male chickens from live performance traits. *Int J Poult Sci* 2007; 6(1): 36-42.
39. Abdellatif MA. Inheritance of comb and wattle lengths and its indicator to select cockerels in a population of Dandarawi chickens. *Assiut J Agric Sci* 1999; 30(4): 123-131.
40. Getachew T. A review article of artificial insemination in poultry. *World's Vet J* 2016; 6(1): 25-33.
41. Davila SG, Campo GL, Gil MG, et al. Effect of the presence of hens on roosters sperm variables. *Poult Sci* 2015; 94 (7): 1645-1649.