

Comparative effects of nano-selenium and sodium selenite supplementations on fertility in aged broiler breeder males

Mohammad Hossein Alavi¹, Manoochehr Allymehr^{2*}, Alireza Talebi², Gholamreza Najafi³

¹ DVSc Candidate, Department of Poultry Health and Diseases, Faculty of Veterinary Medicine, Urmia University, Urmia, Iran; ² Department of Poultry Health and Diseases, Faculty of Veterinary Medicine, Urmia University, Urmia, Iran; ³ Department of Basic Sciences, Faculty of Veterinary Medicine, Urmia University, Urmia, Iran.

Article Info

Article history:

Received: 26 May 2018
Accepted: 29 August 2018
Available online: 15 June 2020

Keywords:

Fertility
Histomorphometry
Male broiler breeder
Nano-selenium
Testis

Abstract

It is well documented that aging has negative effects on fertility. With increasing age, the activity of antioxidant enzymes are reduced and because of roosters sperm composition, a high proportion of polyunsaturated fatty acids (PUFAs), the probability of sperm damage increases. The objective of the present study was to compare the effects of nano-selenium and sodium selenite on fertility in aged male broiler breeder chickens. Thirty-five male broiler breeders (Cobb 500)[®] at 50 weeks of age were randomly divided into five equal groups: The control group was fed on a commercial diet, group T1 was fed on a commercial diet supplemented with sodium selenite (0.30 mg kg⁻¹ feed), group T2, T3 and T4 were fed on a commercial diet supplemented with nano-selenium (0.15, 0.30 and 0.60 mg kg⁻¹ feed, respectively). Sperm characteristics (sperm count, motility, viability, and maturity) as well as testicular histomorphometric features [tubule differentiation (TDI), spermiation (SPI), Sertoli cell (SCI) and meiotic (MI) indices] were assessed. The results showed that sperm characteristics were gradually decreased with age in the control group, however, it increased in group T3. Also, TDI, SPI, SCI, and MI in group T3 were higher than those of other groups. Our findings revealed that dietary supplementations with nano-selenium boosted fertility in aged male broiler breeders and the best results were obtained when the roosters received 0.30 mg kg⁻¹ nano-selenium. Supplementation of nano-selenium in aged broiler breeder males might be effective to maintain flock fertility and/or increase the flock fertility.

© 2020 Urmia University. All rights reserved.

Introduction

Chicken production is limited by fertility constraints. Even when kept under controlled conditions, the fertility rate of roosters peaks 96.00% at 37 weeks of age. This period of fertility is followed by a drastic and rapid decrease in reproductive success with fertility levels reaching 5.00% after 110 weeks.¹⁻³ Since sperm cells contain a high content of polyunsaturated fatty acids (PUFAs), oxidative stress is believed to be a major cause of sperm dysfunctions. The ratio of unsaturated to saturated fatty acids makes the membranes quite vulnerable to the attack of the reactive oxygen species (ROS) leading to membrane integrity loss in the acrosomal region, impaired cell function and decreased sperm motility.⁴ On the other hand, it has been shown that aging has negative effects on

semen quality. With the age progression, antioxidant enzyme activity, particularly that of phospholipid hydroperoxide glutathione peroxidase (GPx4 or PHGPx), is reduced significantly in epididymal sperm. Consequently, elevated ROS production results in apoptosis induction and semen quality reduction.⁵

Natural antioxidants play vital roles in protecting cells from ROS through free radicals scavenging and lipid peroxidation inhibition.⁶ The antioxidant system includes numerous antioxidant enzymes, such as glutathione peroxidase (GSH-Px), superoxide dismutase (SOD), and catalase (CAT).⁷ Selenium is an essential nutrient for the regulation of animals growth and reproduction.^{8,9} Many studies have suggested that selenium has a pronounced effect on male reproductive performance.¹⁰ It can maintain normal testicular function and cell structure⁵ as well as

*Correspondence:

Manoochehr Allymehr. DVM, DVSc
Department of Poultry Health and Diseases, Faculty of Veterinary Medicine, Urmia University, Urmia, Iran
E-mail: m.allymehr@urmia.ac.ir



This work is licensed under a Creative Commons Attribution-NonCommercial 4.0 International License which allows users to read, copy, distribute and make derivative works for non-commercial purposes from the material, as long as the author of the original work is cited properly.

spermatozoal motility and functioning.^{11,12} Some studies have indicated that selenium can increase the chance of successful conception⁵ and the number of Sertoli cells.⁴ Thus, selenium may be involved in the regulation of testicular functions. Selenium improves male reproductive performance not only by potentiating semen quality but also via free radicals suppression. The principal seleno-protein in testis is GPx4 expressing primarily in sperm.⁵ Selenium is an integral component of the active site of GSH-Px,¹³ an enzyme involved in the regulation of hydrogen peroxide and lipid peroxide levels.¹⁴ The Food and Drug Administration has approved the use of selenium as sodium selenate or sodium selenite in poultry feed at the levels of 0.30 mg kg⁻¹.¹⁵ Use of inorganic selenium has several limitations including potential toxicity, poor absorption, interaction with other minerals and dietary components, storage loss and inability to supply and maintaining selenium reserve in the body. Hence, the use of sodium selenite is recently being debated.^{16,17}

Currently, nano-selenium is used in nutritional supplements and has been advocated for applications in medical therapy.^{4,18} Since nanometer particulates exhibit novel characteristics such as great specific surface area, high surface activity, a lot of surface-active centers, high catalytic efficiency, strong adsorbing ability, and low toxicity, nano-selenium has attracted widespread attention.^{19,20} Further, since surface-area-to-volume ratio increases with particle size reduction, selenium nanoparticles have high biological activities²¹ including anti-hydroxyl radical property¹⁸ and protective actions against DNA oxidation.²²

This study was conducted to compare the effects of nano-selenium and sodium selenite supplementations on semen characteristics (semen volume and sperm motility, viability, maturity, and count) and testicular histomorphometric features including tubule differentiation (TDI), spermiation (SPI), Sertoli cell (SCI) and meiotic (MI) indices in aged broiler breeder males approximately the same weights and ages.

Materials and Methods

Chickens diets, and experimental design. Thirty-five male broiler breeders (Cobb 500)[®] at 50 weeks of age with almost same weights were selected from a broiler breeder flock and randomly divided into five equal groups including Control: fed a commercial diet (2700 kcal kg⁻¹ feed, 12.70% crude protein, 0.88% calcium and 0.44% phosphorous);²³ treatment 1 (T1): fed on a commercial diet supplemented with 0.30 mg kg⁻¹ sodium selenite (Merck KGaA, Darmstadt, Germany), treatment 2 (T2): fed on a commercial diet supplemented with 0.15 mg kg⁻¹ nano-selenium (99.00% Selenium nanoparticles, 10.00 - 45.00 nm; American Elements, Los Angeles, USA), treatment 3 (T3): fed on a commercial diet supplemented with 0.30 mg kg⁻¹

nano-selenium and treatment 4 (T4): fed on a commercial diet supplemented with 0.60 mg kg⁻¹ nano-selenium. The experiment has lasted for five weeks: The first week was allocated for adaptation and treatment was started in a second week. During the experiment, all roosters were housed in individual pens, under the controlled conditions of temperature (22.00 ± 2.00°C), humidity (55.00 ± 5.00%) and 14/10 hr light-dark cycle. The Ethics Committee of the Faculty of Veterinary Medicine of Urmia University (IR-UU-AEC-1688/DA3/ 2020) approved the research and animal care procedures. All chemicals except for nano-selenium were purchased from Merck Chemical Co. (Darmstadt, Germany).

Semen collection. To collect semen, the roosters were trained for seven days. Semen collection was performed through abdominal massage as previously described.²⁴

Briefly, an assistant is needed for holding and abdominal massaging of roosters during semen collection. When the rooster is excited, phallic body of the male is swollen and protruded then semen could be collected by finger pressure on the either side of the vent. Immediately after collection, each ejaculate was evaluated for motility, concentration, viability, and maturity of sperms. Semen analyses were carried out at the end of the first, third, and fifth weeks of the experiment.

Sperm motility. Sperm motility were assessed as previously described.^{25,26} Briefly, a modified ringer solution (sodium chloride: 68.00 g, potassium chloride: 17.33 g, calcium chloride: 6.42 g, magnesium sulfate: 2.50 g, sodium bicarbonate: 24.50 g and distilled water 10,000 mL) was used for semen dilution (1:200). Sperm motility was evaluated by using light microscope (Model CHT; Olympus Optical Co. Ltd., Tokyo, Japan) at 400× magnification. At least five microscopic fields were checked out for estimating of sperm motility and a minimum of 200 sperms were analyzed for each sample. Percentage of spermatozoa with moderate to rapid progressive movement were expressed as sperm motility.

Sperm count. A standard hemocytometer method was used for the sperm count as previously described.²⁴ Briefly, 10.00 µL of sperm suspension (1:200) was transferred to each of the counting chambers of the Neubauer hemocytometer (HBG, Berlin, Germany) and after a five min standing in a humid condition, the cells were counted by using a light microscope at 400× magnification and expressed as the number of sperm per mL.

Sperm maturity. This staining was performed to evaluate sperm chromatin condensation. Sperm smear was prepared and fixed by a 3.00% glutaraldehyde fixative solution for 30 min following drying in laboratory temperature. Then, smears were stained by 5.00% aniline blue (using 4.00% acetic acid) for 7 min and the percentages of mature sperms (having colorless heads) and immature sperms (having blue-colored heads) were recorded using a light microscope. Five slides were

prepared for each sample and 100 sperms per slide were counted under the light microscope.²⁷

Sperm viability. A 20.00 μL of eosin-Y (0.05%) was mixed with an equal volume of sperm suspension on a slide and after 30 sec, 20.00 μL nigrosin was added. After two min incubation at room temperature, the slides were examined by a light microscope at 400 \times . At least 200 sperms (pink color sperms were considered as dead sperm) were counted and their viability was expressed as percentage.²⁴

Histological analysis. At the end of the study, the roosters were anesthetized with intramuscular injection of 50 mg kg^{-1} ketamine (Alfasan, Woerden, The Netherlands)²⁸ and euthanized using of CO_2 gas, then testicular tissue samples were collected for histological evaluation as previously described.²⁹ Briefly, after tissue fixation in 10.00% buffered formalin, specimens were processed through paraffin embedding, cut into 6.00 μm sections, and stained with periodic acid-Schiff (PAS) technique. All of the slides were studied by multiple magnifications (400 \times and 1000 \times). The TDI and SPI were determined as a percentage of seminiferous tubules containing at least three differentiated germ cells and a percentage of seminiferous tubules with normal spermiation,²⁴ respectively. Two hundred cross-sections of seminiferous tubules were randomly analyzed (one hundred per testis) for calculation of TDI and SPI. For the estimation of SCI and MI, the ratio of the number of germ cells to the number of Sertoli cells was identified by a characteristic nucleus in all seminiferous tubules and the number of round spermatids for each pachytene primary spermatocytes were recorded, respectively, in sixty seminiferous tubules per group.²⁴

Statistical analysis. The results were expressed as the mean \pm standard error (Mean \pm SE). Differences among the groups were assessed by one-way analysis of variance using SPSS Software Package for Windows (version 25.0, SPSS Inc., Armonk, USA). Statistical significance among the groups was determined by Tukey multiple comparison post-hoc test and the $p \leq 0.05$ were considered to be statistically significant.

Results

Sperm parameters. The sperm characteristics (sperm count, motility, viability, and maturity) in different groups at the end of the first, third, and fifth weeks of the experiment are shown in Table 1.

Sperm motility. As shown in Table 1, the sperm motility in the control group was gradually decreased with age in an insignificant manner ($p > 0.05$). In the T1 group (sodium selenite 0.30 mg kg^{-1}) the sperm motility was decreased with age. This decline was lower than that of the control group; however, it was not statistically significant ($p > 0.05$). In T2, T3, and T4 groups (nano-selenium 0.15, 0.30, and 0.60 mg kg^{-1} , respectively), the sperm motility was gradually increased at the end of the fifth week of the experiment. The lowest increase was observed in the T2 group and the highest one was seen in the T3 group.

Sperm viability. Evaluation of sperm viability (Fig. 1A) showed that the sperm viability rate was decreased with age in all groups except for the T3 group ($p > 0.05$).

Sperm count. As shown in Table1, there was no significant difference in sperm count among the groups ($p > 0.05$). Although, sperm count was increased with age in group T3.

Table 1. Semen characteristics (mean \pm SE) of the examined male broiler breeders, fed on different levels of selenium and nano-selenium.

Groups	Sperm count (10^9 mL^{-1})	Sperm viability (%)	Sperm motility (%)	Sperm maturity (%)
End of the first week				
Control	5.89 \pm 0.87	85.36 \pm 5.46	76.74 \pm 4.29	88.05 \pm 4.28
T1 (0.30 mg sodium selenite)	5.64 \pm 1.28	86.42 \pm 4.24	77.25 \pm 3.21	89.83 \pm 3.91
T2 (0.15 mg nano-selenium)	5.95 \pm 1.09	82.37 \pm 3.65	71.37 \pm 4.08	85.57 \pm 4.43
T3 (0.30 mg nano-selenium)	5.05 \pm 0.63	82.54 \pm 5.21	72.29 \pm 5.01	87.48 \pm 3.84
T4 (0.60 mg nano-selenium)	5.15 \pm 0.92	89.40 \pm 4.42	76.02 \pm 3.17	93.46 \pm 5.07
<i>p</i> -value	0.940	0.804	0.767	0.755
End of the third week				
Control	5.61 \pm 0.94	81.62 \pm 3.27	69.03 \pm 4.23	84.30 \pm 4.17
T1 (0.30 mg sodium selenite)	5.73 \pm 1.01	81.01 \pm 5.61	75.40 \pm 3.92	86.73 \pm 3.45
T2 (0.15 mg nano-selenium)	5.63 \pm 0.51	82.84 \pm 3.11	72.37 \pm 5.19	87.19 \pm 4.57
T3 (0.30 mg nano-selenium)	5.03 \pm 0.97	85.75 \pm 4.58	74.38 \pm 3.34	90.07 \pm 3.06
T4 (0.60 mg nano-selenium)	5.52 \pm 1.11	88.15 \pm 3.86	77.21 \pm 4.63	91.08 \pm 5.18
<i>p</i> -value	0.983	0.730	0.590	0.784
End of the fifth week				
Control	5.55 \pm 1.14	77.03 \pm 3.39	58.93 \pm 4.49	79.62 \pm 3.97
T1 (0.30 mg sodium selenite)	6.00 \pm 0.78	80.21 \pm 4.06	72.85 \pm 3.51	83.21 \pm 4.05
T2 (0.15 mg nano-selenium)	5.97 \pm 0.65	81.17 \pm 3.41	74.37 \pm 6.07	83.43 \pm 3.28
T3 (0.30 mg nano-selenium)	5.72 \pm 0.83	86.83 \pm 4.52	80.16 \pm 4.87	90.89 \pm 5.79
T4 (0.60 mg nano-selenium)	5.32 \pm 1.30	87.50 \pm 5.09	79.26 \pm 3.98	89.53 \pm 4.41
<i>p</i> -value	0.983	0.422	0.110	0.426

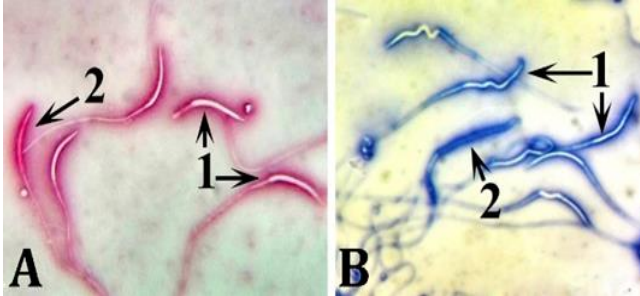


Fig. 1. Rooster (Cobb 500)[®] spermatozoa stained with **A)** Eosin-nigrosin, live sperms are not stained (1) and dead sperm is stained pink (2), and **B)** Aniline-blue, mature sperms (1) are characterized by colorless head and immature sperm (2) has a dark-blue-colored head (1000x).

Sperm maturity. The data revealed that sperm maturity (Fig. 1B) relatively was decreased with age ($p > 0.05$), however, it was increased in the T3 group.

Histological analysis. The SPIs in the control group were significantly lower than those of other groups ($p < 0.05$), (Table 2); while there were no significant differences regarding SPI among T1, T2, T3, and T4 groups. As shown in Table 2, the TDIs in T1, T2, T3, and T4 groups were significantly higher than those of the control group ($p < 0.05$), however, the differences among the mentioned groups were not significant ($p > 0.05$). Regarding SCI and MI, no significant differences were observed among the groups ($p > 0.05$). Testis of the control group exhibit degenerated seminiferous tubules with relatively inactive spermatogenesis and the presence of small amounts of sperm in the lumen (Fig. 2). Also, TDI was negative in some parts of the control group seminiferous tubules. Testes of other groups show partial disorganizations along with vacuolation in seminiferous tubules.

Table 2. Histomorphometric features of the examined male broiler breeders, fed on a different level of selenium and nano-selenium. Data are presented as mean \pm SE.

Groups	Spermiation index (%)	Tubule differentiation index (%)	Sertoli cell index	Meiotic index
Control	42.69 \pm 3.13 ^a	62.68 \pm 3.51 ^a	18.34 \pm 1.98	2.09 \pm 0.54
T1 (0.30 mg sodium selenite)	64.64 \pm 4.49 ^b	84.93 \pm 4.29 ^b	23.28 \pm 2.14	2.44 \pm 0.31
T2 (0.15 mg nano-selenium)	65.71 \pm 4.17 ^b	89.63 \pm 5.01 ^b	24.54 \pm 3.02	2.53 \pm 0.39
T3 (0.30 mg nano-selenium)	76.02 \pm 4.05 ^b	92.42 \pm 3.76 ^b	27.36 \pm 2.91	2.94 \pm 0.72
T4 (0.60 mg nano-selenium)	75.29 \pm 3.94 ^b	90.77 \pm 6.18 ^b	26.12 \pm 3.58	2.87 \pm 0.65
p-value	0.010	0.004	0.315	0.801

^{ab} Different superscripts denote significant difference in each column ($p < 0.05$).

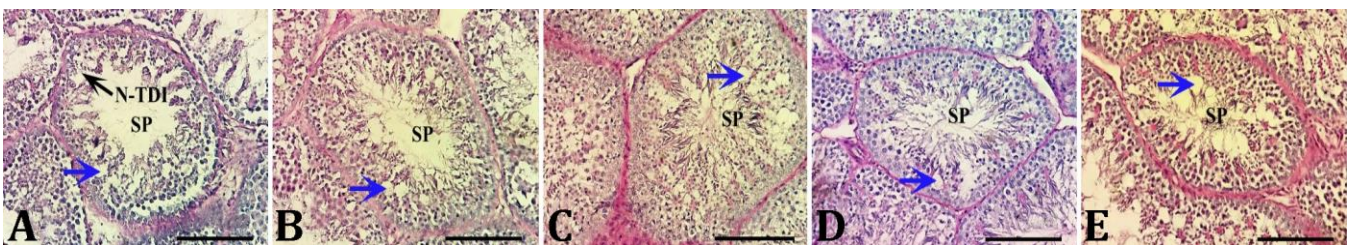

Fig. 2. Photomicrographs of testicular sections of the roosters (Cobb 500)[®] belonged to **A)** Control, **B)** T1, **C)** T2, **D)** T3, and **E)** T4 groups. Testis of the control group exhibits degenerated seminiferous tubules with relatively inactive spermatogenesis and the presence of small amounts of sperm (SP) in the lumen. Also, TDI is negative in some parts of the control group seminiferous tubules (N-TDI). Testes of other groups show partial disorganizations along with vacuolation (blue arrows) in seminiferous tubules (PAS, Bar = 100 μ m).

Discussion

The purpose of this study was to compare the effects of sodium selenite (0.30 mg kg⁻¹) and nano-selenium (0.15, 0.30 and 0.60 mg kg⁻¹) supplementations on sperm characteristics (sperm count, motility, viability, and maturity) and histomorphometric features (SPI, TDI, SCI and MI) in aged male broiler breeders.

The exact mechanism for semen quality reduction with age is not clear. The peroxidation in PUFAs of the n-3, n-9 and n-6 series due to aging may be responsible for viability, motility and fertilizing ability reduction of spermatozoa.³⁰ Also, it has been indicated that changes in the proportions of various lipid components (free fatty acids and cholesterol esters increase continuously with age) in spermatozoa can be associated with reduced fertility of male chickens.³¹

The importance of semen evaluation in poultry breeding for selecting breeding males and/or routine monitoring of their reproductive performance has been well recognized.³²

It has been demonstrated that reproductive performance (sperm concentration, motility, and viability reductions and spermatozoa morphological defect rates increase) is decreased with age in indigenous roosters.²⁶

It has been reported that spermatozoa concentration is reduced with age in turkey toms.^{30,33} It has been revealed that sperm concentration is lower in aged bulls.³⁴ It was also found that there are negative correlations between age and spermatozoa motility and viability in turkeys.³⁰

Furthermore, it has been reported that the quality of fresh and stored semen in turkey is affected by age.³⁵ In agreement with previous studies; the findings of this experiment in the control group indicated that semen

characteristics (sperm count, motility, viability, and maturity) were gradually decreased with age in male broiler breeders.

Accordingly, it has been shown that rooster sperms are particularly susceptible to oxidative damage due to the abundance of plasma membrane PUFAs.^{16,36} Moreover, selenium is the main component of GSH-Px and selenoproteins ensuring sperm viability as well as providing protection against ROS.⁵ Further, selenium has also an important role in sperm motility and male fertility.³⁷ It has been shown that dietary selenium supplementation improves antioxidant status through GSH-Px activation.^{38,39} It has been indicated that selenium supplementation is known to affect the antioxidant defenses system of chicken semen.¹⁶ It has also been reported that selenium is essential for the proper functioning of the male reproductive system. Previous studies have revealed a strong correlation between selenium status and sperm quality.^{4,40,41} Selenium localizes on the mid-piece of sperm⁵ and its deficiency, depending on the severity, results in decreased sperm motility, abnormal sperm morphology and infertility. The testes accumulate and maintain the highest selenium content per dry mass of tissue in comparison with other organs when males are fed on adequate (0.30 mg Se per kg feed) concentrations of Se through diet.⁴² Previous studies have shown that even when the selenium level of other tissues is low, the testes maintain selenium content at original concentrations.¹⁰ Furthermore, it has been shown that when cockerels are fed on a basal diet containing 0.28 ppm selenium without additional dietary supplementation of this trace element, the percentage of normal spermatozoa is only 57.90% and two major observed abnormalities are bent mid-piece (18.70%) and corkscrew head (15.40%) following supplementation with an additional 0.20 ppm selenium in the form of selenite. The percentage of normal spermatozoa was increased to 89.40% and, bent mid-piece and corkscrew head abnormalities were decreased to 6.20% and 1.80%, respectively.⁴³ The present study indicated that fertility was declined in roosters fed on a diet supplemented with selenium (sodium selenite) and decreased with age compared to the control group. Recently, nano-selenium has attracted more attention due to its high bioavailability, high catalytic efficiency, strong adsorbing ability, and low toxicity compared to selenite in mice,¹⁹ chickens,⁴⁴ rats,⁴⁵ sheep⁴⁶ and goats.⁴⁷

It has been shown that nano-selenium absorptions from the intestinal lumen are higher than those of sodium selenite.⁴⁸ Also, dietary supplementation of nano-selenium has resulted in a higher selenium concentration in broilers tissues compared to sodium selenite.⁴⁹ It has been suggested that nano-selenium supplementation (0.30 mg kg⁻¹ diet) may improve growth performance, antioxidative status and immunity in broilers reared under high ambient temperature conditions.⁵⁰

In agreement with the aforementioned studies, our results indicated that nano-selenium supplementations may boost fertility in aged male broiler breeders and the best results were obtained in roosters fed on a diet supplemented with 0.30 mg kg⁻¹ nano-selenium. Histological parameters including TDI and SPI can also give information on the degree of testicular damage as a consequence of germ cell loss.²⁵ This study indicated that the percentage of seminiferous tubules without sperm in the control group was higher than groups fed on diets supplemented with nano-selenium. Accordingly, the percentage of degenerated testicular germinal epithelium in the control group was higher than that of groups fed on diets supplemented with nano-selenium.

In conclusion, the results of the present study indicated that nano-selenium supplementation of the diets of aged male broiler breeders might be effective to maintain fertility in aged flocks and boost the flock reproductive performances.

Acknowledgments

The authors are thankful to all staff at the Department of Poultry Health and Diseases and Department of Basic Sciences, Faculty of Veterinary Medicine, Urmia University, Iran, for their kind cooperation for conducting this study. This research was financially supported by Vice-Chancellor for Research, Urmia University, Urmia, Iran.

Conflict of interest

The authors declare no potential competing conflict of interest.

References

1. Rosenstrauch A, Degen AA, Friedländer M. Spermatozoa retention by Sertoli cells during the decline in fertility in aging roosters. *Biol Reprod* 1994; 50(1): 129-136.
2. Muncher Y, Sod-Moriah UA, Weil S, et al. Intratesticular retention of sperm and premature decline in fertility in the domestic rooster, *Gallus domesticus*. *J Exp Zool* 1995; 273(1): 76-81.
3. Weil S, Rozenboim I, Degen AA, et al. Fertility decline in aging roosters is related to increased testicular and plasma levels of estradiol. *Gen Comp Endocrinol* 1999; 115(1): 23-28.
4. Shi LG, Yang RJ, Yue WB, et al. Effect of elemental nano-selenium on semen quality, glutathione peroxidase activity, and testis ultrastructure in male Boer goats. *Anim Reprod Sci* 2010; 118(2-4): 248-254.
5. Ahsan U, Kamran Z, Raza I, et al. Role of selenium in male reproduction-a review. *Anim Reprod Sci* 2014; 146(1-2): 55-62.

6. Grashorn MA. Functionality of poultry meat. *J Appl Poult Res* 2007; 16(1): 99-106.
7. Surai P. Selenium in poultry nutrition 2. Reproduction, egg and meat quality and practical applications. *World Poult Sci J* 2002; 58(4): 431-450.
8. Grazul-Bilska AT, Caton JS, Arndt W, et al. Cellular proliferation and vascularization in ovine fetal ovaries: effects of undernutrition and selenium in maternal diet. *Reproduction* 2009; 137(4): 699-707.
9. Schwarz K, Foltz CM. Selenium as an integral part of factor 3 against dietary necrotic liver degeneration. *Nutrition* 1999; 15(3): 254-256.
10. Behne D, Höfer T, von Berswordt-Wallrabe R, et al. Selenium in the testis of the rat: studies on its regulation and its importance for the organism. *J Nutr* 1982; 112(9): 1682-1687.
11. Kaur P, Bansal MP. Effect of selenium-induced oxidative stress on the cell kinetics in testis and reproductive ability of male mice. *Nutrition* 2005; 21(3): 351-357.
12. Messaoudi I, Banni M, Saïd L, et al. Involvement of selenoprotein P and GPx4 gene expression in cadmium-induced testicular pathophysiology in rat. *Chem Biol Interact* 2010; 188(1): 94-101.
13. Yoon I, Werner TM, Butler JM. Effect of source and concentration of selenium on growth performance and selenium retention in broiler chickens. *Poult Sci* 2007; 86(4): 727-730.
14. Arthur JR. The glutathione peroxidases. *Cell Mol Life Sci* 2000; 57(13-14): 1825-1835.
15. Food and Drug Administration. Food additives permitted in feed and drinking water of animals: Selenium. *Federal Register* 1987; 52: 10887.
16. Bréque C, Surai P, Brillard JP. Roles of antioxidants on prolonged storage of avian spermatozoa *in vivo* and *in vitro*. *Mol Reprod Dev* 2003; 66(3): 314-323.
17. Pehrson B. Selenium in nutrition with special reference to the biopotency of organic and inorganic selenium compounds. In proceedings: 9th Alltech annual symposium: Biotechnology in the Feed industry. Nottingham, UK 1993: 71-89.
18. Gao X, Zhang J, Zhang L. Hollow sphere selenium nanoparticles: Their *in vitro* anti hydroxyl radical effect. *Adv Mater* 2002; 14(4): 290-293.
19. Wang H, Zhang J, Yu H. Elemental selenium at nano size possesses lower toxicity without compromising the fundamental effect on selenoenzymes: comparison with selenomethionine in mice. *Free Radical Biol Med* 2007; 42(10): 1524-1533.
20. Song D, Cheng Y, Li X, et al. Biogenic nanoselenium particles effectively attenuate oxidative stress-induced intestinal epithelial barrier injury by activating the Nrf2 antioxidant pathway. *ACS Appl Mater Interfaces* 2017; 9(17): 14724-14740.
21. Zhang J, Wang H, Yan X, et al. Comparison of short-term toxicity between Nano-Se and selenite in mice. *Life Sci* 2005; 76(10): 1099-1109.
22. Huang B, Zhang J, Hou J, et al. Free radical scavenging efficiency of Nano-Se *in vitro*. *Free Radic Biol Med* 2003; 35(7): 805-813.
23. Cobb 500 breeder Management supplement. Available at: <https://cobbstorage.blob.core.windows.net/guides/f5ec4cd0-bc92-11e6-bd5d-55bb08833e29.pdf>. Accessed Feb 18, 2016.
24. Talebi A, Alimehr M, Alavi MH, et al. Comparative study of semen traits and histomorphometric features of testes of broiler breeder males with different phenotypic traits. *Vet Res Forum* 2018; 9(1): 1-6.
25. Shalizar Jalali A, Hasanzadeh S. *Crataegus monogyna* fruit aqueous extract as a protective agent against doxorubicin-induced reproductive toxicity in male rats. *Avicenna J Phytomed* 2013; 3(2): 159-170.
26. Tabatabaei S, Chaji M, Mohammadabadi T. Correlation between age of rooster and semen quality in Iranian indigenous broiler breeder chickens. *J Anim Vet Adv* 2010; 9(1): 195-198.
27. Ebadi Manas G, Hasanzadeh S, Najafi G, et al. The effects of pyridaben pesticide on the DNA integrity of sperms and early *in vitro* embryonic development in mice. *Iran J Reprod Med* 2013; 11(8): 605-610.
28. Samour J. *Avian medicine*. 3rd ed. Oxford, UK: Elsevier 2015; 186.
29. Najafi G, Nejati V, Shalizar Jalali A, et al. Protective role of royal jelly in oxymetholone-induced oxidative injury in mouse testis. *Iran J Toxicol* 2014; 8(25): 1073-1080.
30. Rostato MP, Cinone M, Manchisi A, et al. Changes on the quality characteristics of stored semen during reproductive period of Hybrid toms. In proceedings: 12th European poultry conference. Verona, Italy. 2006: 10-14.
31. Cerolini S, Kelso KA, Noble RC, et al. Relationship between spermatozoan lipid composition and fertility during aging of chickens. *Biol Reprod* 1997; 57(5): 976-980.
32. Cheng FP, Guo TJ, Wu JT, et al. Annual variation in semen characteristics of pigeons (*Columba livia*). *Poult Sci* 2002; 81(7): 1050-1056.
33. Kotłowska M, Glogowski J, Dietrich GJ, et al. Biochemical characteristics and sperm production of turkey semen in relation to strain and age of the male. *Poult Sci* 2005; 84(11): 1763-1768.
34. Fuerst-Waltl B, Schwarzenbacher H, Perner C, et al. Effects of age and environmental factors on semen production and semen quality of Austrian Simmental bulls. *Anim Reprod Sci* 2006; 95(1-2): 27-37.
35. Douard V, Hermier D, Magistrini M, et al. Reproductive period affects lipid composition and quality of fresh and stored spermatozoa in turkeys. *Theriogenology* 2003; 59(3-4): 753-764.

36. Surai PF, Fujihara N, Speake BK, et al. Polyunsaturated fatty acids, lipid peroxidation and antioxidant protection in avian semen. *Asian Australasian J Anim Sci* 2001; 14(7): 1024-1050.
37. Mohammadi S, Movahedin M, Mowla SJ. Up-regulation of CatSper genes family by selenium. *Reprod Biol Endocrinol* 2009; 7. doi. 10.1186/1477-7827-7-126.
38. Yoon I, Werner TM, Butler JM. Effect of source and concentration of selenium on growth performance and selenium retention in broiler chickens. *Poult Sci* 2007; 86(4): 727-730.
39. Ebeid TA, Zeweil HS, Basyony MM, et al. Fortification of rabbit diets with vitamin E or selenium affects growth performance, lipid peroxidation, oxidative status and immune response in growing rabbits. *Livest Sci* 2013; 155(2-3): 323-331.
40. Sánchez-Gutiérrez M, García-Montalvo EA, Izquierdo-Vega JA, et al. Effect of dietary selenium deficiency on the in vitro fertilizing ability of mice spermatozoa. *Cell Biol Toxicol* 2008; 24(4): 321-329.
41. Boitani C, Puglisi R. Selenium, a key element in spermatogenesis and male fertility. *Adv Exp Med Biol* 2008; 636: 65-73.
42. Behne D, Wolters W. Distribution of selenium and glutathione peroxidase in the rat. *J Nutr* 1983; 113(2): 456-461.
43. Edens FW. Practical applications for selenomethionine: Broiler breeder reproduction. In proceedings: 18th Alltech annual symposium. Nottingham, UK. 2002; 29-42.
44. Wang RR, Pan XJ, Peng ZQ. Effects of heat exposure on muscle oxidation and protein functionalities of pectoralis majors in broilers. *Poult Sci* 2009; 88(5): 1078-1084.
45. Jia X, Li N, Chen J. A subchronic toxicity study of elemental Nano-Se in Sprague-Dawley rats. *Life Sci* 2005; 76(17): 1989-2003.
46. Shi L, Xun W, Yue W, et al. Effect of elemental nano-selenium on feed digestibility, rumen fermentation, and purine derivatives in sheep. *Anim Feed Sci Technol* 2011; 163: 136-142.
47. Shi L, Xun W, Yue W, et al. Effect of sodium selenite, Se-yeast and nano-elemental selenium on growth performance, Se concentration and antioxidant status in growing male goats. *Small Ruminant Res* 2011; 96(1): 49-52.
48. Hu CH, Li YL, Xiong L, et al. Comparative effects of nano elemental selenium and sodium selenite on selenium retention in broiler chickens. *Anim Feed Sci Technol* 2012; 177(3-4): 204-210.
49. Cai SJ, Wu CX, Gong LM, et al. Effects of nano-selenium on performance, meat quality, immune function, oxidation resistance, and tissue selenium content in broilers. *Poult Sci* 2012; 91(10): 2532-2539.
50. El-Deep MH, Ijiri D, Ebeid TA, et al. Effects of dietary nano-selenium supplementation on growth performance, antioxidative status, and immunity in broiler chickens under thermoneutral and high ambient temperature conditions. *J Poult Sci* 2016; 53(4): 274-283.