

An outbreak of *Fusobacterium necrophorum* associated foot rot in a herd of four-horned antelope (*Tetracerus quadricornis*) in India

Susitha Rajkumar^{1*}, Loveleen Maria Vaz², Mathavan Anandhi¹, Karikalan Mathesh³, Shivasharanappa Nayakvadi⁴, Solomon Rajkumar¹, Shirish Dadarao Narnaware^{1*}

¹ ICAR- Central Coastal Agricultural Research Institute, Goa, India; ² Directorate of Animal Husbandry and Veterinary Services, Goa, India; ³ ICAR- Indian Veterinary Research Institute, Bareilly, India; ⁴ ICAR-National Institute of Veterinary Epidemiology and Disease Informatics, Bengaluru, India.

Article Info	Abstract
<p>Article history:</p> <p>Received: 09 May 2024 Accepted: 11 September 2024 Available online: 15 January 2025</p> <p>Keywords:</p> <p>Foot rot Four-horned antelope <i>lktA</i> gene Pathology Polymerase chain reaction</p>	<p>An outbreak of contagious foot rot due to <i>Fusobacterium necrophorum</i> infection was reported in a herd of four-horned antelopes (<i>Tetracerus quadricornis</i>) in a wildlife sanctuary at Goa, India. The infected animals showed signs of anorexia, limping and foot lesions, like erosions and sloughing of hooves. Mortality was recorded in two antelopes in which gross lesions, like generalized congestion of skeletal muscles and internal organs, and multi-focal to coalescing abscesses in lung, pleura, and diaphragm were observed. Histopathological evaluation of interdigital skin showed zones of coagulative necrosis, infiltration of mononuclear inflammatory cells, congestion, hemorrhage, and thrombosis in the dermis. Lung showed extensive areas of consolidation with alveolar edema, hyperemic alveolar capillaries, hemorrhage, and infiltration of inflammatory cells. The bacterial culture from heart blood, lung, liver, and kidney tissues revealed isolation of <i>F. necrophorum</i> being also confirmed by polymerase chain reaction (PCR) using amplification of <i>lktA</i> gene of <i>F. necrophorum</i>. In addition, the PCR also confirmed the presence of <i>F. necrophorum</i> DNA in the interdigital skin, lung, and liver tissues. Phylogenetic analysis showed that the <i>F. necrophorum</i> isolate from the present study grouped closely with isolates from Australia, China, Pakistan, and Iraq, as well as an Indian isolate from goat. The affected live animals were treated with oral antibiotics, anti-inflammatory medicines, and vitamin supplements for seven days, and recovered. This study confirmed the first outbreak of contagious foot rot and systemic infection with <i>F. necrophorum</i> in a herd of four-horned antelopes in India.</p> <p>© 2025 Urmia University. All rights reserved.</p>

Introduction

Contagious foot rot is a common disease of domestic ruminants worldwide. It is a multi-factorial disease, mainly causing erosions and foul-smelling lesions of the interdigital skin and soft tissues. The disease is characterized by swelling of the interdigital skin, coronet, pastern, and fetlock in addition to destruction of the hard keratin in the hoof and sloughing of hoof, leading to lameness.¹ Although several bacteria and yeast species have been isolated from infected claws and hoofs, *Dichelobacter nodosus* and *Fusobacterium necrophorum* are mostly associated with necrotic lesions and disease severity.² Although *F. necrophorum* is considered as an opportunistic pathogen,

it can cause severe necrotic lesions in various organs known as necrobacillosis.³ Important manifestations reported in *F. necrophorum* infections include digital necrobacillosis, liver abscesses, and necrotizing stomatitis in cattle, and foot abscesses, foot rot, and abortion in sheep.⁴ Necrobacillosis has also been reported in many wild animal species, like mule deer, white-tailed deer, elk, caribou, and sambar deer.⁵

The four-horned antelope (*Tetracerus quadricornis*) is confined to the Indian subcontinent, occurring widely from the foothills of the Himalayas in the north to the Deccan Plateau in the south of India. It is listed as vulnerable by the International Union for Conservation of Nature due to the low population, decreasing population

*Correspondences:

Shirish Dadarao Narnaware. BVSc & AH, MVSc, PhD
ICAR- Central Coastal Agricultural Research Institute, Goa, India
E-mail: shirish.narnaware@icar.gov.in
Susitha Rajkumar. BVSc & AH, MVSc, PhD
ICAR- Central Coastal Agricultural Research Institute, Goa, India
E-mail: susitha.rajkumar@icar.gov.in

trend, and habitat destruction.⁶ In India, the species is protected under Schedule-I of the Wildlife Protection Act (1972) of India, where about 95.00% of its global population is known to occur. It prefers dry deciduous forested habitat and hilly terrain, and is considered a solitary, elusive, cryptic, and shy species due to which it is little studied and reports regarding its disease status are barely available.⁷

In the present study, for the first time an outbreak of foot rot and mortality due to *F. necrophorum* infection in a herd of four-horned antelope at a wildlife sanctuary in Goa, India was reported.

Materials and Methods

Study area and samples. The present outbreak of foot rot was recorded in a herd consisting of seven four-horned antelopes maintained in free range at a wildlife sanctuary located at North Goa, India, in February 2023. Goa region has a tropical monsoon climate and is situated on the west coast of India bordered by Arabian Sea on the west, Karnataka on the South, Maharashtra on the North, and Western Ghats on the East, and lies between the latitudes 14°53'54" N and 15°40'00" N and longitudes 73°40'33" E and 74°20'13" E. During the outbreak, clinical signs were observed and post-mortem examination of one dead animal was carried out. The gross lesions were recorded and heart blood and representative tissue samples from lung, liver, kidney, and foot skin were collected in sterile vials and transported to the laboratory in cold chain for DNA isolation. Tissue samples were also collected in 10.00% neutral buffered formalin for histopathological studies. The handling of the animals was conducted as per the guidelines of the Committee for the Purpose of Control and Supervision of Experiments on Animals, India, and approval of the Institute Animal Ethics Committee (2118/GO/RBi-S/R/-L/21/CPCSEA) of Central Coastal Agricultural Research Institute, Old Goa, India.

Pathogen identification. For bacterial isolation, the swabs from heart blood, lungs, liver, and foot skin were collected during post-mortem examination and transported to the laboratory in cold chain. The swabs were streaked on blood agar plates and incubated aerobically and anaerobically for 24 hr. The bacterial growth was identified by Gram staining and DNA was extracted from the colonies using boiling and snap chilling method.⁸ The DNA isolation was also carried out in foot skin, lung, and liver tissues and heart blood using DNeasy Blood and Tissue DNA Kit (Qiagen, Hilden, Germany). The DNA samples from culture and tissues were screened by polymerase chain reaction (PCR) using specific primers for detection of *Pasteurella multocida*,⁹ *Escherichia coli*,¹⁰ *D. nodosus*, and *F. necrophorum*.¹¹

Histopathology. The tissue samples from various organs were processed for histopathological analyses

by paraffin embedding and cutting into 4.00- μ m thick sections. The sections were stained using Hematoxylin and Eosin, mounted using DPX mountant (Himedia, Mumbai, India), and examined under a light microscope (Leica Microsystems, Wetzlar, Germany).

Phylogenetic analysis. The leukotoxin encoding *lktA* gene of *F. necrophorum* was amplified and sequenced at a commercial DNA sequencing facility (Mediomix Genomics Services, Bangalore, India), and phylogenetic analysis was conducted using sequences retrieved from National Center for Biotechnology Information (NCBI). The sequence was submitted to NCBI with GenBank accession number of OR762215. The sequences were aligned in CLUSTAL W Multiple Sequence Alignment Program (UCD, Dublin, Ireland) and subjected to the MEGA Software (version X; BioDesign Institute, Tempe, USA) tool for evolutionary analysis. The phylogenetic studies were undertaken by the Maximum Likelihood method with the Tamura and Nei model with the highest log likelihood to infer evolutionary relatedness.¹² The pair-wise nucleotide sequence distance matrix was calculated with MegAlign program version 5.00 of DNASTAR software (DNASTAR, Madison, USA). The present outbreak of contagious foot rot due to *F. necrophorum* infection was recorded in total four out of seven adult four-horned antelopes (*T. quadricornis*) in a wildlife sanctuary at Goa, India. Among the affected animals, mortality was recorded in two antelopes aged 3 - 5 years within a span of 2 days. All the affected animals in the herd showed signs of limping, anorexia, and foot lesions. Apart from foot lesions, the animals in the herd appeared healthy with good body condition score. However, the affected animals developed anorexia and lameness 2 - 3 days prior to death. The affected animals in the herd were treated according to the protocol outlined by Baird *et al.*¹³ Initially, the affected animals were given oral antibiotics, like tetracycline powder (Intervet India, Pune, India), at the dose of 1.00 g per 15.00 kg *per* day, for 5 days followed by 45.00 mg kg⁻¹ *per* day of amoxicillin clavulanate powder (Carecorp Biotech Private, Patna, India) for 7 days. In addition, oral anti-inflammatory medicines, including 1.00 mg kg⁻¹ *per* day meloxicam suspension (INTAS Animal Health, Ahmedabad, India) along with oral multi-vitamin supplements (Vimeral®; Virbac Animal Health India Pvt. Ltd., Mumbai, India) containing A, D₃, E, and B₁₂ vitamins were also given for 5 days. After start of treatment, two animals were recovered within a week. During the outbreak, symptoms of foot rot disease were not observed in other wild ruminants *viz.*, spotted deer, sambar deer, barking deer, black buck, and Indian bison living in the same wildlife sanctuary. The bacterial culture on blood agar inoculated with swabs taken from heart blood, lung, liver, and kidney tissues yielded mixed Gram-negative and Gram-positive rod-shaped organisms in aerobic cultures. Whereas, in anaerobic cultures only Gram-negative bacilli were observed.

The DNA obtained from the anaerobic blood agar colonies produced 400 bp product of *lktA* gene of *F. necrophorum* in PCR. In addition, the *lktA* gene of *F. necrophorum* was also amplified from the DNA extracted from interdigital skin, lung, and liver tissues. In addition, the heart blood sample cultured on MacConkey agar showed isolation of *E. coli* colonies being also confirmed by PCR using DNA extracted from bacterial colony. All the DNA samples were negative for *P. multocida* and *D. nodosus* in PCR.

Results

On post-mortem examination, both dead carcasses showed sloughed off hooves leaving dark area of necrotic subcutaneous tissues. One live affected animal also showed sloughed off hoof on one side of the foot, leaving highly congested and necrotic subcutaneous tissue. In addition to foot lesions, severe generalized congestion of skeletal muscles, congestion of serosa of thoracic and abdominal organs, presence of multiple blood clots in the thoracic cavity, and extensively congested and consolidated lungs with presence of multi-focal to coalescing abscesses in right cardiac and diaphragmatic lobes of lung and over the pleura were also recorded. The liver and kidneys showed severe diffuse congestion on gross examination.

The histopathological evaluation of skin over the sloughed hoof showed multiple suppurative areas in the dermis and subcutaneous tissue, characterized by extensive zone of coagulative necrosis with degenerated cells and engorged blood capillaries (Fig. 1A). Fibrin deposits and severe infiltration of neutrophils along with infiltration of mononuclear cells, mainly lymphocytes, were seen in area adjacent to necrotic tissue in the dermis. Area adjacent to abscess in the dermis showed hemorrhage, abundant engorged capillaries, and occasional thrombosis.

The lung was the most severely affected organ showed multi-focal areas of suppurative inflammation, characterized by zone of coagulative necrosis, consisting of necrotic and degenerated cells, demarcated by fibrous tissue proliferation and infiltration of mixed population of neutrophils and lymphocytes (Fig. 1B). In addition, the lung parenchyma showed extensive areas of consolidation with alveolar edema, congested alveolar capillaries, diffuse hemorrhage, and intra-alveolar spaces filled with erythrocytes and fibrin. Some areas in lung parenchyma showed severe lesions, where the alveolar structure was lost and the entire parenchyma was replaced with necrotic mass, inflammatory infiltrates, and edematous fluid in addition to diffuse hemorrhages and thrombosis of small blood vessels.

Histopathological analyses of liver showed congestion of portal vein and focal infiltration of inflammatory cells, mainly lymphocytes, in the portal area. Some areas near

the periphery showed coagulative necrosis and hyperemia of sinusoidal capillaries. The histopathological examination of kidneys revealed interstitial nephritis with infiltration of inflammatory cells, mainly lymphocytes, around the bowman's corpuscles in the cortex and between renal tubules in the medulla along with engorged blood vessels and degenerative changes in tubular epithelia.

The 400 bp *lktA* gene of *F. necrophorum* was successfully amplified from DNA extracted from foot rot tissue samples, as well as bacterial culture. The sequencing and phylogenetic analysis of partial *lktA* sequence obtained in this study, with published sequences of six isolates from India and 21 isolates from different countries using MEGA X revealed that the isolates were broadly grouped into three distinct clusters/clades (Fig. 2). The *lktA* gene sequence of the present study named as *Goa Fusobacterium necrophorum* 1 (GFN1) was grouped closely in a big cluster, including isolates from Pakistan, New Zealand, China, Iraq, and Australia, and Indian isolates from Andhra Pradesh and Kerala.

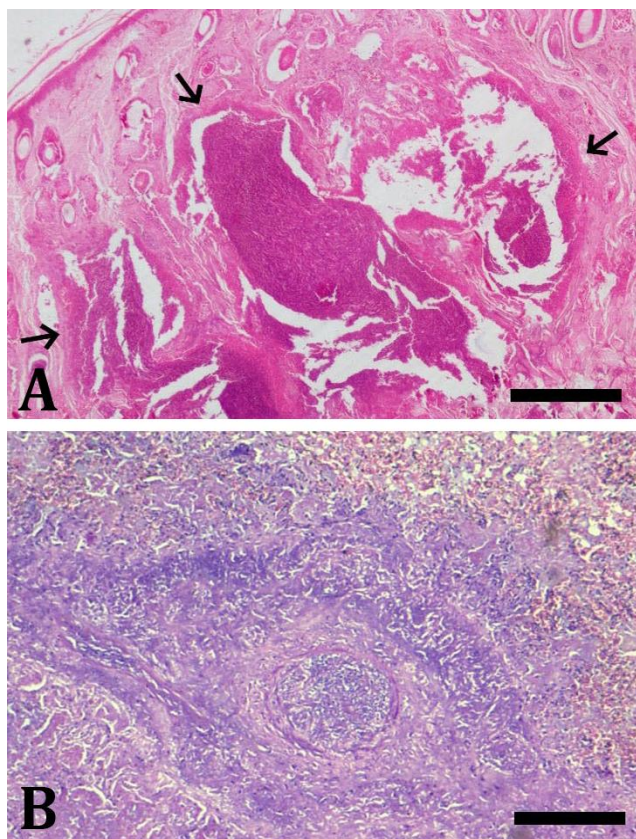


Fig. 1. Histopathological findings. **A)** An area of suppurative inflammation in the dermis (arrows), characterized by extensive zone of coagulative necrosis with degenerated cells and engorged blood capillaries; **B)** Photomicrograph of lung showing an area of suppurative inflammation, consisting of necrotic and degenerated cells, demarcated by zone of fibrous tissue proliferation and infiltration of neutrophils and lymphocytes (Hematoxylin and Eosin staining, Bars = 500 μ m).

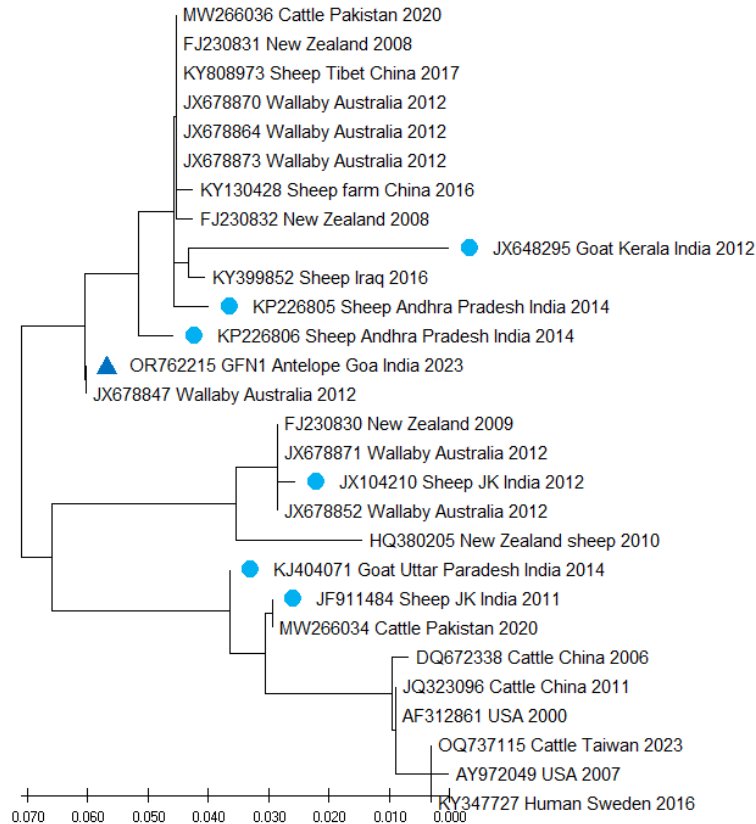


Fig. 2. Phylogenetic analysis of the *lktA* gene of *Fusobacterium necrophorum* isolate of the present study named as Goa *Fusobacterium necrophorum* 1 (triangle mark) with isolates from India (marked as circles) and other countries using the Neighbor-Joining method.

The pair-wise distance matrix for nucleotide showed that the GF1 isolate showed maximum similarity of 100% with isolate from Australia (JX678847) followed by 98.50% similarity with isolates from Australia (JX678870), Tibet (KY808973), China (KY130428), and Pakistan (MW266036). In addition, the GFN1 sequence showed 93.20%, 94.50%, 95.60%, and 98.50% nucleotide identity with Indian isolates from Jammu Kashmir (JX104210), Kerala (JX648295), Uttar Pradesh (JK404071), and Andhra Pradesh (KP226805), respectively.

Discussion

The *F. necrophorum* is reported to be a normal inhabitant of the mouth and gastrointestinal tract of ruminants and an opportunistic pathogen associated with several necrotic disease conditions, like foot rot, liver abscesses, calf diphtheria, mastitis, and septicemia in ruminants, including wildlife.^{3,14,15} Predisposing factors linked in the pathogenesis of foot rot are damp soil, injury to the skin of the interdigital area, and overcrowding.¹³

Foot rot outbreaks are commonly reported in wet seasons due to the faster spread of bacteria and higher survivability in soil.¹⁶ The present outbreak was recorded in a wildlife sanctuary located at Goa being a coastal region

having long rainy season from June to October with a very heavy rainfall pattern and comparatively cooler weather from November to February. However, the dampness in the soil persists till the starting of March. Although the four-horned antelopes of the present study were in a wildlife facility in which they were maintained in a natural ecosystem without crowding, since this wildlife sanctuary is mostly covered with moist deciduous forest with small patches of semi-evergreen forest and cane along streams, the wet conditions last for longer time. This peculiar environment was responsible for causing dampness in the soil in the area inhabited by four-horned antelopes. Moreover, during the February, the temperature starts increasing during daytime which might have imposed considerable stress in the animals and precipitated the disease and mortality.

In agreement with the findings of the present study, foot swelling with deep ulcers in skin, and inflammation, edema, and necrosis of subcutaneous tissue along with fibrosis, vasculitis, and thrombosis were reported in foot rot infection in Reindeer.¹⁴ The visceral lesions in the present outbreak were also comparable with necrobacillosis caused by *F. necrophorum* infection in domestic and wildlife species, such as elks (*Cervus canadensis*),¹⁷ pronghorn antelope,¹⁸ and sheep.¹⁹ Similar to the several

outbreaks of *Fusobacterium* infections in wildlife, and as per the findings of the present study, the disease became systemic, affecting visceral organs leading to the death of animals. In the present case, major visceral lesions were seen in lungs being comparable with the previous outbreak of necrobacillosis caused by *F. necrophorum* in lambs, characterized by infiltration of degenerated leukocytes, hyperemia, neutrophil infiltration, and fibrin deposition in the alveolar lumen.¹⁹ Similarly, focal areas of coagulative necrosis and suppurative inflammation in liver as recorded in the present study were earlier reported in lambs and cattle.^{3,19} Studies have shown that multiple *F. necrophorum* variants of *lktA* may contribute to the severity and duration of foot rot lesions.²⁰

Although culture is the common method for identification of *F. necrophorum*, since the sampling site is often contaminated with other pathogens and the bacterium is obligate anaerobe requiring special medium for the growth, the isolation is difficult.²¹ Hence, PCR is considered to have more advantage over the culture in identification and confirmation of *F. necrophorum*.¹¹ The sequencing and phylogenetic analysis of partial *lktA* sequence showed close relationship with the isolates from India, Pakistan, New Zealand, China, Iraq, and Australia. However, more comprehensive phylogenetic studies involving a large number of isolates and molecular markers are required to understand the molecular epidemiology of *F. necrophorum* isolates from wildlife.

In conclusion, the present study confirmed the first outbreak of foot rot in Indian four-horned antelopes due to acute systemic *F. necrophorum* infection. The acute mortality in the affected animals could be attributed to the systemic spread of bacteria and extensive lesions in the lungs. It is speculated that dampness in the soil along with sudden change in the weather conditions might have precipitated the disease outbreak in the herd.

Acknowledgments

The authors are thankful to the Director, ICAR- Central Coastal Agricultural Research Institute, Goa, India, for providing the necessary facilities to carry out this work.

Conflict of interest

The authors declare that they have no known competing financial interests or personal relationships that could have appeared to influence the work reported in this paper.

References

1. Monrad J, Kassuku AA, Nansen P, et al. An epidemiological study of foot rot in pastured cattle. *Acta Vet Scand* 1983; 24(4): 403-417.
2. Atia J, Monaghan E, Kaler J, et al. Mathematical modeling of ovine foot rot in the UK: the effect of *Dichelobacter nodosus* and *Fusobacterium necrophorum* on the disease dynamics. *Epidemics* 2017; 21: 13-20.
3. Nagaraja TG, Narayanan SK, Stewart GC, et al. *Fusobacterium necrophorum* infections in animals: pathogenesis and pathogenic mechanisms. *Anaerobe* 2005; 11(4): 239-246.
4. Radostits OM, Gay CC, Hinchcliff KW, et al. *Veterinary medicine: A Textbook of the diseases of cattle, horses, sheep, pigs and goats*. 10th ed. London, UK: Saunders 2007; 1061-1080.
5. Leighton AF. *Fusobacterium necrophorum* infection. In: Williams ES, Barker IK (Eds). *Infectious diseases of wild mammals*. 3rd ed. Ames, USA: Iowa State University Press 2001; 493-496.
6. IUCN SSC Antelope Specialist Group. *Tetracerus quadricornis*. The IUCN red list of threatened species 2017; e.T21661A50195368. Available at: <https://www.iucnredlist.org/species/21661/50195368>. Accessed Jan 10, 2024.
7. Sahu S, Panda SK, Sahoo N. Black quarter outbreak in four-horned antelopes at Nandankanan Zoological Park. *Indian Vet J* 2016; 93(01): 59-60.
8. Singh NK, Upadhyay AK, Kamboj A, et al. Evaluation of various methods for genomic DNA extraction from pure cultures of lysis resistant campylobacters isolated from wild animals. *J Anim Res* 2022; 12(05): 775-781.
9. Townsend KM, Frost AJ, Lee CW, et al. Development of PCR assays for species- and type-specific identification of *Pasteurella multocida* isolates. *J Clin Microbiol* 1998; 36(4): 1096-1100.
10. Yokoigawa K, Inoue K, Okubo Y, et al. Primers for amplifying an alanine racemase gene fragment to detect *E. coli* strains in foods. *J Food Sci* 1999; 64(4): 571-575.
11. Ozgen EK, Cengiz S, Ulucan M, et al. Isolation and identification of *Dichelobacter nodosus* and *Fusobacterium necrophorum* using the polymerase chain reaction method in sheep with footrot. *Acta Vet Brno* 2015; 84: 97-104.
12. Tamura K, Nei M. Estimation of the number of nucleotide substitutions in the control region of mitochondrial DNA in humans and chimpanzees. *Mol Biol Evol* 1993; 10(3): 512-526.
13. Baird AN, Shipley CF. Diseases of the musculoskeletal system. In: Pugh DG, Baird AN, Edmondson MA, et al (Eds). *Sheep, goat and cervid medicine*. 3rd ed. Philadelphia, USA: Elsevier 2021; 251-280.
14. Handeland K, Boye M, Bergsjø B, et al. Digital necrobacillosis in Norwegian wild tundra reindeer (*Rangifer tarandus tarandus*). *J Comp Pathol* 2010; 143(1): 29-38.
15. Frosth S, König U, Nyman AK, et al. Characterisation of

- Dichelobacter *nodosus* and detection of *Fusobacterium necrophorum* and *Treponema* spp. in sheep with different clinical manifestations of footrot. *Vet Microbiol* 2015; 179(1-2): 82-90.
16. Sertkaya H, Sindak N. Incidence and treatment with two different drug combinations of sheep's footrot in Birecik District of Şanlıurfa and its villages. *Turk J Vet Surg* 2004; 10: 48-54.
 17. Murie OJ. An epizootic disease of elk. *J Mammal* 1930; 11: 214-222.
 18. Edwards JF, Davis DS, Roffe TJ, et al. Fusobacteriosis in captive wild-caught pronghorns (*Antilocapra americana*). *Vet Pathol* 2001; 38(5): 549-552.
 19. Karakurt E, Dağ S, Çelebi Ö, et al. A necrobacillosis case determined in a sheep herd. *MAE Vet Fak Derg* 2019; 4(1): 41-44.
 20. Farooq S, Wani SA, Hassan MN, et al. The detection and prevalence of leukotoxin gene variant strains of *Fusobacterium necrophorum* in footrot lesions of sheep in Kashmir, India. *Anaerobe* 2018; 51: 36-41.
 21. Tadepalli S, Narayanan SK, Stewart GC, et al. *Fusobacterium necrophorum*: a ruminal bacterium that invades liver to cause abscesses in cattle. *Anaerobe* 2009; 15(1-2): 36-43.