

Post-treatment with metformin improves random skin flap survival through promoting angiogenesis in rats

Mojtaba Karimipour¹, Gholam Hossein Farjah^{1,2*}, Morteza Hassanzadeh¹, Masoumeh Zirak Javanmard¹

¹ Department of Anatomical Sciences, School of Medicine, Urmia University of Medical Sciences, Urmia, Iran; ² Neurosciences Research Center, School of Medicine, Urmia University of Medical Sciences, Urmia, Iran.

Article Info

Article history:

Received: 13 April 2020
Accepted: 28 June 2020
Available online: 15 June 2022

Keywords:

Metformin
Rat
Skin flap
Survival
Vascular endothelial growth factor

Abstract

Skin flap necrosis has been remained as an unsolved problem in plastic and reconstructive surgeries. Here, we explored the effects of metformin post-treatment on random skin flap survival in rats. An 8.00 × 2.00 cm dorsal skin flap was created in 24 rats and they were then divided into three groups (n = 8) including Control, metformin (Met) 50.00 mg kg⁻¹ and Met 100 mg kg⁻¹. All animals were administrated orally until seven days after flap surgery. Flap survival, the number of blood vessels and mast cells in the flap tissues were analyzed. Vascular endothelial growth factor (VEGF) expression levels in flap tissues was also determined using immunohistochemical methods. The percentage of survival area in Met 50.00 mg kg⁻¹ and Met 100 mg kg⁻¹ groups were significantly higher compared to control. The blood vessel density and the VEGF positive cells in the viable areas of flaps showed a significant increase in Met 50.00 mg kg⁻¹ group compared to control group. The results of this study suggested that treatment with metformin, especially with low dose following skin flap surgery was effective in improving the flap survival and increasing the neovascularization in the flaps tissues of rats.

© 2022 Urmia University. All rights reserved.

Introduction

The surgical random skin flap is one of the most popular surgical technique in plastic and reconstructive surgeries. This kind of surgical method is often used to repair massive skin damage and underlying soft tissue injuries resulting from congenital and acquired defects following trauma or surgical procedure like tumor excision.^{1,2} Due to the lack of specific vessels in random skin flaps, their viability is largely dependent on the early formation of new blood vessels in the pedicle of the flap.^{3,4} The skin flap, which is a skin transfer, is technically simple and in terms of color, texture and thickness can largely match with the graft site tissues.⁵

The necrosis and loss of the skin after flap surgery are devastating events, especially when this graft is the last available resource for treating patients with large skin defects.¹ Thus, postoperative necrosis and failure of skin flaps are the major concern of surgeons in this procedure.⁶ These complications are believed to be due to insufficient flap perfusion and ischemia-reperfusion injury which is

associated with lack of adequate blood flow and impaired venous drainage.^{7,8} Consequently, surgeons are not always able to predict the survival rate of the flap after surgery. This can lead to high-cost hospital and surgical practice and unnecessary additional operation.⁵

To address this issue, numerous approaches such as low-level laser therapy⁹ and low dose radiation¹⁰ as well as several pharmacological drugs and agents such as vasodilators, anti-coagulants, free radical scavengers and calcium blockers have been used to reduce or prevent tissue necrosis following skin flap surgery.¹¹⁻¹³ The clinical application of some of these drugs has undesired side effects so the investigation continues to find a cost-effective drug without systemic effects.

Metformin, a popular biguanide antidiabetic, is known as a first line drug in the clinic for treatment of type-2 diabetic and was introduced about 60 years ago.¹⁴ The effect of metformin in suppressing blood glucose is mainly associated with the inhibition of gluconeogenesis in the liver mediated through activation of AMP-activated protein kinase (AMPK) which is activated following

*Correspondence:

Gholam hossein Farjah. PhD

Department of Anatomical Sciences, School of Medicine, Urmia University of Medical Sciences, Urmia, Iran | Neurosciences Research Center, School of Medicine, Urmia University of Medical Sciences, Urmia, Iran

E-mail: farjah.gh@umsu.ac.ir



This work is licensed under a Creative Commons Attribution-NonCommercial 4.0 International License which allows users to read, copy, distribute and make derivative works for non-commercial purposes from the material, as long as the author of the original work is cited properly.

changes in cellular energy levels.^{15,16} Recently, various experimental studies have shown that metformin has beneficial effects in the other disease and its therapeutic effect is not limited to the ability to lower blood glucose levels. For example, it has been shown that metformin is neuroprotective and decrease cell death in the Alzheimer's disease.¹⁷ Also, a prior study has reported antioxidant and anti-inflammatory properties of metformin and through modulating inflammatory and antioxidant pathway protect the cells in the transient global cerebral ischemia.¹⁸

Several experimental studies have focused on the beneficial role of metformin on wound repair and indicated that supplementation with metformin accelerated wound healing process. In a previous study, it was shown that metformin accelerated wound closure and stimulated angiogenesis in diabetic mice and it was also reported that the decreased number of circulating endothelial progenitor cells (EPCs) in diabetic mice was significantly increased following metformin treatment.¹⁹ The authors of the report cited above indicated that ability of tube formation and migration of bone marrow-derived endothelial progenitor cells (BM-EPCs) were impaired in diabetic mice and metformin improved it. Metformin pharmacologically has been shown to have anti-aging effects. In a prior study it was reported that metformin promoted wound healing and cutaneous integrity in skin of aging rats.²⁰ In another study it was reported that metformin through improving angiogenesis contributed to wound healing and it was, in parts, associated with stimulation of nitric oxide (NO) and inhibition of superoxide (O₂⁻).²¹

To the best of our knowledge, there are limited data on the beneficial role of metformin in improving the skin flap viability. In a recent study it was indicated that pretreatment, before flap creation, with a single dose of metformin through NO system improved skin flap survival.²² Meanwhile, in another study it was reported that the mice treated with metformin for seven days before flap surgery until euthanizing on 7th day post-operation improved the flap viability.²³ There is no previous report regarding the effects of metformin post treatment on the survival of random-pattern skin flaps. Therefore, the main objective of the current study was to focus on the therapeutic effects of metformin treatment after skin flap surgery in rats in order to improve flap survival.

Materials and Methods

Animals. Random skin flaps were created in 24 healthy male adult rats weighing between 220 - 240 g. The study was performed in accordance with Guide for the Care and Use of Laboratory Animals and the experimental protocols were approved by Urmia University of Medical Sciences Ethics Committee (Ir.UMSU.rec.1395.22). The rats were maintained at a room temperature of 22.00 -

24.00 °C with free access to food and water. The animals were randomly divided into three groups of eight rats each. Group I (control group) received water intragastric, Group II received Met (50.00 mg kg⁻¹ per day) and Group III received Met (100 mg kg⁻¹ per day). Metformin (Mahan Chemi Co., Tehran, Iran) was dissolved in water and administrated via intragastric gavage. The first gavage was 2 hr after flap creation and was repeated until the end of the study on seven days post-operation. The dose of 50.00 and 100 mg kg⁻¹ metformin were selected according to the previous study.²⁴

Random skin flap model. In this regard, the rats were anesthetized with an intraperitoneal dose of ketamine (60.00 mg kg⁻¹, Alfasan, Woerden, The Netherlands) and xylazine (10.00 mg kg⁻¹, Alfasan). After anesthesia, the animals were immobilized in a prone position and then their dorsal regions were shaved and disinfected using povidone iodine solution. A caudally based Mc Farlane skin flap model (2.00 × 8.00 cm) was created at the same position on the back of each animal. After this procedure, the flaps were sutured back using 4-0 silk (Supa Medical Devices, Tehran, Iran) to its original position immediately.^{25,26} Following flap surgery, the rats were housed in individual cages until the end of the experiment.

Flap survival assessment. Seven days after skin flap surgery, the animals were re-anesthetized and the survival and necrotic areas in each flap were demarcated on a transparent paper and then cut and weighed the paper using a precision scale. Then, the percentage of survival rate of each animal was calculated formulas follows:²⁷

$$\text{Percentage of skin flap survival} = (\text{Weight of survival area} / \text{Total weight of paper}) \times 100$$

The alive areas of the flap were identified by gross observation and were warm and soft to the touch, but the necrotic areas were dark in color, stiff and hairless.

Histological evaluations. Seven days after flap creation, the rats were euthanized using overdose of ketamine and xylazine solution. Then, skin tissue specimens were obtained from the same place of the surviving area of the flap. The skin tissues were immediately fixed at 10.00% buffered formalin, embedded in paraffin and then, sectioned into 6.00 μm slices and stained with Hematoxylin and Eosin (H&E). To determine blood vessel density, the vessels were counted in five fields on H&E-stained slides at 100× magnification.²⁷ In addition, to determine the number of mast cells in flap tissues, 6.00 μm sections was obtained from paraffin-embedded blocks and then stained with toluidine blue. The number of mast cells counted in five fields at 400× magnification.²⁸ All morphometric evaluations in the present study were performed by two persons blinded to treatment.

Immunohistochemical evaluation. To test the VEGF expression levels in flap tissues, the tissue sections from paraffin-embedded blocks were stained with primary anti-

VEGF antibody solution (Abcam Company, Waltham, USA), 1:200 dilution overnight at 4.00 °C. After washing with PBS, a secondary against antibody was added to slides for 45 min at 37.00 °C and washed again. The diaminobenzidine solution was used (10 min at room temperature) for color development. Lastly, the slides were counterstained with hematoxylin. The VEGF positive brown color cells were counted in two fields using a light microscope equipped with a micrometer lens at 400× magnification. This lens had 100 squares and only the cells within the square were counted.²⁹

Statistical Analysis. The results were shown as mean ± standard deviation (SD) and all statistical analysis was performed using one-way analysis of variance, with Tukey's post hoc to compare the means. The SPSS Software (version 16.0; SPSS, Chicago, USA) was used to analyze all variables. The differences were considered significant at $p < 0.05$.

Results

Skin flap survival. At the end of the seventh day after flap surgery, the mean ± SD of flap survival (%) in groups control, Met 50.00 mg kg⁻¹ and Met 100 mg kg⁻¹ were 64.43 ± 8.38, 79.91 ± 7.93 and 77.25 ± 5.90 percentage, respectively. The results showed significant differences between control and experimental groups ($p < 0.01$ and $p < 0.05$, respectively), (Figs. 1 and 2).

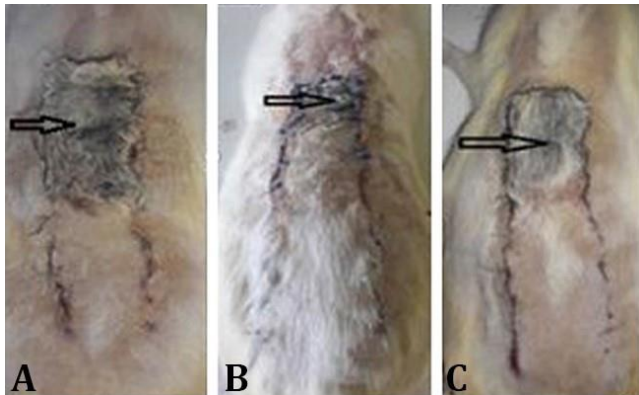


Fig. 1. Digital photograph of dorsal skin flaps in rats seven days post-operation. The arrows exhibit the necrotic areas. **A)** Control group, **B)** Metformin 50.00 mg kg⁻¹; **C)** Metformin 100 mg kg⁻¹.

Histological findings. Figure 3 shows the new blood vessels in the flap tissues in the studied groups. Seven days after flap surgery the mean number of vessels in group Met 50.00 mg kg⁻¹ (16.28 ± 2.42) significantly ($p < 0.001$) was higher than control group (11.57 ± 1.51). The mean of blood density in Met 100 mg kg⁻¹ was 12.85 ± 1.46 and it was higher than control, however, it was not significant. Figure 3 also shows the distribution of blood vessels in the inner side of the flap.

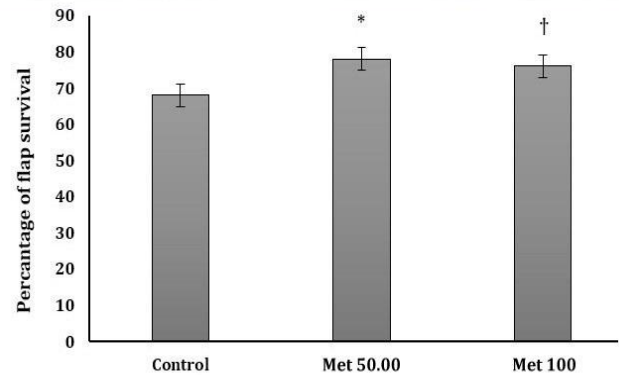


Fig. 2. The mean ± SD of flap survival (%) in the studied groups. *† Different symbols indicate significantly difference compared to control group (* $p < 0.01$ and † $p < 0.05$, respectively).

The number of mast cells in flap tissues were 20.12 ± 3.13 in control group, 24.62 ± 2.50 in Met 50.00 mg kg⁻¹ group and 23.75 ± 3.19 in Met 100 mg kg⁻¹ group. The means number was significantly higher in both groups treated with metformin compared to control group ($p < 0.01$ and $p < 0.05$, respectively), (Fig. 4).

VEGF levels in flaps. On day 7 after surgery, immunohistochemistry showed that the mean number of VEGF positive cells in the flap tissues were 7.20 ± 1.64, 11.00 ± 2.23 and 8.00 ± 1.58 in control, Met 50.00 and Met 100 mg kg⁻¹ groups, respectively. Significant differences ($p < 0.05$) were only observed between control and Met 50.00 mg kg⁻¹ groups (Fig. 5).

Discussion

The random skin flap is a surgical technique and has been widely used in plastic surgery to repair skin defects. Random skin flaps are not contained well-known blood vessels, thus, necrosis in the distal part of the flap is a common complication and remains as a major challenge. In experimental studies, several methods such drugs and agents have been used to increase skin flap perfusion in order to reduce rates of necrosis. In the present study, for the first time we showed that oral administration of metformin after flap creation enhanced flap viability. Furthermore, our findings also indicated that metformin increased neovascularization in flap tissue through increasing VEGF expression and blood vessel density.

Metformin, a clinical drug, is commonly used for the treatment of type 2 diabetes. Growing data on metformin indicated that this medical drug in addition to antiglycemic effects bears other impacts including antioxidant, anti-inflammatory on different disease models. Prior studies indicated that metformin has been beneficial to other ischemic tissue, such as myocardial and brain.^{24,30} Recently, we showed that supplementation of metformin reduced ischemia-reperfusion in experimental stroke in rats through inhibiting oxidative stress and inflammation.³⁰

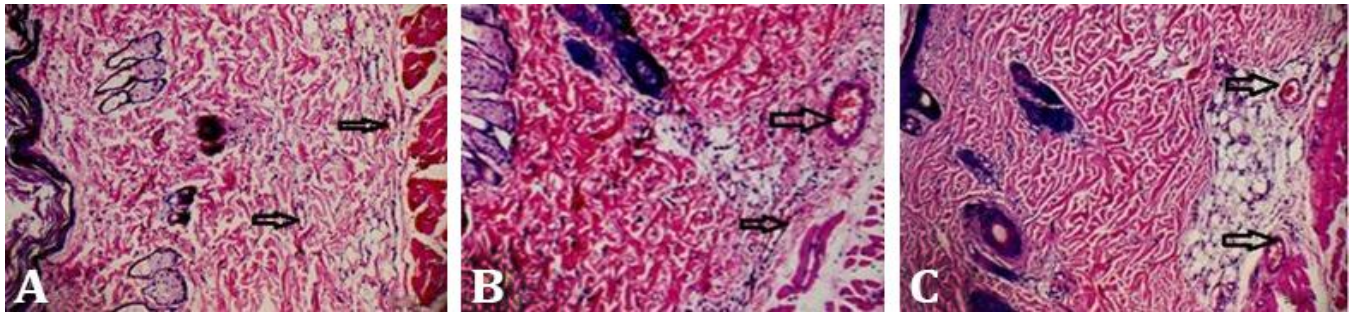


Fig. 3. Digital photographs of the inner side flaps in different groups on day 7 after surgery are showing blood vessel (arrows) formation in flaps **A)** Control group, **B)** Met 50.00 mg kg⁻¹ and **C)** Met 100 mg kg⁻¹ (H&E, 100×).

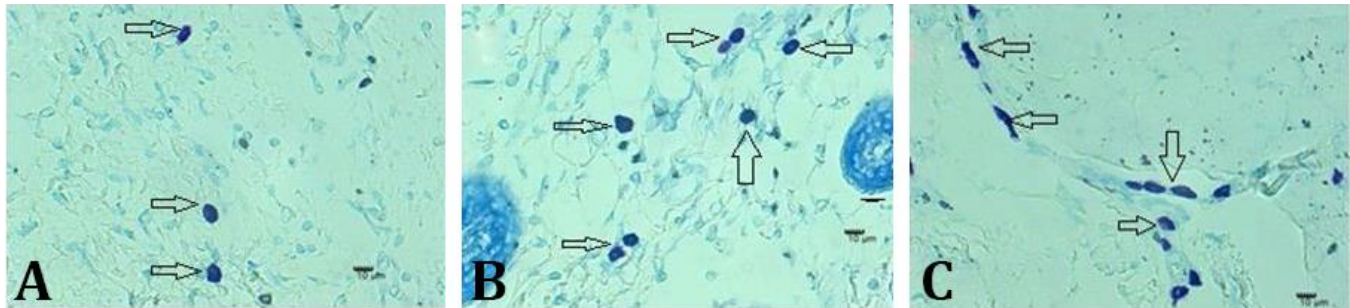


Fig. 4. Mast cells (arrows) in the flap tissue on day 7 after surgery (Toluidine blue, 400×) in different groups: **A)** Control group, **B)** Metformin 50.00 mg kg⁻¹ and **C)** Metformin 100 mg kg⁻¹.

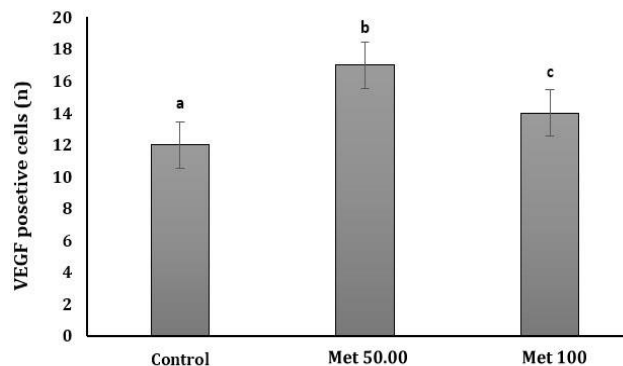


Fig. 5. Histogram of mean \pm SD of VEGF positive cells in flap tissue in the studied groups.

^{abc} different letters indicate significantly difference among the groups ($p < 0.05$).

A few previous studies reported the beneficial effects of metformin on the wound healing process. Yu *et al.* demonstrated that metformin activated angiogenesis and promoted wound closure in diabetic mice.¹⁹ In another experimental study it was shown that local application of metformin could improve cutaneous wound defects through angiogenesis.²⁰ The angiogenesis effects of metformin are mediated by activation of AMPK pathway.³¹ AMPK signaling is necessary to induce angiogenesis and is known to stimulate VEGF expression.³²

In a recent study it was also documented that treated mice with 200 mg kg⁻¹ metformin for 14 days (seven days before to seven days after flap surgery) improved the survival of skin flaps by alleviating oxidative stress, inducing

angiogenesis and inhibiting apoptosis and these positive effects of metformin were associated with activation of autophagy via AMPK-mTOR-TFEB signaling pathway.²³

In the current study, we found that treatment with 50.00 mg kg⁻¹ metformin after random skin flap significantly increased VEGF expression in comparison with the control group. The VEGF as an important pro-angiogenesis molecule, has been shown that is important for wound healing and induces neovascularization in ischemic areas.³³ VEGF is expressed by different cell types in injured skin such as keratinocytes, mast cells and macrophages.^{34,35} It is documented that VEGF stimulate the migration and proliferation of endothelial cells and promotes vascular permeability.²⁹ Furthermore, it has been shown that exogenous VEGF through increasing skin flap angiogenesis improve flap survival.³⁶ Studies have also documented that VEGF is a strong regulator of angiogenesis and induces neovascularization. Angiogenesis, or sprouting angiogenesis is the creation of new blood vessels from preexisting vessels and has an important role in tissue healing at injured sites which provides oxygen and nutrients to tissues.³⁷

Angiogenesis as a crucial and complicated process is involved in the proliferation of endothelial cells and also determines the fate of flap survival. Early angiogenesis initiation in flap tissue can guarantee the flap survival. In the process of angiogenesis, the role of matrix metallo-proteinase (MMPs) for extracellular matrix degradation is important. MMPs are produce by various cells such as fibroblasts, epithelial cells, smooth muscle, endothelial and inflammatory cells. It has been reported that for migration

of endothelial cells during angiogenesis the activity of MMPs is necessary.³⁸ In our study, immunohistochemical staining revealed that VEGF expression was markedly increased in the treated groups compared to control group. The vascular density was also increased in the metformin groups. These results indicated that metformin promoted angiogenesis, thereby, increasing the distribution of new blood vessels in the damaged tissue by increasing VEGF expression and increasing the blood supply. Through these effects flap survival might have been improved. However, these findings suggested a mechanism for the beneficial effect of metformin on the survival of random skin flaps.

With regard to mast cells, we observed a significant increase in the total number of mast cells in the skin flap tissue of animals treated with metformin. Mast cells are the source of numerous chemical mediators such as serotonin and histamine, which have vasoactive property and are able to increase vascular perfusion.²⁸

As stated earlier, high levels of VEGF expression and increased in vascular density were observed in flap of metformin groups. One possible reason could be due to contributing of mast cells in inducing angiogenesis through VEGF secretion. In a previous study, it was indicated that low dose radiation could induce tissue revascularization, at least in part, through mast cell production of VEGF.³⁹ However, this point requires to be soundly studied. In other reports such as one by Chehelcheraghi *et al.* who used bone marrow mesenchymal-derived stem cells in order to improve skin flap viability, found a significant increase in the number of mast cells in the flap tissue.⁴⁰ Another possible positive role of mast cells in the present study could be due to vasodilator effect of histamine which was released from mast cells.

Regarding the effects of metformin on EPCs and wound healing, published data is controversial. For example, Han *et al.* reported that metformin could improve wound healing and increase the quality of circulating EPCs and BM-EPCs in diabetic mice.²¹ On the contrary, it was indicated that metformin supplementation could not alter the circulating EPCs number and even led to delayed wound healing in diabetes.⁴¹ EPCs are precursors of endothelial cells and mobilize from bone marrow into the blood circulation and are associated with neo-vascularization after tissue injury.^{42,43}

In this study, we used two different doses of metformin aiming to increase viability of random skin flaps in rats. Our results showed that treatment with 50.00 mg kg⁻¹ metformin in comparison with 100 mg kg⁻¹ provided satisfactory results in terms of increased vascular density and expression of VEGF levels in skin flaps. This treatment led to significant reduction in the percentage of the necrotic area of flaps. The VEGF expression levels and blood vessel density were increased in the group received 100 mg kg⁻¹ metformin in comparison with control group,

however, it was not significant. Due to lack of information, no physiological explanations were found to these findings, thus, now we cannot explain why low dose of metformin had better outcomes in skin flap viability in rats and further studies are needed to elucidate it. Another study showed that the beneficial effects of metformin on flap survival were mediated through the nitric oxide (NO) pathway.²² They suggested a role for the nitric oxide in metformin-induced protective effects in random skin flaps. In that report, it was indicated that a single co-administration of metformin and L-arginine (nitric oxide precursor) had higher effects on the flap survival rate compared to metformin administration alone and the animals which received L-NAME (inhibitor of nitric oxide synthesis) showed the lowest flap viability rate. In another study it was documented that NO had an important role in the regulation of vascular tone and blood flow, and inhibited the platelet and neutrophil aggregation.⁴⁴ Also, it has been reported that exogenous NO therapy increased flap survival and maintained circulation in the flap.⁴⁵

Furthermore, previous studies have also confirmed the beneficial role of NO in IR damage and circulation of skin flap^{46,47} especially in the distal part of the flap which is predisposed to low blood flow and necrosis. Necrosis in the distal part of flap depends on vasodilator effects of NO, whereas, it has been reported that L-arginine through increasing blood flow to the skin can lead to an increase in the flap viability.^{22,47}

We did not measure the NO levels and oxidative stress that could be considered as limitations of the present study. The measurements of these assays could provide additional information to confirm involved mechanism of metformin-induced protective effects following flap surgery.

In conclusion, in the present study the levels of VEGF expression and vascular density (markers of neo-vascularization) were higher in flap of animals treated with 50.00 mg kg⁻¹ metformin in comparison with the 100 mg kg⁻¹ metformin and control groups indicating that metformin protected the flap from necrosis through VEGF-mediated angiogenesis. Also, histological examination of the flap tissues in metformin treated rats showed increased blood vessel dilation compared to control rats that contributed to increased blood flow and ultimately decrease in flap necrosis. However, we postulate treatment with metformin after flap surgery might have improved the flap viability via vasodilating effects which in turn increased blood flow in skin flap tissue.

Acknowledgments

The results described in this paper were part of student thesis. This work was financially supported by a grant from the Urmia University of Medical Sciences, Urmia, Iran. We also appreciate Mahan Chimi Company for providing metformin as a gift.

Conflict of interest

The authors declared that no competing interest exists.

References

- Cury V, Moretti AI, Assis L, et al. Low level laser therapy increases angiogenesis in a model of ischemic skin flap in rats mediated by VEGF, HIF-1 α and MMP-2. *J Photochem Photobiol B* 2013; 125: 164-170.
- Lu F, Mizuno H, Uysal CA, et al. Improved viability of random pattern skin flaps through the use of adipose-derived stem cells. *Plast Reconstr Surg* 2008; 121(1): 50-58.
- Chen L, Zhou K, Chen H, et al. Calcitriol promotes survival of experimental random pattern flap via activation of autophagy. *Am J Transl Res* 2017; 9(8): 3642-3653.
- Stell PM. Proceedings: The influence of retraction on the viability of a skin flap. *Br J Surg* 1976; 63(8): 669.
- Dölen UC, Sungur N, Koca G, et al. The vasodilator effect of a cream containing 10% menthol and 15% methyl salicylate on random-pattern skin flaps in rats. *Arch Plast Surg* 2015; 42(6): 695-703.
- Gould DJ, Hunt KK, Liu J, et al. Impact of surgical techniques, biomaterials, and patient variables on rate of nipple necrosis after nipple-sparing mastectomy. *Plast Reconstr Surg* 2013; 132(3): 330e-338e
- Yang M, Sheng L, Li H, et al. Improvement of the skin flap survival with the bone marrow-derived mononuclear cells transplantation in a rat model. *Microsurgery* 2010; 30(4): 275-281.
- Wang WZ, Baynosa RC, Zamboni WA. Update on ischemia-reperfusion injury for the plastic surgeon: 2011. *Plast Reconstr Surg* 2011; 128(6): 685e-692e.
- Baldan CS, Masson IF, Esteves Júnior I, et al. Inhibitory effects of low-level laser therapy on skin-flap survival in a rat model. *Plast Surg (Oakv)* 2015; 23(1): 35-39.
- Karimipour M, Amanzade V, Jabbari N, et al. Effects of gamma-low dose irradiation on skin flap survival in rats. *Phys Med* 2017; 40: 104-109.
- Rinker B, Fink BF, Barry NG, et al. The effect of calcium channel blockers on smoking-induced skin flap necrosis. *Plast Reconstr Surg* 2010; 125(3): 866-871.
- Chen W, Yang D, Wang P, et al. Microencapsulated myoblasts transduced by the vascular endothelial growth factor (VEGF) gene for the ischemic skin flap. *Aesthetic Plast Surg* 2011; 35(3): 326-332.
- Akgül GG, Yenidogan E, Gülçelik MA, et al. Effects of N-acetylcysteine on random skin flaps in rats. *Wounds* 2013; 25(3): 68-74.
- Mamputu JC, Wiernsperger NF, Renier G. Antiatherogenic properties of metformin: the experimental evidence. *Diabetes Metab* 2003; 29(4 Pt 2): 6S71-6S76.
- Hundal RS, Krssak M, Dufour S, et al. Mechanism by which metformin reduces glucose production in type 2 diabetes. *Diabetes* 2000; 49(12): 2063-2069.
- Tian R, Musi N, D'Agostino J, et al. Increased adenosine monophosphate-activated protein kinase activity in rat hearts with pressure-overload hypertrophy. *Circulation* 2001; 104(14): 1664-1669.
- Salminen A, Kaarniranta K, Haapasalo A, et al. AMP-activated protein kinase: a potential player in Alzheimer's disease. *J Neurochem* 2011; 118(4): 460-474.
- Ashabi G, Khalaj L, Khodaghali F, et al. Pre-treatment with metformin activates Nrf2 antioxidant pathways and inhibits inflammatory responses through induction of AMPK after transient global cerebral ischemia. *Metab Brain Dis* 2015; 30(3): 747-754.
- Yu JW, Deng YP, Han X, et al. Metformin improves the angiogenic functions of endothelial progenitor cells via activating AMPK/eNOS pathway in diabetic mice. *Cardiovasc Diabetol* 2016; 15: 88. doi:10.1186/s12933-016-0408-3.
- Zhao P, Sui BD, Liu N, et al. Anti-aging pharmacology in cutaneous wound healing: effects of metformin, resveratrol, and rapamycin by local application. *Aging Cell* 2017; 16(5): 1083-1093.
- Han X, Tao Y, Deng Y, et al. Metformin accelerates wound healing in type 2 diabetic db/db mice. *Mol Med Rep* 2017; 16(6): 8691-8698.
- Taleb S, Moghaddas P, Rahimi Balaei M, et al. Metformin improves skin flap survival through nitric oxide system. *J Surg Res* 2014; 192(2): 686-691.
- Wu H, Ding J, Li S, et al. Metformin promotes the survival of random-pattern skin flaps by inducing autophagy via the AMPK-mTOR-TFEB signaling pathway. *Int J Biol Sci* 2019; 15(2): 325-340.
- Soraya H, Khorrami A, Garjani A, et al. Acute treatment with metformin improves cardiac function following isoproterenol induced myocardial infarction in rats. *Pharmacol Rep* 2012; 64(6): 1476-1484.
- McFarlane RM, DeYoung G, Henry RA. The design of a pedicle flap in the rat to study necrosis and its prevention. *Plast Reconstr Surg* 1965; 35: 177-182.
- Karimipour M, Hassanzadeh M, Zirak Javanmard M, et al. Oral administration of alanyl-glutamine and glutamine improve random pattern dorsal skin flap survival in rats. *Iran J Basic Med Sci* 2018; 21(8): 842-847.
- Lin B, Lin Y, Lin D, et al. Effects of bezafibrate on the survival of random skin flaps in rats. *J Reconstr Microsurg* 2016; 32(5): 395-401.
- Pinfildi CE, Liebano RE, Hochman BS, et al. Effect of low-level laser therapy on mast cells in viability of the transverse rectus abdominis musculocutaneous flap. *Photomed Laser Surg* 2009; 27(2): 337-343.
- Bagdas D, Cam Etoz B, Inan Ozturkoglu S, et al. Effects

- of systemic chlorogenic acid on random-pattern dorsal skin flap survival in diabetic rats. *Biol Pharm Bull* 2014; 37(3): 361-370.
30. Karimipour M, Shojaei Zarghani S, Mohajer Milani M, et al. Pre-treatment with metformin in comparison with post-treatment reduces cerebral ischemia reperfusion induced injuries in rats. *Bull Emerg Trauma* 2018; 6(2): 115-121.
 31. Zhou G, Myers R, Li Y, et al. Role of AMP-activated protein kinase in mechanism of metformin action. *J Clin Invest* 2001; 108(8): 1167-1174.
 32. Ouchi N, Shibata R, Walsh K. AMP-activated protein kinase signaling stimulates VEGF expression and angiogenesis in skeletal muscle. *Circ Res* 2005; 96(8): 838-846.
 33. Zhang F, Fischer K, Komorowska-Timek E, et al. Improvement of skin paddle survival by application of vascular endothelial growth factor in a rat TRAM flap model. *Ann Plast Surg* 2001; 46(3): 314-319.
 34. Brown LF, Yeo KT, Berse B, et al. Expression of vascular permeability factor (vascular endothelial growth factor) by epidermal keratinocytes during wound healing. *J Exp Med* 1992; 176(5): 1375-1379.
 35. Shiota N, Nishikori Y, Kakizoe E, et al. Pathophysiological role of skin mast cells in wound healing after scald injury: study with mast cell-deficient W/W(V) mice. *Int Arch Allergy Immunol* 2010; 151(1): 80-88.
 36. Michlits W, Mittermayr R, Schäfer R, et al. Fibrin-embedded administration of VEGF plasmid enhances skin flap survival. *Wound Repair Regen* 2007; 15(3): 360-367.
 37. Johnson KE, Wilgus TA. Vascular endothelial growth factor and angiogenesis in the regulation of cutaneous wound repair. *Adv Wound Care (New Rochelle)* 2014; 3(10): 647-661.
 38. Rivilis I, Milkiewicz M, Boyd P, et al. Differential involvement of MMP-2 and VEGF during muscle stretch-versus shear stress-induced angiogenesis. *Am J Physiol Heart Circ Physiol* 2002; 283(4): H1430-H1438.
 39. Heissig B, Rafii S, Akiyama H, et al. Low-dose irradiation promotes tissue revascularization through VEGF release from mast cells and MMP-9-mediated progenitor cell mobilization. *J Exp Med* 2005; 202(6):739-750.
 40. Chehelcheraghi F, Abbaszadeh A, Tavafi M. Skin mast cell promotion in random Skin flaps in rats using bone marrow mesenchymal stem cells and amniotic membrane. *Iran Biomed J* 2018; 22(5): 322-330.
 41. Ochoa-Gonzalez F, Cervantes-Villagrana AR, Fernandez-Ruiz JC, et al. Correction: Metformin induces cell cycle arrest, reduced proliferation, wound healing impairment *in vivo* and is associated to clinical outcomes in diabetic foot ulcer patients. *PLoS One* 2016; 11(7): e0159468. doi:10.1371/journal.pone.0159468.
 42. Li DW, Liu ZQ, Wei J, et al. Contribution of endothelial progenitor cells to neovascularization (Review). *Int J Mol Med* 2012; 30(5): 1000-1006.
 43. Mao L, Huang M, Chen SC, et al. Endogenous endothelial progenitor cells participate in neovascularization via CXCR4/SDF-1 axis and improve outcome after stroke. *CNS Neurosci Ther* 2014; 20(5): 460-468.
 44. Ozturk A, Firat C, Parlakpınar H, et al. Beneficial effects of aminoguanidine on skin flap survival in diabetic rats. *Exp Diabetes Res* 2012; 2012: 721256. doi:10.1155/2012/721256.
 45. Gribbe O, Gustafsson LE, Wiklund NP. Transdermally administered nitric oxide by application of acidified nitrite increases blood flow in rat epigastric island skin flaps. *Eur J Pharmacol* 2008; 578(1):51-56.
 46. Afraz S, Kamran A, Moazzami K, et al. Protective effect of pharmacologic preconditioning with pioglitazone on random-pattern skin flap in rat is mediated by nitric oxide system. *J Surg Res* 2012; 176(2): 696-700.
 47. Gribbe O, Samuelson UE, Wiklund NP. Effects of nitric oxide synthase inhibition on blood flow and survival in experimental skin flaps. *J Plast Reconstr Aesthet Surg* 2007; 60(3): 287-293.