

## Obstructive bacterial cystitis following cystotomy in a Persian cat

Zahra Nikousefat<sup>1</sup>, Mohammad Hashemnia<sup>2\*</sup>, Moosa Javdani<sup>3</sup>, Ali Ghashghai<sup>1</sup>

<sup>1</sup> Department of Clinical Sciences, Faculty of Veterinary Medicine, Razi University, Kermanshah, Iran; <sup>2</sup> Department of Pathobiology, Faculty of Veterinary Medicine, Razi University, Kermanshah, Iran; <sup>3</sup> Department of Veterinary Surgery and Radiology, Faculty of Veterinary Medicine, Shahrekord University, Shahrekord, Iran.

### Article Info

#### Article history:

Received: 03 July 2016  
Accepted: 08 November 2016  
Available online: 15 June 2018

#### Key words:

Bacterial cystitis  
Cat  
Cystotomy  
Urinary tract infection

### Abstract

Feline lower urinary tract diseases are known to be life threatening conditions in cats, especially when they occur as obstructive diseases in males. Early diagnosis and treatment is necessary, otherwise it may lead to death. A 3-year-old male Persian cat was referred to the clinic with a history of anuria, lethargy, loss of appetite and exploratory cystotomy 6 months ago due to urethral obstruction following urolithiasis. Urinary bladder was enlarged and painful on palpation and urine accumulation was observed in ultrasonography. Biochemical and hematological analyses revealed hypocalcemia, hyperphosphatemia and hyperkalemia and increase in blood urea nitrogen, creatinine, white blood cell (WBC), red blood cell (RBC) and hematocrit. Urine analysis showed a turbid appearance, protein 1+, blood 3+, pH reduction, increased WBCs and RBCs and presence of bacteria, calcium oxalate crystals and epithelial cells. Urine culture revealed *Staphylococcus saprophyticus*. Postoperatively, microscopic examinations of the urinary bladder biopsy showed pathological lesions of bacterial cystitis. Based on these findings, bacterial cystitis and urethral obstruction due to post-operative urinary tract infections were diagnosed. For treatment, electrolyte imbalances were corrected firstly, cystotomy was performed and a catheter was conducted into the urethra; then, urethra was flushed and obstruction was resolved. Ampicillin was effective in reducing the bacterial count in urine. Despite the fact that cystotomy is a common procedure in veterinary medicine, clinicians should be aware of its complications such as post-operative urinary tract infections.

© 2018 Urmia University. All rights reserved.

### مقایسه التهاب انسدادی باکتریایی مثانه به دنبال سیستوتومی در یک قلابه گربه نژاد ایرانی

#### چکیده

بیماری های دستگاه ادراری تحتانی گربه، به عنوان شرایط تهدید کننده زندگی در گربه ها به خصوص به هنگام بروز به عنوان یک بیماری انسدادی در حیوانات نر محسوب می شوند. تشخیص زود هنگام و درمان ضروری می باشد که در غیر این صورت ممکن است به مرگ منجر گردد. یک گربه نر سه ساله نژاد ایرانی با سابقه ناتوانی در دفع ادرار، بی حالی، از دست دادن اشتها و سیستوتومی اکتشافی به علت انسداد مجرای ادرار ناشی از سنگ مجرای ادراری شش ماه پیش، به درمانگاه ارجاع شد. در ملامسه، مثانه بزرگ و دردناک بود. در اولتراسونوگرافی، تجمع ادرار مشاهده شد. ارزیابی های بیوشیمیایی و خون شناسی هیپوکالمی، هیپرفسفاتی و هیپرکالمی و افزایش در نیتروژن اوره خون، کراتینین، گلبول سفید، گلبول قرمز و هماتوکریت را آشکار ساخت. ارزیابی ادرار ظاهری کدر، پروتئین +1، خون 3+، کاهش pH، افزایش گلبول های سفید و قرمز و وجود باکتری، بلورهای اگزالات کلسیم و سلول های پوششی را نشان داد. کشت ادرار، رشد باکتری *استافیلوکوکوس ساپروفیتیکوس* را آشکار نمود. بررسی های میکروسکوپی بیوپسی مثانه متعاقب جراحی، ضایعات پاتولوژیک التهاب مثانه باکتریایی را نشان دادند. بر اساس این یافته ها، التهاب مثانه باکتریایی و انسداد پیشابراه به علت عفونت دستگاه ادراری به دنبال عمل جراحی تشخیص داده شد. جهت درمان، نخست عدم توازن های الکترولیتی اصلاح شد، سیستوتومی صورت گرفت و کاتتر به درون مجرای ادراری هدایت شد، سپس مجرای ادرار با فشار مایع شستشو داد شد و انسداد رفع گردید. آمپی سیلین در کاهش تعداد باکتری در ادرار مؤثر بود. با وجود این واقعیت که سیستوتومی یک روش رایج در دامپزشکی است، متخصصان بالینی باید از عوارض آن مانند عفونت های دستگاه ادراری پس از عمل آگاه باشند.

واژه های کلیدی: التهاب باکتریایی مثانه، گربه، سیستوتومی، عفونت مجاری ادراری

#### \*Correspondence:

Mohammad Hashemnia. DVM, PhD  
Department of Pathology, Faculty of Veterinary Medicine, Razi University, Kermanshah, Iran.  
E-mail: [m.hashemnia@razi.ac.ir](mailto:m.hashemnia@razi.ac.ir)



This work is licensed under a Creative Commons Attribution-NonCommercial 4.0 International License which allows users to read, copy, distribute and make derivative works for non-commercial purposes from the material, as long as the author of the original work is cited properly.

## Introduction

Feline lower urinary tract disease (FLUTD) is a common disease in cats which may occur in both genders.<sup>1</sup> The FLUTD is usually present with signs of dysuria, pollakiuria, hematuria, agitation or vocalization during urination, urethral obstruction and/or periuria. History and clinical manifestation of bacterial cystitis are usually similar to FLUTD.<sup>2</sup>

Bacterial cystitis is rare in cats, but perhaps it is more common in those with immune system suppression. While urinary tract infections (UTIs) are uncommon in young cats, the prevalence increases with age increasing. It has been reported from referral institutions that most young cats presenting lower UTI do not have a positive urine culture, while older cats can have a positive culture as much as 15.00-20.00% of the time. Risk factors for UTIs include urolithiasis, immunosuppression, previous indwelling catheterization, perineal urethrostomy, tube cystostomies, diabetes mellitus, neoplasia, hyperadrenocorticism, congenital or acquired anomalies of the lower urinary tract and chronic renal failure. A slight male predisposition has been reported in cats, which likely occurs because male cats can present urethral obstruction and are more likely to be catheterized.<sup>2-4</sup>

In all patients suspected of having UTIs, a urinalysis and bacterial culture provide the most diagnostic information. A quantitative urine culture obtained by cystocentesis is the gold standard for documenting UTIs. Uncomplicated UTIs occur in patients where no underlying structural, neurological or functional abnormalities exist. In most uncomplicated UTIs, a complete blood count and biochemical profile are not warranted, as the results of these tests are usually normal. However, if recurrent bacterial cystitis has been documented or there is the possibility of pyelonephritis or prostatitis, blood work should be evaluated because of significant elevations in the white blood cell (WBC) count. Moreover, blood urea nitrogen (BUN) and creatinine (Cr) can be seen in these latter two conditions. In addition, UTIs are often considered complicated if they occur in cats, male dogs and intact female dogs or if they involve the kidneys or prostate. The distinction between uncomplicated and complicated UTIs is helpful for determining prognosis, risk of recurrence, duration of treatment and follow up recommendations for recheck evaluations.<sup>5,6</sup>

In the present paper, we described a complicated UTI in a Persian cat due to previous cystotomy for urolithiasis treatment.

## Case Description

A 3-year-old male Persian cat was referred to the clinic of Faculty of Veterinary Medicine, Razi University, Kermanshah, Iran, with clinical signs such as anuria,

lethargy and loss of appetite for approximately one week. There was a history of exploratory cystotomy six months ago due to urethral obstruction caused by urolithiasis.

On physical examination, the cat had tachypnea and his bladder was enlarged and painful on palpation. Accumulation of urine was prominent in the ultrasonography of bladder. The biochemical and hematological profiles revealed an increase in BUN, Cr, WBC, red blood cell (RBC) and hematocrit. Additionally, hypocalcemia, hyperphosphatemia and hyperkalemia were observed. In WBCs differential count, neutrophil count was increased. Urine analysis showed a turbid appearance, protein 1+, blood 3+, pH reduction, increased WBCs and RBCs and presence of bacteria, calcium oxalate crystals and epithelial cells. Urine culture showed a positive result for *Staphylococcus saprophyticus* (bacterial growth exceeding  $10^5$  CFU mL<sup>-1</sup>).

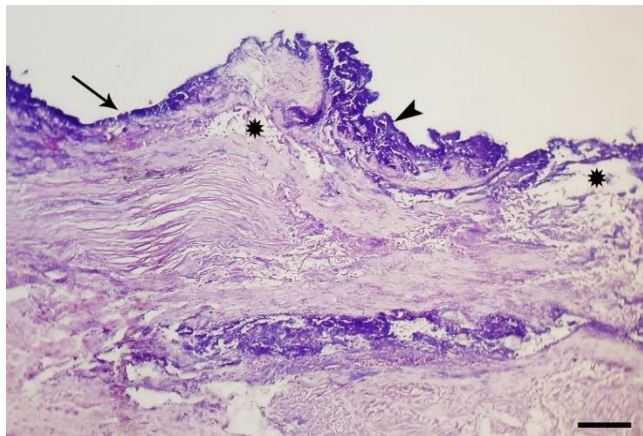
Based on these findings, the possibility of urethral obstruction due to post-operative UTIs or urolithiasis was considered. At the beginning of the treatment process, effort to open the urethra by catheterization was unsuccessful; therefore, decision was made to perform cystotomy.

To correct the underlying fluid deficit, an intravenous (IV) line was established and electrolyte imbalances were corrected before the start of the procedure. Following 5 min pre-oxygenation, the patient was pre-medicated with 0.2 mg kg<sup>-1</sup> midazolam (Darou-Pakhsh, Tehran, Iran) intravenously and anesthesia was induced with IV administration of 5.5 mg kg<sup>-1</sup> ketamine (Alfasan, Woerden, The Netherlands) and 0.2 mg kg<sup>-1</sup> diazepam (Caspian, Rasht, Iran) combination. Maintenance of anesthesia achieved by redoes of the mentioned combination.

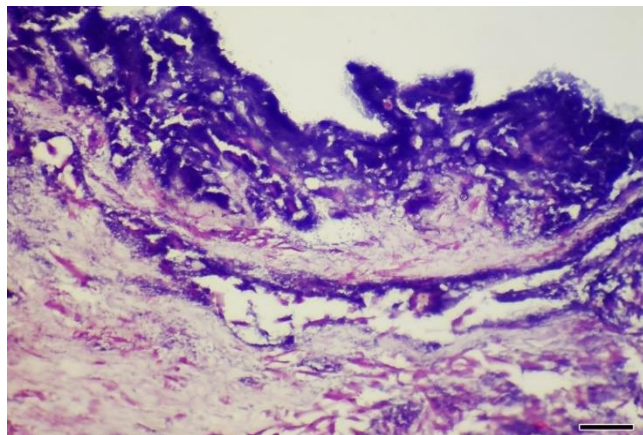
Celiotomy was performed through a caudal midline incision. After entering the abdominal cavity, 210 mL urine was aspirated from the distended bladder. Because of thickening of the ventral bladder wall due to previous cystotomy, a 1.5 cm incision was made on the apex of the bladder. After removing some suspender soft tissue from the bladder, a catheter was introduced into the urethra from the incision site and urethra was flushed with sterile normal saline and obstruction was resolved. Finally, the bladder incision was closed with single-layer inverting patterns and celiotomy incision was sutured routinely.

Microscopic examinations of the urinary bladder biopsy showed some pathological lesions of bacterial cystitis. Denudation of urothelial mucosa, edema with numerous dilated blood vessels in the superficial lamina propria and superficial severe bacterial colonization were the main histopathological findings (Figs. 1 and 2). Urine gram staining showed abundant gram positive cocci and also few polymorphonuclear leukocytes, RBCs and spermatozoa (Fig. 3). Therefore, the primary diagnosis of bacterial cystitis and urethral obstruction due to post-operative UTIs was finally confirmed.

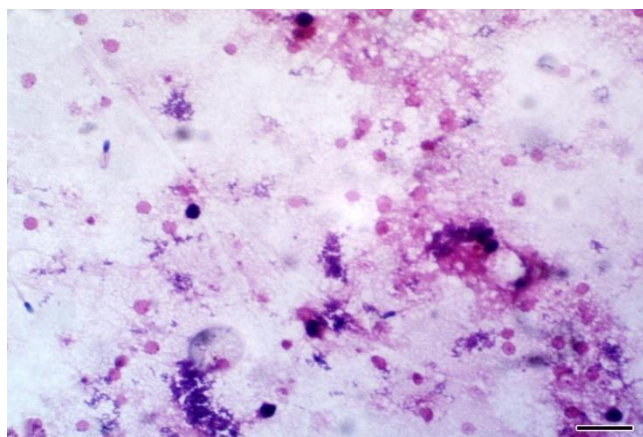
Following surgery, the cat received meloxicam (0.1 mg kg<sup>-1</sup>; Farabi, Tehran, Iran) for 5 days and ampicillin (20.0 mg kg<sup>-1</sup>; Farabi) for 10 days. Also, prednisolone (1.0 mg kg<sup>-1</sup>; Aburaihan Co., Tehran, Iran) and amitriptyline (1.0 mg kg<sup>-1</sup>; Darou-Pakhsh) were administered daily for two and three weeks, respectively.



**Fig. 1.** Denudation of urothelial mucosa (arrow) and presence of bacterial colonies in the mucosa (arrow head) and edematous lamina propria (asterisks) (H&E; Bar = 80 µm).



**Fig. 2.** Superficial severe bacterial colonization (H&E; Bar = 20 µm).



**Fig. 3.** Presence of abundant gram positive cocci and few leukocytes, RBCs and spermatozoa in the urine (Gram staining; Bar = 15 µm).

## Discussion

Feline urethral obstruction is a common presenting complaint to emergency veterinary clinicians. Incidence estimates range from 1.00 to 10.00%. With urethral obstruction, the bladder capacity is reached, resulting in an increase in intra-vesical pressure. Subsequently, the pressure increases in the ureters, renal pelvis and renal tubules with a resultant drop in glomerular filtration rate due to intra-tubular hydrostatic pressure. As functional renal mass decreases, urine concentrating ability is lost. Increased tubular volume of urine and increased tubular pressure result in renal failure and subsequent azotemia, uremia and hyperkalemia.<sup>7,8</sup>

Severe hyperkalemia is the most commonly recognized life-threatening problem in feline urethral obstruction. Eventually, impaired renal clearance of hydrogen ions along with possibly impaired renal production of ammonia results in metabolic acidosis. Cats that have hyperkalemia also have other metabolic abnormalities such as ionized hypocalcemia and acidemia.<sup>9,10</sup> Therefore, the treatment of hyperkalemia should take these changes into account. Based on these criteria, correction of the fluid deficit and electrolyte changes should be the first therapeutic step.

Bacterial UTIs in cats are relatively rare but much higher prevalence rates (15.00 to 43.00%) are observed in cats that have their urinary tract defense mechanisms compromised by the effects of other diseases and/or by the treatment. The UTIs are of particular importance because they are associated with urethral obstruction. Major predisposing factors of feline UTIs are senescence, perineal urethrostomy, low urine specific gravity and previous catheterization history.<sup>11</sup>

Urine analyses were shown to be useful indicators for UTIs. The most commonly isolated bacteria from cats with UTIs were reported to be *Escherichia coli*, *Enterococcus* spp., *Staphylococcus* spp. and *Streptococcus* spp.<sup>12-15</sup>

The key to successful treatment of UTIs is a correct diagnosis. Where a specific cause can be identified, then, its treatment can be undertaken.<sup>16</sup> In the present case, cytology and histopathology were useful methods for UTI diagnosis.

Although urine is easily accessible for cytological examinations, its use in the differentiation of the different types of cystitis is limited. The main utility of urine cytology is to rule out malignancy; it can also be very useful in guiding the clinicians to correct the diagnosis of certain infectious processes. Tissue sampling in the acute phase of infectious cystitis is contraindicated; however, chronic and recurrent cases may need histological evaluations to rule out underlying malignancy. The main histopathological findings are edema and nonspecific acute or chronic inflammatory cells infiltration in the lamina propria. Various degrees of reactive atypia may be also present in the overlying epithelium.<sup>17</sup>

In the present case, previous cystotomy was recognized as a main cause of bacterial cystitis. Cystotomy is a common surgical procedure in small animal veterinary practice, typically performed to remove cystic calculi. Complications that can develop include uroabdomen, UTI, surgical site infection, incomplete removal of uroliths, recurrence of cystic calculi and lower urinary tract obstruction. The type of suture used, the location of the bladder incision and a quadratic of the annual number of feline cystotomies were significantly associated with post-operative UTI. The use of absorbable multifilament suture and dorsal cystotomy incisions may produce fewer recurrent UTIs than absorbable monofilament suture and ventral incisions.<sup>18,19</sup>

Urethral obstruction in tomcat occurs mainly in the narrow distal portion of the urethra. Irrespective of cause, initial treatment must focus on the restoration of urethral patency and urine flow. Non-surgical techniques including penile massage and retrograde urethral flushing can be very effective in dislodging intraluminal plugs and uroliths.<sup>20-22</sup>

In the cases of bacterial cystitis, treatment is usually difficult and time-consuming process. Appropriate antibiotic treatment leads to significantly higher symptomatic and bacteriological cure rates and better prevention of reinfection in animals with bacterial cystitis.

The first-choice agents for treatment of acute cystitis in human include nitrofurantoin monohydrate/macrocrystals, trimethoprim-sulfamethoxazole or fosfomycin.  $\beta$ -lactam antibiotics may be used when other recommended agents cannot be used.<sup>23,24</sup> In the present case, administration of ampicillin decreased quantitative bacterial counts in the urine and culture positive urine on days 5 and 10, respectively.

In conclusion, various treatment options for urethral obstructions are now available for veterinary patients. Despite the fact that cystotomy is a common procedure in veterinary medicine, clinicians should be aware of its complications such as post-operative UTIs.

### Acknowledgments

We thank the authorities of Veterinary Faculty, Razi University, Kermanshah, Iran for their cooperation.

### Conflict of Interest

The authors declare that there is no conflict of interest regarding the publication of this paper.

### References

1. Srivastava AK, Syed B. Management of urinary tract infection in cats. *Indian J Canine Pract* 2012; 4: 94-95.
2. Malouin A. Urologic Emergencies. In: Drobatz KJ, Costello MF (Eds). *Feline emergency and critical care medicine*. 1<sup>st</sup> ed. Ames, USA: Wiley-Blackwell, 2010: 282-283.
3. Buffington CA, Chew DJ, Kendall MS, et al. Clinical evaluation of cats with nonobstructive urinary tract diseases. *J Am Vet Med Assoc* 1997; 210(1): 46-50.
4. Bailiff NL, Westropp JL, Nelson RW, et al. Evaluation of urine specific gravity and urine sediment as risk factors for urinary tract infections in cats. *J Am Vet Med Assoc* 2008; 37(3): 317-322.
5. Bailiff NL, Nelson RW, Feldman EC, et al. Frequency and risk factors for urinary tract infection in cats with diabetes mellitus. *J Vet Intern Med* 2006; 20: 850-855.
6. Mayer-Roenne B, Goldstein RE, Erb HN. Urinary tract infections in cats with hyperthyroidism, diabetes mellitus and chronic kidney disease. *J Feline Med Surg* 2007; 9: 124-132.
7. Polzin DJ, Osborne CA, Bartges JW. Management of postrenal azotemia. *Vet Clin North Am: Small Anim Pract* 1996; 26(3): 507-513.
8. Bartges JW, Finco DR, Polzin DJ. Pathophysiology of urethral obstruction. *Vet Clin North Am: Small Anim Pract* 1996; 26(2): 255-264.
9. Lee JA, Drobatz KJ. Characterization of the clinical characteristics, electrolytes, acid-base, and renal parameters in male cats with urethral obstruction. *J Ve Emerg and Crit Care* 2003; 13(4): 227-233.
10. Drobatz KJ, Hughes D. Concentration of ionized calcium in plasma from cats with urethral obstruction. *J Am Vet Med Assoc* 1997; 211(11): 1392-1395.
11. Lekcharoensuk C, Osborne CA, Lulich JP. Epidemiologic study of risk factors for lower urinary tract diseases in cats. *J Am Vet Med Assoc* 2001; 218: 1429-1435.
12. Litster A, Moss SM, Honnery M, et al. Prevalence of lower urinary tract disease in cats with clinical signs of lower urinary tract disease: Recognition of *Staphylococcus felis* as a possible feline urinary tract pathogen. *Vet Microbiol* 2007; 121: 182-188.
13. Litster A, Thompson M, Moss S, et al. Feline bacterial urinary tract infections: An update on an evolving clinical problem. *Vet J* 2011; 187: 18-22.
14. Eggertsdóttir AV, Lund HS, Krøntveit R, et al. Bacteriuria in cats with feline lower urinary tract disease: a clinical study of 134 cases in Norway. *J Feline Med Surg* 2007; 9: 458-465.
15. Dokuzeylül B, Kahraman BB, Bayrakal A, et al. Bacterial species isolated from cats with lower urinary tract infection and their susceptibilities to cefovecin. *Irish Vet J* 2015; 68: 2.
16. Gunn-Moore DA. Feline lower urinary tract disease. *J Feline Med Surg* 2003; 5: 133-138.
17. Neuhaus J, Schwalenberg T, Horn LC, et al. New aspects in the differential diagnosis and therapy of bladder pain syndrome/interstitial cystitis. *Adv Urol* 2011; 2011:639479. doi: 10.1155/2011/639479.

18. Appel S, Otto SJ, Weese JS. Cystotomy practices and complications among general small animal practitioners in Ontario, Canada. *Can Vet J* 2012; 53(3): 303-310.
19. Berent AC. Ureteral obstructions in dogs and cats: A review of traditional and new interventional diagnostic and therapeutic options. *J Vet Emerg Crit Care* 2011; 21(2): 86-103.
20. Goh CSS, Seim HB. Feline perineal urethrostomy ventral approach. *Today's Vet Pract* 2014, 4: 43-49.
21. Ruda L, Heiene R. Short- and long-term outcome after perineal urethrostomy in 86 cats with feline lower urinary tract disease. *J Small Anim Pract* 2012; 53: 693-698.
22. Bass M, Howard J, Gerber B, et al. Retrospective study of indications for and outcome of perineal urethrostomy in cats. *J Small Anim Pract* 2005; 46: 227-231.
23. Gupta K, Hooton TM, Naber KG, et al. International clinical practice guidelines for the treatment of acute uncomplicated cystitis and pyelonephritis in women: A 2010 update by the Infectious Diseases Society of America and the European Society for Microbiology and Infectious Diseases. *Clin Infect Dis* 2011; 52(5): e103-120.
24. Wagenlehner FM, Schmiemann G, Hoyme U, et al. National S3 guideline on uncomplicated urinary tract infection: Recommendations for treatment and management of uncomplicated community-acquired bacterial urinary tract infections in adult patients. *Urologe A* 2011; 50(2): 153-169.