

## Hemolytic anemia associated with *Trypanosoma theileri* in a cow from Kurdistan province, West of Iran

Attaollah Hajihassani<sup>1</sup>, Shilan Maroufi<sup>2</sup>, Bijan Esmaeilnejad<sup>3\*</sup>, Hajir Khorram<sup>2</sup>, Mousa Tavassoli<sup>3</sup>, Bahram Dalir-Naghadeh<sup>4</sup>, Awat Samiei<sup>3</sup>

<sup>1</sup>Dean of Primer Diagnostic Laboratory, Baneh, Iran; <sup>2</sup>Private Veterinary Practitioner, Baneh, Iran; <sup>3</sup>Department of Pathobiology, Faculty of Veterinary Medicine, Urmia University, Urmia, Iran; <sup>4</sup>Department of Internal Medicine and Clinical Pathology, Faculty of Veterinary Medicine, Urmia University, Urmia, Iran.

### Article Info

#### Article history:

Received: 12 February 2019  
Accepted: 13 July 2019  
Available online: 15 June 2020

#### Keywords:

Anemia  
Cow  
Iran  
*Trypanosoma theileri*

### Abstract

Various species of *Trypanosoma* parasites are known to infect several wild and domestic animals worldwide. A 7-year-old Holstein cow from Baneh, Kurdistan province, was examined by a private veterinarian due to anorexia and depression. Physical examination revealed fever, enlarged subscapular lymph node, and pale mucosa. Blood samples were taken for hematological, parasitological, and PCR examination. The large *Trypanosoma* spp. was microscopically observed in a stained blood smear. Decreased red blood cells (RBCs) count, packed cell volume and hemoglobin concentration were observed through complete blood cell count. Nucleated RBCs were also found in this case. Species-specific PCR assay confirmed *T. theileri* infection. Treatment was performed subcutaneously with diminazene aceturate. The clinical signs were improved after two days. Two-month follow-up showed no recurrence. In conclusion, *T. theileri* is characterized by anemia and pyrexia in a cow. To our knowledge, the present case report describes the first molecular evidence of *T. theileri* in Kurdistan, West of Iran.

© 2020 Urmia University. All rights reserved.

### Introduction

*Trypanosoma theileri* is assigned to the subgenus *Megatrypanum* by a classification originally based on its morphology. This species is one of the largest mammalian blood trypanosomes. The large trypomastigote form *T. theileri* can be revealed in peripheral blood having a long pointed posterior end with kinetoplast typically situated near the nucleus.<sup>1,2</sup> The main form of transmission is probably through blood-sucking arthropods such as *Tabanus*.<sup>3</sup> Although *T. theileri* is mostly associated with mild or no pathogenicity, evidence of regenerative anemia, fever, and progressive weight loss has been revealed in sporadic clinical cases in domestic animals of several countries such as Spain, Ireland, Germany, and Italy.<sup>4-10</sup> The present case report describes a cow infected with *T. theileri* in Kurdistan, West of Iran.

### Case Description

A 7-year-old Holstein cow from Baneh county (35° 59' 51" N 45° 53' 07" E), located at about 249 km north of

Sanandaj (Kurdistan province) in the West of Iran, was examined by a private veterinarian due to fever, anorexia, and depression. Enlarged subscapular lymph nodes, strong heart sounds, and pale mucosa were also recorded. The blood samples from the jugular vein were collected in EDTA-containing blood collection tubes (Kendall Co., Mansfield, USA) for hematological and molecular examinations. First, Giemsa-stained blood smears were prepared for precise detection of the parasite under a light microscope (Olympus SZ61; Olympus Corporation, Tokyo, Japan) using morphological features and taxonomical key of Kaufmann.<sup>11</sup> Then, a part of the blood sample was assigned to routine hematological parameters including red blood cell (RBC) count, packed cell volume (PCV) value, and hemoglobin concentration by automated hematology analyzer (Exigo, Stockholm, Sweden).

The DNA from the blood sample was extracted using a DNA extraction kit (MBST, Tehran, Iran). A pair of primers, forward 5' -CGTCTCTGGCTCCGGTCAAAC-3' and reverse 5'-TTAAAGCTTCCACGAGTTCTTGATGATCCAGTA-3' was used to amplify a 289 bp fragment of cathepsin L-like protein (CATL) gene from *T. theileri* according to the

#### \*Correspondence:

Bijan Esmaeilnejad. DVM, PhD  
Department of Pathobiology, Faculty of Veterinary Medicine, Urmia University, Urmia, Iran  
E-mail: b.esmaeilnejad@urmia.ac.ir

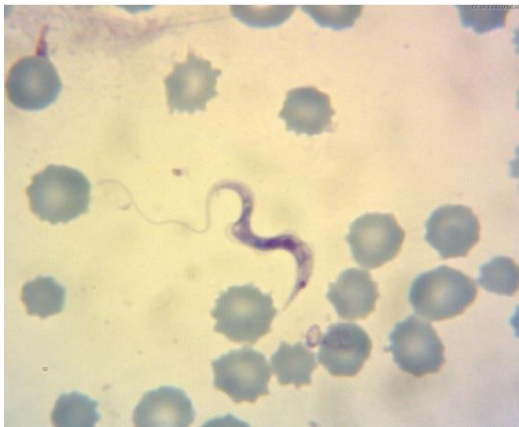

This work is licensed under a Creative Commons Attribution-NonCommercial 4.0 International License which allows users to read, copy, distribute and make derivative works for non-commercial purposes from the material, as long as the author of the original work is cited properly.

method described by Yokoyama *et al.*<sup>12</sup> Polymerase chain reaction (PCR) was carried out in 50.00  $\mu$ L total reaction volume containing 5.00  $\mu$ L of 10x PCR buffer, 2.00 mM MgCl<sub>2</sub> (Cinnagen, Tehran, Iran), 250  $\mu$ M of each of the four deoxynucleotide triphosphates, 1.25 U Taq DNA polymerase (Fermentas Life Science, St. Leon-Rot, Germany), 50.00 pmol of each primer and 50.00 ng of extracted DNA. Amplification of parasite DNA was done in a thermocycler (CP2-003; Corbett Research, Sydney, Australia). Cycling condition for *T. theileri* was 95.00 °C for 5 min, followed by 45 cycles at 95.00 °C for 30 sec, 55.00 °C for 60 sec and 72.00 °C for 1 min with a final extension step of 72.00 °C for 10 min. The PCR products extracted from the agarose gel were sent for sequencing (SinaClon, Tehran, Iran). The *T. theileri* positive control was confirmed by GenBank under the accession number of MK393794. The negative control contained all essential components of the amplification reaction except the template. The study was approved by the Ethics Committee of Faculty of Veterinary Medicine, Urmia University, Urmia, Iran (AECVU-190-2019).

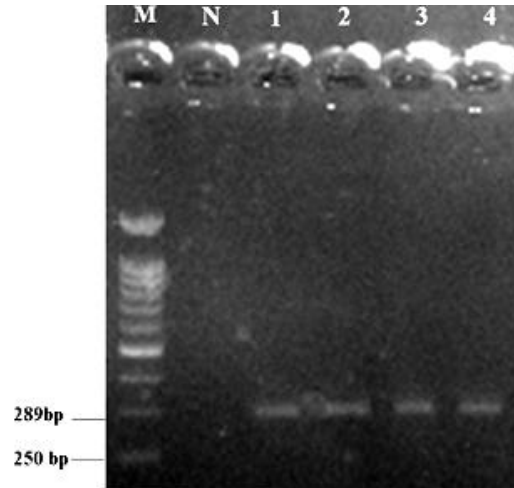
## Results

Light microscopic examination of Giemsa-stained peripheral blood films revealed the presence of *Trypanosoma* spp. trypomastigotes (85.00  $\pm$  5.00  $\mu$ m in length) freely scattered between erythrocytes having kinetoplast typically situated near the nucleus (Fig. 1). The PCR analysis showed an expected 289 bp fragment of the CATL gene of *T. theileri* amplified from a blood sample (Fig. 2). Negative control reactions of each PCR run did not yield amplification products. The PCR product was purified, sequenced, and registered under the accession number of MK393794 in GenBank. The sequences of the CATL gene of *T. theileri* obtained in the present study were compared with other CATL sequences retrieved from GenBank. Sequence analysis demonstrated the highest homology of 98.00-100% between obtained sequences and registered sequence of *T. theileri* in GenBank.



**Fig. 1.** Giemsa-stained blood smear showing large trypomastigote of *Trypanosoma* spp (100x)

Hematological examinations indicated low PCV (18.00%; reference interval: 24.00 - 46.00%), RBC count ( $3.55 \times 10^6 \mu\text{L}^{-1}$ ; reference interval:  $5.00-10.00 \times 10^6 \mu\text{L}^{-1}$ ) and hemoglobin (6.10 g dL<sup>-1</sup>; reference interval: 8.00 - 15.00 g dL<sup>-1</sup>).<sup>13</sup> In addition, nucleated RBCs (four per 100 white blood cells) were found in this case.



**Fig. 2.** Agarose gel electrophoresis of *T. theileri* cathepsin L-like protein gene products by PCR. Lane M: 100 bp DNA molecular marker; Lane N: Negative control; Lanes 2 to 4: PCR product of *T. theileri* samples.

## Discussion

Microscopic examinations such as Giemsa-stained blood smears and cultivation of blood samples are mostly used as a confirmatory diagnosis of vertebrate host suffering from *Trypanosoma* infections. Based on microscopic examinations, there are two reports of *T. theileri* infection in cattle of Iran.<sup>14,15</sup> However, this study was focused on molecular confirmation of *T. theileri*, which is the lesser-studied species. The PCR has been proven to be more sensitive than a blood examination regarding trypanosome genomic DNA detection in the animal or vector host. Also, this method is sensitive enough to detect even one trypanosome genomic DNA per mL of blood. Also, DNA-based diagnostic methods have generally facilitated epidemiological studies of trypanosomes.<sup>12</sup>

Prevalence of *T. theileri* varies considerably in different countries ranging from 10.00 to 90.00%.<sup>7</sup> In the previous study in Iran, a culture of blood was used and the prevalence of *T. theileri* was determined as 26.47%.<sup>14</sup> Infection of a cow by *T. theileri* has been reported previously in cattle of Urmia, Iran using the cytologic examination.<sup>15</sup> However, to the best of the authors' knowledge, the present report is the first molecular-confirmed case of *T. theileri* infection in cattle of Iran.

*Trypanosoma theileri* is commonly associated with mild or no clinical signs and it is thought to have very low pathogenicity.<sup>8</sup> In this case report, pyrexia, enlarged lymph

nodes, and decreased RBCs, PCV, and hemoglobin concentration are in agreement with clinical and hematological findings reported in other studies.<sup>5,9,15</sup> Enlargement of the lymph node in infected cow could be due to extravascular localization of trypomastigotes in the lymph node.<sup>16</sup>

In summation, the findings recorded here demonstrated that *T. theileri* should be considered in the differential diagnosis of diseases characterized by anemia and pyrexia. The PCR evaluation for *T. theileri* DNA should be included in the investigation of such cases to enable the rapid definitive detection of this infection, which may be more common than the previous estimation. Besides, diminazene aceturate might be effective in the treatment of *T. theileri* in cattle, however; conducting further case studies are necessary to recommend successful treatment. Our findings also indicate that *T. theileri* should be considered as an occasional pathogen of cattle in Iran.

### Acknowledgments

The authors would like to thank the Research Dean of Urmia University, Urmia, Iran for the financial support of this study.

### Conflict of interest

The authors declare no conflict of interest.

### References

1. Votýpka J, d'Avila-Levy CM, Grellier P, et al. New approaches to systematics of Trypanosomatidae: Criteria for taxonomic (re) description. *Trends Parasitol* 2015; 31(10): 460-469.
2. Reichenow E. East African observations on trypanosomids. *Arch Protistenk* 1940; 94: 267-287.
3. Böse R, Heister NC. Development of *Trypanosoma (M.) theileri* in tabanids. *J Eukaryot Microbiol* 1993; 40(6): 788-792.
4. Sood NK, Singla LD, Singh RS, et al. Association of *Trypanosoma theileri* with peritonitis in a pregnant cross-bred cow: A case report. *Vet Med* 2011; 56(2): 82-84.
5. Villa A, Gutierrez C, Gracia E, et al. Presence of *Trypanosoma theileri* in Spanish cattle. *Ann N Y Acad Sci* 2008; 1149: 352-354.
6. Fölsch DW. Simplified, contamination-free, cultural demonstration of *Trypanosoma theileri* (Laveran, 1902) in cattle blood in North Germany. Isolation and culture. *Acta Trop* 1971; 28(2): 170-174.
7. Polidori GA, Grelloni V, Moretti A, et al. *Trypanosoma theileri* infection in cattle in central Italy. *Atti Soc Ital Sci Vet* 1982; 36: 650-652.
8. Greco A, Loria GR, Dara S, et al. First isolation of *Trypanosoma theileri* in Sicilian cattle. *Vet Res Commun* 2000; 24(7): 471-475.
9. Doherty ML, Windle H, Voorheis HP, et al. Clinical disease associated with *Trypanosoma theileri* infection in a calf in Ireland. *Vet Rec* 1993; 132(26): 653-656.
10. Desquesnes M, McLaughlin G, Zoungrana A, et al. Detection and identification of *Trypanosoma* of African livestock through a single PCR based on internal transcribed spacer 1 of rDNA. *Int J Parasitol* 2001; 31(5-6): 610-614.
11. Kaufmann J. Parasitic infections of domestic animals: A diagnostic manual. 1<sup>st</sup> ed. Berlin, Germany: Birkhäuser 1996; 61-62.
12. Yokoyama N, Sivakumar T, Fukushi S, et al. Genetic diversity in *Trypanosoma theileri* from Sri Lankan cattle and water buffaloes. *Vet Parasitol* 2015; 207(3-4): 335-341.
13. Blood DC. Pocket companion to veterinary medicine. 8<sup>th</sup> ed. London, UK: WB Saunders 1997; 484.
14. Niak A. The incidence of *Trypanosoma theileri* among cattle in Iran. *Trop Anim Health Prod* 1978; 10(1): 26-27.
15. Seifi HA. Clinical trypanosomosis due to *Trypanosoma theileri* in a cow in Iran. *Trop Anim Health Prod* 1995; 27(2): 93-94.
16. Luckins AG, Gray AR. Trypanosomes in the lymph nodes of cattle and sheep infected with *Trypanosoma congolaise*. *Res Vet Sci* 1979; 27(1): 129-131.