

Immunohistochemical investigation of parainfluenza 3 virus in sheep pneumonia

Gizem Eser*, Yavuz Selim Sağlam, Serkan Yıldırım

Department of Veterinary Pathology, Faculty of Veterinary Medicine, Ataturk University, Erzurum, Türkiye.

Article Info

Article history:

Received: 13 April 2022
Accepted: 01 August 2022
Available online: 15 August 2023

Keywords:

Histopathology
Immunohistochemistry
Parainfluenza 3
Pneumonia
Sheep

Abstract

The aim of this study was to determine the prevalence of parainfluenza 3 (PI3) virus antigen through histopathological and immunohistochemical (IHC) methods in sheep lung samples collected from Erzurum province, Türkiye. Between August and November 2017, 1462 sheep were dissected in the slaughterhouse and their lungs were examined macroscopically. In total, 100 of the lung samples with pneumonia were selected. Routine histopathological and IHC analyses of the collected lung tissues with pneumonia were performed. Pneumonia observed through macroscopical and histopathological examinations of the lung samples was classified as purulent-catarrhal bronchopneumonia (14.00%), fibrinous bronchopneumonia (23.00%), interstitial pneumonia (69.00%), granulomatous pneumonia (7.00%), verminous pneumonia (19.00%) and pulmonary adenomatosis (6.00%). Two or three types of pneumonia were observed in many of the same cases. The PI3 virus antigen positivity rate in the IHC analysis of sheep lung samples was 19.00%. In the IHC tracing, positivities were found mostly in the alveolar macrophages and cytoplasm of bronchial, bronchiolar and alveolar epithelial cells. As a result, the prevalence of PI3 virus in sheep in Erzurum province, Türkiye, was determined to be 19.00% using KLN BVB IHC method.

© 2023 Urmia University. All rights reserved.

Introduction

Sheep pneumonia causes significant economic losses due to the degradation of conditions, low yields and secondary infections as well as deaths in animal breeding in Türkiye and throughout the world.^{1,2} In the occurrence of pneumonia, predisposing factors such as maintenance feeding errors, crowded housing, inappropriate ventilation, sudden climate change, hunger, secondary diseases, transport and stress along with disease-causing factors such as viruses, bacteria, chlamydia, fungi and parasites play a role.^{3,4}

The parainfluenza 3 (PI3) virus, which is among the viral agents of sheep pneumonia, is an important problem in terms of pneumonia agents in Türkiye ; but, it is also common throughout the world.^{2,5} The PI3 virus is found in the genus paramyxovirus in the paramyxoviridae family.^{6,7} The virus is spread by tears, nasal secretions and saliva from infected animals as well as through transporting active animals, infected feed and barn materials.⁸ The main symptoms are high fever, nasal and eye discharges, increased respiratory rate and pain in the thoracic region.⁹

Diarrhea and significant weight loss have also been observed in some animals. It should be noted that, although PI3 virus infections being uncomplicated by secondary agents have no clinical symptoms, PI3 virus infections together with other viral and secondary bacterial infections can cause severe pneumonia and death.¹⁰

In the literature, no studies have been found regarding PI3 virus in sheep in Erzurum province, Türkiye, where the animal breeding is intense. In this study, sheep lung tissue samples taken in order to determine the presence and prevalence of PI3 virus antigen in sheep in Erzurum province, Türkiye, were examined using histopathological and immunohistochemical (IHC) methods.

Materials and Methods

The material of the study consisted of 100 lung specimens with pneumonia lesions. The sheep lung samples were placed in 10.00% formalin solution for histopathological examination and embedded in paraffin blocks in accordance with routine tissue follow-up procedures. Sections of 4.00 µm thickness from each block

*Correspondence:

Gizem Eser. PhD
Department of Veterinary Pathology, Faculty of Veterinary Medicine, Ataturk University, Erzurum, Türkiye
E-mail: gizem.eser@igdir.edu.tr



This work is licensed under a Creative Commons Attribution-NonCommercial-ShareAlike 4.0 International (CC BY-NC-SA 4.0) which allows users to read, copy, distribute and make derivative works for non-commercial purposes from the material, as long as the author of the original work is cited properly.

were prepared and placed onto normal and adhesive slides. The preparations were stained with Hematoxylin and Eosin (H & E) and IHC methods and examined under a light microscope (Olympus, Tokyo, Japan).¹¹

Results

Pneumonia was detected in 100 (6.83%) of the 1462 sheep lung specimens being examined macroscopically.

Macroscopically, the pneumonia lesions observed in the 100 lung specimens were evaluated and grouped as lobar (n = 12), lobular (n = 47), lobar + lobular (n = 4) and interstitial (n = 37) pneumonia according to their structure, location and characteristics. According to the localization and morphology of the lesions, bronchopneumonia (bronchopneumonia with fibrin, bronchopneumonia with purulent-catarrrhal discharge and aspiration pneumonia) was classified as interstitial, granulomatous and verminous pneumonias and tumoral diseases (pulmonary adenomatosis). Of the sheep lungs examined, 23 (23.00%) had fibrin bronchopneumonia, 14 (14.00%) purulent-catarrrhal bronchopneumonia, 69 (69.00%) interstitial pneumonia, seven (7.00%) granulomatous pneumonia and 19 (19.00%) verminous pneumonia and pulmonary adenomatosis was found in six (6.00%). From the lungs with pneumonia, 12 cases of fibrinous bronchopneumonia and interstitial pneumonia, four cases of catarrrhal bronchopneumonia and interstitial pneumonia, two cases of fibrinous bronchopneumonia and granulomatous pneumonia, three cases of catarrrhal bronchopneumonia and interstitial pneumonia, one case of interstitial pneumonia and catarrrhal bronchopneumonia and verminous pneumonia, 17 cases of verminous pneumonia and interstitial pneumonia and two cases of granulomatous pneumonia and interstitial pneumonia were seen.

In the macroscopical examination of interstitial pneumonia cases, the lungs were not collapsed and they were light-colored, bulging, spongy and elastic in consistency having emphysema (Fig. 1A). In the microscopical examination of interstitial pneumonia cases, intense mononuclear cell infiltrations in the inter-alveolar septum, thickening due to an increase in connective tissue and sometimes the emphysematous areas were observed. In some cases, the development of peribronchial, peribronchiolar and perivascular lymphoid cell hyperplasia was quite prominent (Fig. 1B).

Lung samples were stained by IHC method and positivity for the PI3 virus was detected in 19 (19.00%) of the 100 lung samples. It was noted that there was a high positivity rate in the lung samples of animals with interstitial pneumonia. Of the lung samples examined for PI3 virus antigen, intra-cytoplasmic positivity was found in type II alveolar epithelium (Fig. 2A), macrophage cell (Fig. 2B), bronchiolar epithelial cell (Fig. 2C) and bronchial gland epithelial cell (Fig. 2D).

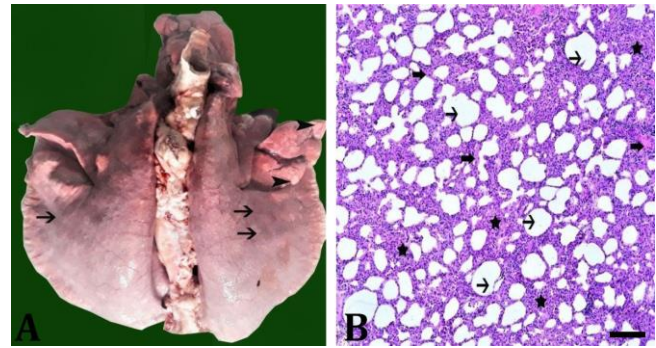


Fig. 1. Interstitial pneumonia. **A)** Over the spongy and elastic lung, rib marks (arrows) and areas with emphysema (arrowheads) are obvious; **B)** Moderate thickening of the inter-alveolar septum in the lung (asterisks) and alveolar emphysema (formation and presence; arrows) can be seen. (H & E, bar = 100 μ m).

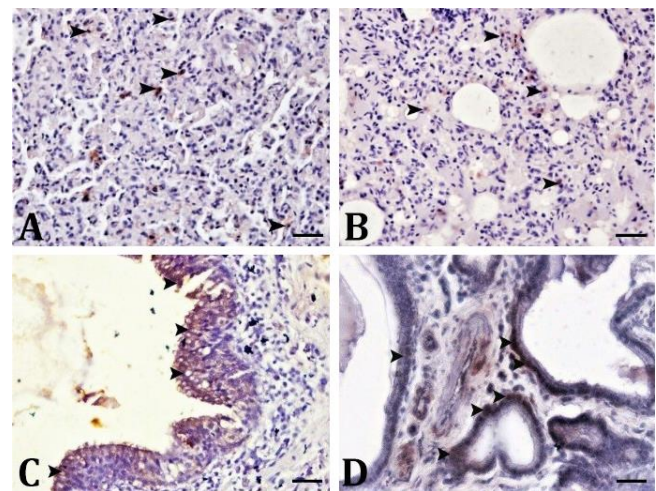


Fig. 2. Parainfluenza 3 virus antigen immunohistochemical (IHC) tracing. **A)** Intra-cytoplasmic positivity of type II alveolar epithelium (arrowheads); **B)** Intra-cytoplasmic positivity of macrophage cells (arrowheads); **C)** Intra-cytoplasmic positivity of bronchiolar epithelial cells (arrowheads); **D)** Intra-cytoplasmic positivity of bronchial gland epithelial cells (arrowheads), (IHC staining, bars = 20.00 μ m).

Discussion

In the previous studies carried out in sheep and lamb, pneumonia rates varied from region to region at the rates of 50.30 - 66.40%,² 18.26 %, ⁴ 3.90%,¹² and 4.40%.¹³ In this study, pneumonia was detected in 100 (6.83%) of the lungs of 1462 sheep slaughtered in the facilities of Erzurum, Türkiye. This rate is within the range of pneumonia reported in former studies; but, not those with very high rates.

Interstitial pneumonia was reported at the rates of 69.50% and 77.40% in sheep lung samples^{1,14} and 21.13% and 58.50% in lamb lungs.^{3,15} Also, Çomaklı *et al.*,¹⁶ reported IHC, immunofluorescence (IF) and enzyme-linked immunosorbent assay antigen positivity as 48.33%,

50.83% and 29.90%, respectively. In the present study, interstitial pneumonia was the most common type of pneumonia in sheep, with a rate of 69.50%. As in the most of previous studies,^{1,3,14} the presence of interstitial pneumonia was found to be higher than other types of pneumonia. Although similar macroscopical and microscopical findings to other studies were observed in this study, syncytial giant cell formation was not seen.¹⁴⁻¹⁶

Although PI3 virus, which is common all over the world,^{2,5,6} is seen at different rates in Türkiye, it is one of the most isolated viruses from respiratory tract infections.^{1,3,16,17} The presence and diagnosis of PI3 virus are possible through direct and indirect diagnostic methods.¹⁸ The PI3 virus infection has been frequently observed in studies and serological methods are used for its diagnosis. Polymerase chain reaction, immunohistochemistry and IF techniques, which are more sensitive diagnostic methods, should be used for the definitive diagnosis of infection. However, serological tests are easily performed in the laboratory and preferred because of their low cost.^{19,20} In this study, the presence of PI3 virus in sheep pneumonia was determined by immunohistochemistry and the histopathological findings of positive lung samples were reported. The presence of PI3 virus was found to be 19.00% being particularly high in pneumonia cases. The results of present study indicate that PI3 virus infection plays a very important role in the etiology of sheep pneumonia in Erzurum province, Türkiye. For this reason, it is recommended that preventive measures should be taken, especially in the Erzurum region in Türkiye and the fight against the disease should be advanced by informing private and public veterinarians. In addition, the data of this study will provide new information for the literature and serve as a reference for future scientific studies.

Acknowledgments

We would like to thank Atatürk University Scientific Research Project Coordination Unit, Erzurum, Türkiye (Project No. ID.6571; Code: TYL-2018-6571) for supporting this study. This study was prepared from a master thesis (Number: 533826).

Conflict of interest

There is no conflict of interest between the authors.

References

- Topçuoğlu H, Yoldaş A, Tekin MA. Pathological investigation of pneumonia in small ruminants in Adana region [Turkish]. *AVKAE Dergisi*, 2014; 4: 19-24.
- Mao L, Yang L, Li W, et al. Epidemiological investigation and phylogenetic analysis of caprine parainfluenza virus type 3 in sheep of China. *Transbound Emerg Dis* 2019; 66(3): 1411-1416.
- Yüzbaşıgil AF. Pathological and bacteriological investigations and the role of parainfluenza 3 (PI-3) virus in etiology in lamb pneumonia [Turkish]. Doctoral Thesis, Selcuk University, Institute of Health Sciences. Konya, Türkiye: 2010.
- Mekibib B, Mikir T, Fekadu A, et al. Prevalence of pneumonia in sheep and goats slaughtered at Elfora Bishoftu export abattoir, Ethiopia: A pathological investigation. *J Vet Med* 2019; 2019: 5169040. doi: 10.1155/2019/5169040.
- Moroz A, Czopowicz M, Mickiewicz M, et al. Antibodies to parainfluenza virus type 3 in goat population in Poland. *Pol J Vet Sci* 2021; 24(2): 235-241.
- Li W, Li J, Sun M, et al. Viperin protein inhibits the replication of caprine parainfluenza virus type 3 (CPIV 3) by interaction with viral N protein. *Antiviral Res* 2020; 184: 104903. doi: 10.1016/j.antiviral.2020.104903.
- Amarasinghe GK, Ayllón MA, Bào Y, et al. Taxonomy of the order Mononegavirales: update 2019. *Arch Virol* 2019; 164(7): 1967-1980.
- Li W, Hao F, Mao L, et al. Pathogenicity and horizontal transmission studies of caprine parainfluenza virus type 3 JS2013 strain in goats. *Virus Res* 2016; 223: 80-87.
- Contreras-Luna MJ, Ramírez-Martínez LA, Silva RES, et al. Evidence of respiratory syncytial virus and parainfluenza-3 virus in Mexican sheep. *Virusdisease* 2017; 28(1): 102-110.
- Gençay A, Akça Y. Investigation of parainfluenza-3 (PI-3) virus infection with immunofluorescence and microneutralization tests in sheep [Turkish]. *Erciyes Üniv Vet Fak Derg* 2004;1(2): 91-96.
- Suvarna SK, Layton C, Bancroft JD. *Bancroft's theory and practice of histological techniques*. 8th ed. Amsterdam, The Netherlands: Elsevier health sciences 2018; 126-139.
- Usta M. Pathological and bacteriological investigation of sheep pneumonia [Turkish]. Master's Thesis. Balıkesir University, Institute of Health Sciences, Balıkesir, Türkiye: 2000.
- Gökçe E, Erdoğan HM. Pneumonia in neonatal lambs: frequency and some associated risk factors [Turkish]. *Kafkas Üniv Vet Fak Derg* 2008; 14(2): 223-228.
- Özkaraca M. Histopathological and immunohistochemical investigations in pneumonia caused by small ruminant plague, parainfluenza type -3 and respiratory syncytial virus of sheep in Elazığ region [Turkish]. Doctoral Thesis, Fırat University, Institute of Health Sciences, Elazığ, Türkiye 2013.
- Ülgen M, Sönmez G, Aydın F. Microbiological and histopathological investigations on lamb pneumonia [Turkish]. *Etilik Vet Mikrob Derg* 1997; 9(2): 55-70.
- Çomaklı S, Sağlam YS, Timurkan MÖ. Comparative

- detection of bovine herpesvirus-1 using antigen ELISA, immunohistochemistry and immunofluorescence methods in cattle with pneumonia. *Türk J Vet Anim Sci* 2019; 43(3): 306-313.
17. Leal É, Liu C, Zhao Z, et al. Isolation of a divergent strain of bovine parainfluenza virus type 3 (BPIV3) infecting cattle in China. *Viruses* 2019; 11(6): 489. doi: 10.3390/v11060489.
 18. Fenner FJ, Bachmann PA, Gibbs EPJ. *Veterinary virology*. Cambridge, USA: Academic Press 2014; 485-505.
 19. Jarikre TA, Emikpe BO. First report of immunohistochemical detection of Peste des petit ruminants, parainfluenza 3 and respiratory syncytial viral antigens in lungs of Nigerian goats. *J Immunoassay Immunochem* 2017; 38(5): 555-568.
 20. Yang Y, Wang FX, Sun N, et al. Development and evaluation of two truncated recombinant NP antigen-based indirect ELISAs for detection of bovine parainfluenza virus type 3 antibodies in cattle. *J Virol Methods* 2015; 222: 47-54.