

# Protective effects of propolis on ischemia-reperfusion injury in a rat testicular torsion and detorsion model

Emad Vakili-Sadeghi<sup>1</sup>, Alireza Najafpour<sup>1\*</sup>, Rahim Mohammadi<sup>2</sup>

<sup>1</sup> Department of Clinical Sciences, Faculty of Veterinary Medicine, Urmia Branch, Islamic Azad University, Urmia, Iran; <sup>2</sup> Department of Surgery and Diagnostic Imaging, Faculty of Veterinary Medicine, Urmia University, Urmia, Iran.

Article Info	Abstract
<b>Article history:</b> Received: 13 November 2022 Accepted: 26 January 2023 Available online: 15 July 2023	<p>The torsion model of testis in a rat was adopted for evaluation of possible effects of propolis (Prop) on ischemia-reperfusion (IS/REP) injury. The healthy male Wistar rats (totally 24 animals) were randomized into four groups (n = 6) and animals experienced bilateral testicular torsions as follows: In sham group just, laparotomy was performed and in IS group, animals experienced a 3 hr period testicular IS. In IS/REP group, a 3 hr period of IS followed by a 3 hr period of testicular REP for left testis and a one-week testicular REP for right testis were done. In this group animals were gavaged by 1.00 mL normal saline 1 hr before the onset of IS. In IS/REP/Prop group, the same procedures for IS/REP animals were followed as well as gavage of 1.00 mL Prop extract solution 1 hr before the onset of IS. Analyses of biochemistry, histology, inflammatory biomarkers and sperm parameters were carried out. In IS/REP/Prop group, nitric oxide synthase malondialdehyde, myeloperoxidase and 8-hydroxy-2 deoxyguanine in IS/REP/Prop group were significantly decreased and, superoxide dismutase, total glutathione, glutathione peroxidase, glutathione reductase and glutathione S-transferase were significantly increased compared to the other animals. In IS/REP/Prop group, seminiferous tubules (with normal spermatogenesis) showed all stages of spermatogenic cells with plentiful spermatozoa. Tubular deterioration and atrophy and spermatogenic cell loss in were seen in a limited extent. The mean concentrations of Interleukin-1 beta and tumor necrosis factor alpha in IS/REP/Prop were significantly decreased. Sperm quality was significantly improved by Prop in IS/REP/Prop group. It was concluded that Prop could be supportive in diminishing IS/REP injury in testicular tissue exposed to ischemia.</p>
<b>Keywords:</b> Ischemia-reperfusion Propolis Rat RT-PCR Testis	

© 2023 Urmia University. All rights reserved.

## Introduction

It has been reported that torsion and detorsion of testis is noteworthy medical concern for men with infertility. Twisting of the spermatic cord has considered to be an emergency situation because of turning of the testis and epididymis around the spermatic cord axis. Fifty percent of the cases of infertility are because of infertility of male partner generally involving one man in 20.<sup>1</sup> The yearly torsion incidence in testis was demonstrated to be one per 4,000 males. The incidence has been reported to get to peak in infants and full-grown people.<sup>2,3</sup> Instant medical interventions are obligatory to preserve tissue perfusion and help prevent damage in the testis. Since, this may end up reduced spermatogenesis in most of the patients, hence, everlastingly increases infertility rates.<sup>4</sup>

A proposed mechanism of tissue damage during reperfusion is a collection of the stimulated neutrophils generating reactive oxygen species (ROS).<sup>5</sup> The most detrimental consequence of free radicals is lipid peroxidation in the cell. Malondialdehyde (MDA), an end product of lipid peroxidation, results in severe cell damage via commencement of polymerization and cross-linking in components of membrane.<sup>6</sup> One of the deleterious products of DNA is 8-hydroxy-2 deoxyguanine (8-OH dG) that reacts with DNA.<sup>7,8</sup>

The poplar and conifer trees are resources of a natural product, propolis (Prop), collected by honey bees. Propolis is used as an antibiotic against foreign organisms and also to repair the cracks of the hives.<sup>9</sup> Propolis bears extensive biological activities like anti-inflammatory, anti-fungal, anti-oxidant and immune-stimulating activities.<sup>10</sup> Majority of these properties are associated with its anti-oxidant

### \*Correspondence:

Alireza Najafpour. DVM, DVSc  
Department of Clinical Sciences, Faculty of Veterinary Medicine, Urmia Branch, Islamic Azad University, Urmia, Iran  
E-mail: alireza.najafpour@iau.ac.ir



This work is licensed under a Creative Commons Attribution-NonCommercial-ShareAlike 4.0 International (CC BY-NC-SA 4.0) which allows users to read, copy, distribute and make derivative works for non-commercial purposes from the material, as long as the author of the original work is cited properly.

activity and free radical scavenging capacity.<sup>11</sup> Polyphenolics including aldehydes, caffeic acid and caffeic acid phenethyl ester are main ingredients of prop playing a crucial role in neurological ailments, cardiovascular problems, cancer pathophysiology and diabetes.<sup>12-15</sup> Effects of Prop on ovarian ischemia-reperfusion injury were studied and reported to augment regulatory T cells to exert anti-inflammatory effects.<sup>16</sup> Inhibition of apoptosis via preventing phosphorylation of proapoptotic proteins has also been reported for Prop.<sup>17</sup>

The present study was conducted to assess effect of oral administration of Prop on ischemia-reperfusion damage in testicular torsion/detorsion model in rats.

## Materials and Methods

**Preparation of propolis.** The water-soluble extract of Prop was obtained from a local market (Urmia, Iran). The extract of Prop was dissolved in 100 mL distilled water. Then, it was diluted at 200 mg kg<sup>-1</sup> concentrations. One milliliter of the solution was given to rats 1 hr before the onset of ischemia. The dose was selected according to the literature data.<sup>18</sup>

**Study design.** A range of 23.00 ± 3.00 °C in temperature along with continuous humidity in air and a normal light were prepared for 15 days before and during the experimentations. Then, the rats were placed in boxes with healthy food and water, *ad libitum*. All evaluations were done by an agent blind to the groups. The animals (totally 24 healthy male Wistar rats) were considered and randomized into four groups (n = 6) and experienced bilateral testicular torsion as follows: In Sham group, just laparotomy was done and the incision was sutured using 4/0 nylon (Supa, Tehran, Iran). In IS group, the testes were taken out through laparotomy incision and undergone ischemia for three hr. The testes were removed for all the assessments and the midline incision was sutured with 4/0 nylon. In IS/REP group, the testes were exteriorized through laparotomy incision and undergone ischemia for 3 hr. Then, the testes were detorted and reperfused for 3 hr. After the 3 hr reperfusion, the left testis was removed for biochemical, histological, molecular and inflammatory bio-markers assessments. The right testis was returned back to the scrotum, the laparotomy incision was closed and the rats were kept for a week. After one week, the rats were anesthetized and the right testis was removed for sperm parameters assessments. To elicit possible changes in sperm quality indices, the right testis was allocated to be reperfused for more one week. In IS/REP/Prop group, 1.00 mL Prop extract solution was gavaged 1 hr before the onset of ischemia to the rats and the same procedure for IS/REP group was performed in this group. The rationale for administration of Prop 1 hr before the onset of ischemia was based on the work of others<sup>18</sup> and that was because within that time the absorbable constituents of Prop could

be absorbed to circulatory system for possible preservation of the cells against reperfusion injury after detorsion.

**Surgical procedures.** To anesthetize the animals, 90.00 mg kg<sup>-1</sup> ketamine (Alfasan, Woerden, Netherlands) and 5.00 mg kg<sup>-1</sup> xylazine (Alfasan) were injected intraperitoneally (IP). Through a low midline laparotomy, the testis was taken out and removed. The 720° torsions were applied on the testes and kept moisturized using wet gauze. After termination of the torsion, the testes were detorted back for reperfusion. Based on the study design the testes were taken for further analyses. Ketamine (500 mg kg<sup>-1</sup>; IP) and xylazine (50.00 mg kg<sup>-1</sup>; IP) were administered to euthanize the animals.<sup>20</sup> The ethical rules were followed within the surgical procedures.<sup>19</sup> The study was registered under the ethical code of IR.IAU.URMIA.REC.1400.026.

**Biochemical assessments.** The tissue samples were kept at - 80.00 °C for 3 days and then, activities of enzymes were assessed. Liquid nitrogen in a mortar was used to ground the tissues. A 0.50 g of the tissue was used from each animal and then, 4.50 mL of an appropriate buffer was used for treatment. This mixture was homogenized on ice using an Ultra-Turrax® homogenizer (IKA, Staufen, Germany) for 15 min and centrifuged by a refrigerator centrifuge (Sigma Laborzentrifugen GmbH, Osterode, Germany) for 15 min, 3000 rpm at 4.00 °C. To investigate enzymatic activities, the supernatants were used. Antioxidant activities of the enzymes (Table 1) were assessed at room temperature according the methods of others.<sup>21</sup> Myeloperoxidase (MPO), isolation of DNA from tissue and cDNA hydrolysis with formic acid measurement of 8-OH dG were evaluated.<sup>21</sup> Total glutathione (tGSH), glutathione peroxidase (GPO), glutathione reductase (GSHRd) and glutathione S-transferase (GST) analyses were also carried out.<sup>20</sup>

**Histological assessments.** Histological assessments were based on the others as follows: After one-week reperfusion in right testes, they were exteriorized and fixed in 10.00% buffered formalin. The samples were then stained with Hematoxylin and Eosin and examined with a light microscope (Eclips E600; Nikon, Tokyo, Japan). The histopathological features of the tubules and the degree of damage were estimated based on others.<sup>22</sup> Also, mean diameter of seminiferous tubules (MSTD), testicular capsule thickness (TCT) and thickness of germinal epithelium (GET) were determined. To investigate substantial histopathological alterations in the tubules and germinal cells, Cosentino's histopathological score and testicular biopsy scores were adopted.<sup>23</sup> In brief, each testis was scored from 0 to 4 for each parameter, with the higher numbers indicating a more widely distributed pathological condition for that parameter within the tissue section being studied.<sup>23</sup>

**Measurement of testicular inflammatory biomarkers.** The homogenate sample from the left testis was used for measurement of testicular inflammatory biomarkers. The Interleukin-1 beta (IL-1β) and tumor

necrosis factor alpha (TNF- $\alpha$ ) concentrations were quantified according to the manufacturer's instructions and guidelines using enzyme-linked immunosorbent assay kit (CinnaGen Inc., Tehran, Iran).

**Sperm analysis.** The posterior part of epididymis of the right testis in each animal (see above) was excised and put in a Petri dish with 5.00 mL RPMI 1640 medium (Inoclon, Karaj, Iran). The epididymis was cut into the pieces with a sharp scalpel blade to facilitate sperm suspension in the medium culture. Finally, the Petri dish was kept in a 37.00 °C incubator for 15 min to facilitate sperm drainage. Sperm parameters were investigated based on the methods of the others.<sup>24</sup> In brief, 1:20 dilutions for counting of sperms were prepared. Then, 190  $\mu$ L of distilled water was added to 10.00  $\mu$ L of the sperms. The diluted sperm (10.00  $\mu$ L) was put on a Neubauer slide (Kisker Biotech GmbH & Co. KG, Steinfurt, Germany) to count the numbers of spermatozoa. To determine sperm motility, 10.00 mL of the medium with sperm was put on the Neubauer slide. Then, the sperm motility percentage was measured using a light microscopy. To determine sperm viability, 20.00  $\mu$ L of the semen sample was put on a slide and then, Eosin solution (20.00  $\mu$ L) was added to it. The Nigrosine solution (20.00  $\mu$ L) was added after 30 sec. Finally, to determine viability, percentages of live sperms (colorless ones) and dead sperms (having red color in head) were measured using a light microscopy. It should be noted that, immature spermatozoa were detected with the ones bearing cytoplasmic debris. For estimation of DNA strand damage, the samples of semen were washed three times using phosphate buffered saline. To get a final concentration, following removal of the supernatant, the sediment was obtained with phosphate buffered saline. Then, the smears from medium with sperm were prepared and dried in room temperature for half an hr. Then, they were put in an acetone-ethanol (1:1) container. Acridine orange solution was used to stain the smears for 7 min. Then, they were let to be dried in a dark place. Finally, they were examined with an immunofluorescence microscope (model 466300; Carl Zeiss, Jena, Germany).

**Statistical analysis.** Statistical analyses were made using SPSS (version 22.0; IBM Corp., Armonk, USA). One-way analysis of variance test was done and post hoc multiple comparisons were performed with least-squares differences. Kruskal-Wallis test was used for non-parametric data. Statistically significant difference was set at  $p < 0.05$ .

## Results

**Biochemical findings.** In the animals treated with Prop (IS/REP/Prop group) the mean values of SOD activities were significantly increased compared to the IS and IS/REP groups ( $p = 0.001$ ). Levels of tNOS, MDA, MPO and 8-OH dG (a DNA damage product) in IS/REP/Prop group when compared to IS and IS/REP groups, were significantly decreased ( $p = 0.001$ ). In IS/REP/Prop animals compared to IS and IS/REP ones, significantly increased levels of GSH, GPO, GSHRd and GST were observed ( $p = 0.001$ ; Table 1).

**Histological findings.** Histological features and scores for testicular biopsy are presented in Figure 1 and Table 2, respectively. Ischemia significantly reduced GET, MSTD, GET based on cell layers and TCT compared to the sham animals ( $p < 0.05$ ). The GET, GET based on cell layers, MSTD and TCT were considerably higher in IS/REP/Prop group compared to the IS and IS/REP groups ( $p < 0.05$ ). The Cosentino's score in the sham animals was significantly lower than other groups ( $p < 0.05$ ); however, this score was significantly reduced in IS/REP/ Prop group compared to the IS and IS/REP groups ( $p < 0.05$ ). No noticeable damage in the testis of sham animals was observed and MSTD were in normal morphology being confirmed by the high testicular biopsy score of  $9.33 \pm 0.51$ . In the IS group, tubular deterioration and atrophy and spermatogenic cell loss were observed and it was confirmed that there was a damage at levels of spermatozoa, spermatids and some spermatocytes. The testicular biopsy scores of  $5.33 \pm 0.51$  and  $6.66 \pm 0.51$  were recorded in IS and IS/REP groups, respectively. In the IS/REP/Prop group, MSTD (with normal spermatogenesis)

**Table 1.** Comparison of the levels of superoxide dismutase (SOD), nitric oxide synthase (NOS), malondialdehyde (MDA), myeloperoxidase (MPO), total glutathione (tGSH), glutathione peroxidase (GPO), glutathione S-transferase (GST), glutathione reductase (GSHRd) and a DNA damage product of 8-hydroxy-2 deoxyguanine (8-OH dG) in the testicular tissues of animals from all experimental groups. Data are expressed as mean  $\pm$  SD.

Parameters	Sham	IS	IS/REP	IS/REP/Prop
SOD (mmol mg <sup>-1</sup> per min)	70.50 $\pm$ 3.35 <sup>a</sup>	39.70 $\pm$ 0.76 <sup>c</sup>	60.30 $\pm$ 0.17 <sup>b</sup>	75.50 $\pm$ 3.40 <sup>a</sup>
NOS (nmol mg <sup>-1</sup> per min)	3.80 $\pm$ 0.14 <sup>a</sup>	3.60 $\pm$ 0.13 <sup>c</sup>	3.50 $\pm$ 0.55 <sup>b</sup>	3.20 $\pm$ 0.15 <sup>a</sup>
MDA ( $\mu$ mol g <sup>-1</sup> protein)	5.50 $\pm$ 0.10 <sup>a</sup>	12.90 $\pm$ 0.29 <sup>c</sup>	11.80 $\pm$ 0.13 <sup>b</sup>	5.30 $\pm$ 0.19 <sup>a</sup>
MPO (U g <sup>-1</sup> protein)	6.30 $\pm$ 0.24 <sup>a</sup>	15.90 $\pm$ 0.11 <sup>c</sup>	12.90 $\pm$ 0.20 <sup>b</sup>	7.20 $\pm$ 0.30 <sup>a</sup>
tGSH (nmol g <sup>-1</sup> protein)	9.80 $\pm$ 0.35 <sup>a</sup>	2.70 $\pm$ 0.20 <sup>c</sup>	4.70 $\pm$ 0.35 <sup>b</sup>	8.20 $\pm$ 0.75 <sup>a</sup>
GPO (U g <sup>-1</sup> protein)	37.70 $\pm$ 3.16 <sup>a</sup>	12.20 $\pm$ 2.18 <sup>c</sup>	17.00 $\pm$ 1.87 <sup>b</sup>	33.20 $\pm$ 2.49 <sup>a</sup>
GSHRd (U g <sup>-1</sup> protein)	33.50 $\pm$ 2.25 <sup>a</sup>	9.30 $\pm$ 1.88 <sup>c</sup>	16.70 $\pm$ 1.25 <sup>b</sup>	29.60 $\pm$ 2.40 <sup>a</sup>
GST (U g <sup>-1</sup> protein)	21.70 $\pm$ 1.25 <sup>a</sup>	10.60 $\pm$ 1.27 <sup>c</sup>	14.50 $\pm$ 1.30 <sup>b</sup>	19.00 $\pm$ 1.22 <sup>a</sup>
8-OH dG (pmol L <sup>-1</sup> )	1.20 $\pm$ 0.19 <sup>a</sup>	2.60 $\pm$ 0.19 <sup>c</sup>	2.20 $\pm$ 0.19 <sup>b</sup>	1.30 $\pm$ 0.19 <sup>a</sup>

IS: ischemia; REP: reperfusion; and Prop: propolis.

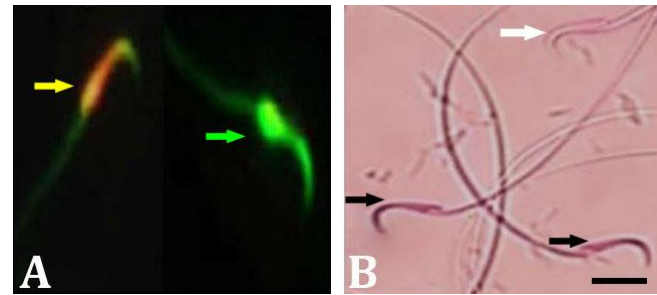
<sup>abc</sup> Different superscripts in each row indicate significant differences among groups at  $p < 0.05$ .

showed all stages of spermatogenic cells with plentiful spermatozoa. Tubular deterioration and atrophy and spermatogenic cell loss were seen in a limited extent. The testicular biopsy score of  $7.08 \pm 0.31$  was recorded in IS/REP/Prop group that was significantly increased compared to the IS and IS/REP groups ( $p < 0.05$ ).

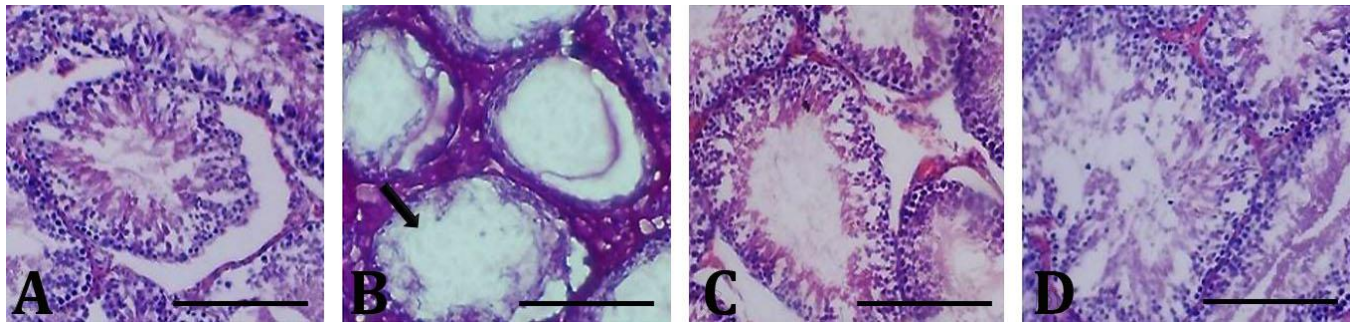
**Testicular inflammatory biomarkers analyses findings.** The mean concentrations of IL-1 $\beta$  in sham, IS, IS/REP and IS/REP/Prop groups were  $35.37 \pm 4.55$ ,  $79.55 \pm 0.25$ ,  $58.17 \pm 4.43$  and  $37.5 \pm 0.43$  pg mg $^{-1}$  protein, respectively. There was a significant difference between mean concentrations of IL-1 $\beta$  in IS/REP/Prop group compared to the other ones ( $p < 0.05$ ). The mean concentrations of TNF- $\alpha$  in sham, IS, IS/REP and IS/REP/Prop groups were  $31.27 \pm 3.19$ ,  $81.36 \pm 0.19$ ,  $65.19 \pm 4.19$  and  $44.35 \pm 0.19$  pg mg $^{-1}$  protein, respectively. There was a significant difference between mean concentrations of TNF- $\alpha$  in IS/REP/Prop group in comparison with the other ones ( $p < 0.05$ ).

**Sperm parameters findings.** The sperm count findings demonstrated a significant difference ( $p = 0.001$ ) between mean number of sperms in the IS/REP/Prop group in comparison with other groups. In the animals treated with Prop (IS/REP/Prop group), the mean values for sperm motility were significantly higher than other animals ( $p = 0.001$ ). The sperms stained with green nuclei

were normal and those stained with yellow and orange to red nuclei were considered as DNA damaged ones (Fig. 2A). In the animals treated with Prop (IS/REP/Prop group), the mean values for damaged DNA were significantly lower in comparison with other animals ( $p = 0.001$ ). The findings of sperm viability showed a significant difference between IS/REP/Prop group and other groups ( $p = 0.001$ ; Fig. 2B). Our findings indicated that sperm parameters were significantly improved in IS/REP/Prop group compared to the IS and IS/REP groups ( $p = 0.001$ ; Table 2).



**Fig. 2.** **A)** Fluorescent image of spermatozoa. Sperm with damaged DNA is depicted with bright yellow appearance (yellow arrow) and intact DNA is presented with light green appearance (green arrow), (Acridine orange staining; 1,000 $\times$ ). **B)** Assessment of sperm viability. White arrow shows live sperm with pale pink head and black arrows show dead spermatozoa with red or dark pink heads (Eosin-Nigrosine staining; 1,000 $\times$ ).



**Fig. 1.** Representative micrographs of the testicular tissue in **A)** sham, **B)** IS, **C)** IS/REP and **D)** IS/REP/Prop groups. Black arrow shows tubular deterioration and atrophy as well as spermatogenic cell loss in the IS group (Hematoxylin and Eosin staining, scale bar = 300  $\mu$ m). IS: ischemia; REP: reperfusion; and Prop: propolis.

**Table 2.** Histomorphometrical assessments of testicular tissue and sperm analysis findings in experimental animals. The values are expressed as mean  $\pm$  SD.

Parameters	Sham	IS	IS/REP	IS/REP/Prop
GET ( $\mu$ m)	$77.23 \pm 5.35^b$	$21.75 \pm 5.23^c$	$37.10 \pm 7.25^d$	$55.15 \pm 9.40^a$
MSTD ( $\mu$ m)	$286.17 \pm 19.55^b$	$97.57 \pm 34.33^c$	$186.17 \pm 20.12^d$	$250.10 \pm 15.14^a$
GET (based on cell layers)	$8.74 \pm 0.55^b$	$2.24 \pm 0.19^c$	$4.63 \pm 0.75^d$	$6.19 \pm 0.04^a$
TCT ( $\mu$ m)	$39.15 \pm 5.23^b$	$15.25 \pm 3.12^c$	$24.45 \pm 4.70^d$	$30.55 \pm 3.18^a$
Cosentino's score	$1.00 \pm 0.00^b$	$4.03 \pm 0.05^c$	$3.57 \pm 0.05^d$	$1.33 \pm 0.04^a$
Testicular biopsy score	$9.33 \pm 0.51^b$	$5.33 \pm 0.51^c$	$6.66 \pm 0.51^d$	$7.08 \pm 0.31^a$
Normal Sperms (%)	$83.85 \pm 6.34^b$	$68.10 \pm 7.70^c$	$71.80 \pm 5.10^d$	$73.35 \pm 7.50^a$
Number of sperms ( $\times 10^6$ mL $^{-1}$ )	$75.65 \pm 5.43^b$	$42.50 \pm 5.44^c$	$59.85 \pm 4.87^d$	$68.55 \pm 4.17^a$
Motility of sperms (%)	$65.74 \pm 3.87^b$	$31.87 \pm 5.88^c$	$40.45 \pm 4.77^d$	$55.77 \pm 3.64^a$
Viability of sperms (%)	$72.44 \pm 4.55^b$	$37.17 \pm 3.33^c$	$48.13 \pm 3.25^d$	$66.37 \pm 3.56^a$
DNA damaged sperms	$2.87 \pm 0.65^b$	$14.71 \pm 0.83^c$	$7.93 \pm 0.55^d$	$3.16 \pm 0.40^a$

IS: ischemia; REP: reperfusion; Prop: propolis. GET: germinal epithelium thickness; MSTD: mean seminiferous tubules diameter; and TCT: testicular capsule thickness.

<sup>abcd</sup> Different superscripts in each row indicate significant differences among groups at  $p < 0.05$ .

## Discussion

Nowadays, the strategy for management of the testis after torsion/detorsion is surgery; however, discovering more therapeutic alternatives is required.<sup>25</sup> Hence, in this work, the possible beneficial effect of Prop to avoid testicular injury in ischemia reperfusion circumstances in rat testes was studied and beneficial effects were found. Where the ischemia reperfusion takes place, numerous mechanisms take part in the pathogenesis.<sup>25</sup> It is thought that ROS generation in the cell triggers widespread damage to mitochondrial oxidative system.<sup>25</sup> Excessive amounts of ROS are generated in the cells undergoing ischemia invading mitochondrial DNA because of its distinct organizational features. This results in accumulation of a sensitive marker of oxidative DNA damage (8-OH dG).<sup>26,27</sup>

Propolis is the bee product containing the highest amount of phenolics; thus, it has been deeply studied for anti-oxidant and radical scavenging activities.<sup>28</sup> It has been shown that Prop treatment significantly reduces MPO and MDA levels in rats ovary undergoing ischemia reperfusion.<sup>29</sup> It has been demonstrated that Prop antagonizes the damage induced by cerebral ischemia reperfusion through suppression of MDA and elevation of reduced GSH, SOD, GPO and catalase levels in the brain homogenates of rats with cerebral ischemia reperfusion injury.<sup>30</sup> Kaya *et al.*, have studied the protective effect of Prop on myocardial ischemia reperfusion injury in rats and showed that Prop increases total anti-oxidant status and SOD, and decreases total oxidant status in rats.<sup>31</sup> da Costa *et al.*, have reported that red Prop significantly improves oxidative stress parameters in ischemia reperfusion acute renal injury.<sup>32</sup> Consistent with above-mentioned report, in the present study, it was found that Prop administration significantly increased SOD, GSH, GPO, GSHRd and GST, and decreased NOS, MDA, MPO and a DNA damage product of 8-OH dG.

Changes in histological parameters (GET, MSTD, GET based on cell layers and TCT) have been used in the evaluation of the cell condition.<sup>33</sup> In the present study, it was found that Prop administration considerably increased GET, MSTD, and GET based on cell layers as well as number, motility and viability of sperms. The DNA damage was also decreased. In agreement with our study, others have demonstrated that Prop treatment causes mild reduction of histological changes induced by ischemia reperfusion in ovarian tissue and subsequently ameliorates the ovarian damage.<sup>29</sup> In a previous study, protective effect of Prop on myocardial ischemia reperfusion I/R injury in rats was reported. It has been demonstrated that the histological lesions are ameliorated in Prop-treated rats.<sup>32</sup>

Several studies have reported anti-inflammatory properties of Prop, possibly linked to the presence of

phenolic acids. The release of cytokines such as IL-1 $\beta$  and TNF- $\alpha$  after reperfusion results in recruitment of neutrophils and macrophages, causing germ cell apoptosis, spermatogenesis disruption and testicular atrophy.<sup>34</sup> Our results demonstrated increased testicular TNF- $\alpha$  and IL-1 $\beta$  in ischemia reperfusion untreated group; whereas, Prop-treated animals showed a significant decrease in their levels in comparison with untreated ones. This finding was consistent with findings of others showing significant decrease in TNF- $\alpha$  levels where Prop was used in ovarian ischemia reperfusion therapy in rats.<sup>29</sup>

The present study findings were encouraging; however, the duration of the experiment was rather short; hence, the detailed experimentations are essential to evaluate clinical consequences of Prop administration following testicular ischemia reperfusion injury that could be considered as shortcomings of the present work.

In conclusion, results of our experimentation showed that Prop administration might be beneficial in minimalizing ischemia reperfusion injury in testicular tissue exposed to ischemia. The precise mechanisms of Prop effects on testicular tissue preservation could be more intricate than our results that remain to be investigated in depth.

## Acknowledgments

This study was supported in part by Vice-Chancellor for Research and Technology of Islamic Azad University, Urmia Branch, Urmia, Iran, being appreciated by the authors. The authors are grateful to the Solid Tumor Research Center, Urmia University of Medical Sciences, Urmia, Iran, and Urmia Pathobiology Center, Urmia, Iran, for their technical helps. The present study was a part of a research project performed as a dissertation of the first author submitted as a partial fulfilment of the degree of DVSc at the Islamic Azad University, Urmia Branch, Urmia, Iran.

## Conflict of interest

The authors declare that there is no conflict of interest.

## References

1. McLachlan RI, de Krester DM. Male infertility: the case for continued research. *Med J Aust* 2001; 174(3): 116-117.
2. Srinath H. Acute scrotal pain. *Aus Fam Physician* 2013; 42(11): 790-792.
3. Arap MA, Vicentini FC, Cocuzza M, et al. Late hormonal levels, semen parameters, and presence of antisperm antibodies in patients treated for testicular torsion. *J Androl* 2007; 28(4): 528-532.
4. Parhizkar P, Mohammadi R, Shahrooz R, et al. Effects of



- pyrroloquinoline quinone (PQQ) on ischemia-reperfusion injury in rat ovaries: histological and biochemical assessments. *Bull Emerg Trauma* 2019; 7(1): 35-40.
5. Javanmardi S, Khordadmehr M. Benidipine reduces ischemia/reperfusion injury following testicular torsion/detorsion in rats. *Iran J Vet Surg* 2017; 12(2): 21-30.
  6. Girotti AW. Lipid hydroperoxide generation, turnover, and effector action in biological systems. *J Lipid Res* 1998; 39(8): 1529-1542.
  7. Huang HY, Helzlsouer KJ, Appel LJ. The effects of vitamin C and vitamin E on oxidative DNA damage: results from a randomized controlled trial. *Cancer Epidemiol Biomarkers Prev* 2000; 9(7): 647-652.
  8. Ames BN, Shigenaga MK, Hagen TM. Oxidants, antioxidants, and the degenerative diseases of aging. *Proc Natl Acad Sci USA* 1993; 90(17): 7915-7922.
  9. El-Guendouz S, Al-Waili N, Aazza S, et al. Antioxidant and diuretic activity of co-administration of *Capparis spinosa* honey and propolis in comparison to furosemide. *Asian Pac J Trop Med* 2017; 10(10): 974-980.
  10. Park SG, Lee DY, Seo SK, et al. Evaluation of anti-allergic properties of caffeic acid phenethyl ester in a murine model of systemic anaphylaxis. *Toxicol Appl Pharmacol* 2008; 226(1): 22-29.
  11. Sforzin JM. Biological properties and therapeutic applications of propolis. *Phytother Res* 2016; 30(6): 894-905.
  12. Barbosa RA, Nunes TL, Nunes TL, et al. Hydroalcoholic extract of red propolis promotes functional recovery and axon repair after sciatic nerve injury in rats. *Pharm Biol* 2016; 54(6): 993-1004.
  13. Chen CC, Kuo CY, Chen RF. Role of CAPE on cardiomyocyte protection via connexin 43 regulation under hypoxia. *Int J Med Sci* 2016; 13(10): 754-758.
  14. Kabała-Dzik A, Rzepecka-Stojko A, Kubina R, et al. Migration rate inhibition of breast cancer cells treated by caffeic acid and caffeic acid phenethyl ester: an in vitro comparison study. *Nutrients* 2017; 9(10): 1144. doi: 10.3390/nu9101144.
  15. Nie J, Chang Y, Li Y, et al. Caffeic acid phenethyl ester (propolis extract) ameliorates insulin resistance by inhibiting JNK and NF-κB inflammatory pathways in diabetic mice and HepG2 cell models. *J Agric Food Chem* 2017; 65(41): 9041-9053.
  16. Cheung KW, Sze DM, Chan WK, et al. Brazilian green propolis and its constituent, Artepillin C inhibits allogeneic activated human CD4 T cells expansion and activation. *J Ethnopharmacol* 2011; 138(2): 463-471.
  17. Tang H, Yao X, Yao C, et al. Anti-colon cancer effect of caffeic acid p-nitro-phenethyl ester *in vitro* and *in vivo* and detection of its metabolites. *Sci Rep* 2017; 7: 7599. doi: 10.1038/s41598-017-07953-8.
  18. Koc K, Erol HS, Colak S, et al. The protective effect of propolis on rat ovary against ischemia-reperfusion injury: immunohistochemical, biochemical and histopathological evaluations. *Biomed Pharmacother* 2019; 111: 631-637.
  19. Ethical standards for investigations of experimental pain in animals. The committee for research and ethical issues of the international association for the study of pain. *Pain* 1980; 9(2): 141-143.
  20. Animal euthanasia policy. Approved and adopted. Available at: <https://research.wustl.edu/wp-content/uploads/2017/05/Euthanasia.pdf>. Accessed May 03, 2023.
  21. Esmaeilsani Z, Barati F, Mohammadi R, et al. Effects of curcumin nanoparticles on the tissue oxidative stress following testicular torsion and detorsion in rat model. *Iran J Vet Surg* 2019; 14(2): 97-104.
  22. O'Shaughnessy PJ, Monteiro A, Verhoeven G, et al. Effect of FSH on testicular morphology and spermatogenesis in gonadotrophin-deficient hypogonadal mice lacking androgen receptors. *Reproduction* 2010; 139(1):177-184.
  23. Cosentino MJ, Nishida M, Rabinowitz R, et al. Histopathology of prepubertal rat testes subjected to various durations of spermatic cord torsion. *J Androl* 1986; 7(1): 23-31.
  24. Moloody-Tappe M, Shahrooz R, Razi M, et al. The effect of CoQ10 on testicular tissue in rats treating with busulfan: sperm quality and histological change. *Iran J Vet Surg* 2018; 13(1): 29-38.
  25. Dai C, Ciccotosto GD, Cappai R, et al. Rapamycin confers neuroprotection against colistin-induced oxidative stress, mitochondria dysfunction, and apoptosis through the activation of autophagy and mTOR/Akt/CREB signaling pathways. *ACS Chem Neurosci* 2018; 9(4): 824-837.
  26. Tan Q, Yan X, Song L, et al. Induction of mitochondrial dysfunction and oxidative damage by antibiotic drug doxycycline enhances the responsiveness of glioblastoma to chemotherapy. *Med Sci Monit* 2017; 23: 4117-4125.
  27. Pan Y, Wang N, Xia P, et al. Inhibition of Rac1 ameliorates neuronal oxidative stress damage via reducing Bcl-2/Rac1 complex formation in mitochondria through PI3K/Akt/mTOR pathway. *Exp Neurol* 2018; 300: 149-166.
  28. Viuda-Martos M, Ruiz-Navajas Y, Fernández-López J, et al. Functional properties of honey, propolis, and royal jelly. *J Food Sci* 2008; 73(9): R117-R124.
  29. Geyikoglu F, Koc K, Erol HS, et al. The propolis and boric acid can be highly suitable, alone/or as a combinatory approach on ovary ischemia-reperfusion injury. *Arch Gynecol Obstet* 2019; 300(5): 1405-1412.
  30. Abdel-Rahman RF, Alqasoumi SI, Ogaly HA, et al. Propolis ameliorates cerebral injury in focal cerebral

- ischemia/reperfusion (I/R) rat model via upregulation of TGF- $\beta$ 1. *Saudi Pharm J* 2020; 28(1): 116-126.
31. Kaya ST, Agan K, Fulden-Agan A, et al. Protective effect of propolis on myocardial ischemia/reperfusion injury in males and ovariectomized females but not in intact females. *J Food Biochem* 2022; 46(7): e14109. doi: 10.1111/jfbc.14109.
  32. da Costa MF, Libório AB, Teles F, et al. Red propolis ameliorates ischemic-reperfusion acute kidney injury. *Phytomedicine* 2015; 22(9): 787-795.
  33. Celik O, Turkoz Y, Hascalik S, et al. The protective effect of caffeic acid phenethyl ester on ischemia-reperfusion injury in rat ovary. *Eur J Obstet Gynecol Reprod Biol* 2004; 117(2): 183-188.
  34. Armutcu F, Akyol S, Ustunsoy S, et al. Therapeutic potential of caffeic acid phenethyl ester and its anti-inflammatory and immunomodulatory effects (Review). *Exp Ther Med* 2015; 9(5): 1582-1588.