




1st International Congress of Veterinary Medicinal Plants and Traditional Medicine



Plant Products and Pharmacology
Effects of Plant Products on Animal and Zoonotic Pathogens
Plant Products and Food Science
Traditional Veterinary Medicine
Phytochemistry and Biotechnology in Medicinal Plants

Topics:

October
21 & 22
2024
Urmia - Iran



www.licvmp.urmia.ac.ir

www.licvmp.com

Successful treatment of *Candida albicans*-induced fungal cystitis in a dog using caspofungin: a case report

Sei-Myoung Han*

Department of Animal Health and Welfare, College of Health and Biotechnology, Semyung University, Jecheon, South Korea.

| Article Info | Abstract |
|---|---|
| Article history: Received: 28 December 2023 Accepted: 07 May 2024 Available online: 15 August 2024 | <p>A 7-year-old castrated male poodle was brought to the referral Animal Medical Center and diagnosed with diabetes and pancreatitis. One month later, the patient presented with cloudy urine, and ultrasonography revealed a large number of spherical substances. The patient was subsequently diagnosed with fungal cystitis with <i>Candida albicans</i>. Initially, 10.00 mg kg⁻¹ itraconazole was prescribed twice daily for six weeks, and the symptoms of prolonged urination improved; however, the fungal balls persisted in the bladder. The six months later, the patient showed recurrent symptoms, such as dysuria and stranguria; therefore, 5.00 mg kg⁻¹ fluconazole was prescribed twice daily; however, it was not effective. Subsequently, 1.00 mg kg⁻¹ caspofungin once daily was administered for three consecutive days. Finally, the fungal balls in the bladder disappeared. The patient was regularly monitored after completion of treatment and, 17 months later, doing well without recurrence. Few reports exist on the use of caspofungin in veterinary medicine. The recommended dose of caspofungin in dogs remains unknown. In the case of azole-resistant <i>Candida</i>, treatment using caspofungin should be considered; although, additional studies on the established dosing and side effects are needed.</p> |
| Keywords: Anti-fungal drugs Azole-resistant candidiasis <i>Candida albicans</i> Caspofungin Fungal cystitis | |

© 2024 Urmia University. All rights reserved.

Introduction

Fungal urinary tract infections (UTIs) are caused by the over-growth of fungal yeast. Although fungal bladder or UTIs are uncommon in dogs, *Candida* spp. account for most fungal infections. *Candida* spp. are normal flora of the upper respiratory, gastrointestinal, and urogenital tracts of dogs; however, they can cause opportunistic genitourinary fungal infections in dogs.^{1,2} Several cases of *Candida* spp. infections and treatment have been reported; particularly, those associated with the long-term use of antibiotics, immunosuppressive drugs, and diabetes mellitus.³⁻⁵ In most cases, treatment is attempted and managed successfully using azole drugs; however, resistance to azole-related drugs has been observed.^{6,7} We report the case of a diabetic dog infected with *Candida albicans* that was unresponsive to azole-related anti-fungal agents (itraconazole and fluconazole).

Case Description

A 7-year-old castrated male poodle was brought to the referral Animal Medical Center with signs of depression,

weight loss, and polydipsia. Routine blood workups, such as complete blood counts, serum biochemistry, urinalysis on the collected urine by cystocentesis, abdominal radiography (AccuRay-603R; DK Medical Systems, Seoul, Korea), and ultrasonography (HD15; Philips, Hamburg, Germany) were conducted. Blood analysis (Dri-Chem NX700; Fujifilm Corp., Tokyo, Japan) revealed abnormal alkaline phosphatase (1,100 U L⁻¹; Reference range: 47.00 - 254 U L⁻¹), and hyperglycemia (glucose level: 539 mg dL⁻¹; Reference range: 75.00 - 128 mg dL⁻¹). Thus, urinalysis with dipstick showed glucosuria (2+) and ketonuria (3+) with a specific gravity of 1.046. The amount of urine sediment was small, and bacteria or cells were not found on microscopic examination. The canine pancreatic lipase test (Canine SNAP cPL; IDEXX Laboratories Inc., Westbrook, USA) was also positive. Based on the results, the patient was diagnosed with diabetes mellitus, ketosis, and pancreatitis. While providing supportive care for pancreatitis and ketosis, neutral-protamine-Hagedorn (NPH) insulin (2.00 U, twice daily, Subcutaneously; Humulin N; Eli Lilly and Co., Seoul, Korea) was prescribed for diabetes control at the initial dose. One month later, during a routine checkup, the owner reported that the

*Correspondence:

Sei-Myoung Han. DVM, PhD

Department of Animal Health and Welfare, College of Health and Biotechnology, Semyung University, Jecheon, South Korea

E-mail: smhan@semyung.ac.kr



This work is licensed under a Creative Commons Attribution-NonCommercial-ShareAlike 4.0 International (CC BY-NC-SA 4.0) which allows users to read, copy, distribute and make derivative works for non-commercial purposes from the material, as long as the author of the original work is cited properly.

patient had cloudy urine. Body temperature and other physical examination parameters were normal. Complete blood count, serum chemistry, urinalysis, abdominal radiography, and ultrasonography were performed. Abdominal ultrasonography revealed numerous spherical structures without acoustic shadowing. Urine being collected *via* cystocentesis was slightly cloudy, and urinalysis revealed concentrated urine (specific gravity: 1.036), aciduria (pH: 6.00), glucosuria (2+), and leukocyturia, but no proteinuria or ketonuria. Fungal budding yeast and pseudohyphae were detected in the urine sediment test. A urine sample was submitted to IDEXX Laboratories (Seoul, South Korea) for microbiological culture, which confirmed the presence of *C. albicans*.

Because it was thought that the fungal ball was partially obstructing urination, treatment for cystitis was initiated with 10.00 mg kg⁻¹ itraconazole (Nelson Pharm Korea, Seoul, South Korea) twice daily,³ to improve the symptoms of prolonged urination. The symptoms of prolonged urination improved somewhat; however, the fungal balls persisted in the bladder. Because the treatment was judged to be ineffective, itraconazole administration for 6 weeks was discontinued, and no further treatment was attempted because the patient was able to urinate.

Six months after the diagnosis of *Candida* infection, the patient was brought to the hospital as an emergency with symptoms of dysuria, stranguria, abdominal distension, and vomiting. On abdominal palpation, the bladder was distended, and the patient was considered unable to urinate due to urethral obstruction by the fungal ball. Blood tests revealed no significant changes, except for an increase in white blood cells (23,000 μL^{-1} ; Reference range: 6,000 -17,000 μL^{-1}) and elevated liver enzymes (alanine aminotransferase: 89.00 U L⁻¹; Reference range: 17.00 - 78.00 U L⁻¹ and alkaline phosphatase: 2,333 U L⁻¹; Reference range: 47.00 - 254 U L⁻¹). Ultrasonography revealed a significant increase in the number of previously identified fungal balls. Fluconazole was prescribed at a dose of 5.00 mg kg⁻¹ twice daily (A Progen Fluconazole cap; Aprogen Biologics Seoul, South Korea).⁶ Simultaneously, a urinary balloon catheter was inserted through the urethra into the urinary bladder. Bladder lavage was conducted with 0.90% normal saline solution (volume range: 50.00 - 200 mL) without antibiotics, until the retrieved fluid was clear.

Despite continuous fluconazole administration and bladder lavage for 7 days, no improvement was noted in clinical symptoms, and fungal budding yeast and pseudohyphae were still detected in the urine (Fig. 1). Therefore, fluconazole was changed to 1.00 mg kg⁻¹ caspofungin (MSD-Korea, Seoul, South Korea) once daily. Caspofungin (50.00 mg) was diluted in 250 mL 0.90% normal saline (final concentration: 0.20 mg mL⁻¹) and intravenously injected for 1 hr for three consecutive days.^{6,8} On the third

day of treatment, the fungal balls in the bladder had disappeared. Thus, caspofungin was administered three times *per* week and subsequently discontinued and the bladder lavage was discontinued because the substances discharged during bladder lavage were significantly reduced. Fifteen days after the first administration of caspofungin, a urine culture test was requested again and *Candida* was no longer identified. Figure 2 shows the ultrasound examination of the substances in the bladder from the time of *C. albicans* diagnosis to the termination of treatment. After completing treatment, the patient was regularly monitored every 2 - 3 months for *C. albicans* recurrence and diabetes. Seventeen months after treatment, the patient was doing well, with no recurrence, except for the development of bacterial cystitis and calcium oxalate crystalluria.

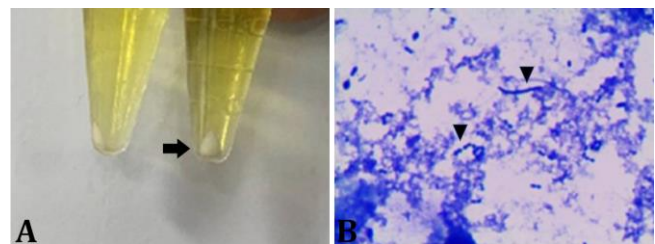


Fig. 1. **A)** The arrow indicates sediment in urine after centrifugation; **B)** Pseudohyphae and budding yeast (arrowheads) are observed under the microscope after Diff-Quik® staining of the urine sediment (400 \times).

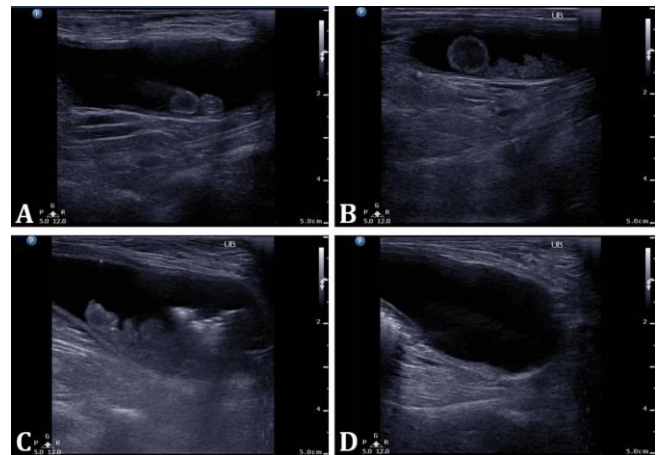


Fig. 2. Ultrasonographic findings of the bladder. **A)** Ultrasound at the time of diagnosis. **B)** Worsening of symptoms. A large amount of mobile echogenic ball-shaped matter without acoustic shadowing is observed. **C)** Ultrasound view before caspofungin administration. **D)** Bladder ultrasound after the termination of caspofungin administration. The previously seen spherical material is not identified.

Even after caspofungin administration, there was no significant change in blood test results compared to those before administration. Blood test results of the patient before and after caspofungin administration are summarized in Table 1.

Table 1. Changes in blood analysis before and after starting caspofungin treatment. Based on the day of caspofungin administration, the blood test results before (Day -9) and after (Days 2, 16, and 135) treatment are presented.

| Parameters | Day -9 | Day 2 | Day 16 | Day 135 | Normal range |
|--|---------------|---------------|---------------|---------|---------------|
| White blood cells ($\times 10^3 \mu\text{L}^{-1}$) | 23.10 | Not available | Not available | 7.80 | 6.00 - 17.00 |
| Red blood cells ($\times 10^6 \mu\text{L}^{-1}$) | 6.93 | Not available | Not available | 7.48 | 5.50 - 8.50 |
| Hematocrit (%) | 55.50 | Not available | Not available | 55.30 | 37.00 - 55.00 |
| Platelet ($\times 10^3 \mu\text{L}^{-1}$) | 318 | Not available | Not available | 478 | 150 - 500 |
| Alanine aminotransferase (U L ⁻¹) | 89.00 | 31.00 | 81.00 | 127 | 17.00 - 78.00 |
| Aspartate aminotransferase (U L ⁻¹) | 27.00 | 21.00 | 37.00 | 29.00 | 17.00 - 44.00 |
| Alkaline phosphatase (U L ⁻¹) | 2,333 | 1,082 | 1,312 | 1,386 | 47.00 - 254 |
| Gamma-glutamyl transferase (U L ⁻¹) | 80.00 | 25.00 | 20.00 | 41.00 | 0.00 - 11.00 |
| Blood urine nitrogen (mg dL ⁻¹) | Not available | 9.10 | 12.80 | 8.50 | 9.20 - 29.20 |
| Creatinine (mg dL ⁻¹) | Not available | 0.27 | 0.28 | 0.29 | 0.40 - 1.40 |
| Glucose (mg dL ⁻¹) | 506 | 148 | 250 | 329 | 80.00 - 120 |
| Total protein (g dL ⁻¹) | Not available | Not available | 7.30 | 6.80 | 5.40-7.10 |
| Albumin (g dL ⁻¹) | Not available | Not available | 4.10 | 4.00 | 2.60-4.00 |
| Triglyceride (U L ⁻¹) | > 500 | Not available | > 500 | > 500 | 30.00 - 133 |
| Total cholesterol (mg dL ⁻¹) | 281 | Not available | 241 | > 450 | 111 - 312 |
| C-reactive protein (mg L ⁻¹) | < 9.00 | Not available | Not available | < 9.00 | 0.00 - 9.00 |

Discussion

Candida spp. are natural inhabitants of the upper respiratory, gastrointestinal, and urogenital tracts of dogs and can cause opportunistic infections in immunocompromised animals or those undergoing long-term treatment with antibiotics, corticosteroids, and immunosuppressive drugs.² Moreover, infections in the urinary system of dogs with diabetes have been reported.^{6,7} Recently, Reagan *et al.*⁵ investigated the risk factors for candida UTIs in dogs and indicated that they were related to antibiotic use, among several factors that can cause candidiasis (use of antibiotics and immunosuppressants, urinary catheterization, diabetes, and hospitalization). Patients with diabetes had an increased susceptibility to *Candida* spp. owing to an infection being exacerbated in cases of uncontrolled hyperglycemia and immunosuppression.^{9,10}

In human medicine, the necessity for candiduria treatment is uncertain because of the low risk of candidemia. Thus, the concomitant bacterial cystitis should be treated first, and only thereafter should anti-fungal treatment be considered. Because asymptomatic candiduria does not benefit from anti-fungal treatment,¹¹ it should not be treated except in immunocompromised patients. Symptomatic *Candida* infections (*e.g.*, pyelonephritis, prostatitis, and epididymo-orchitis) must be treated with appropriate anti-fungal agents.¹²

Azole drugs are primarily used in patients with symptomatic candiduria. Among azole drugs, fluconazole is the first-line anti-fungal drug for candida cystitis treatment. It is usually recommended to prescribe fluconazole for 1 week at a dose of 2.50 - 5.00 mg kg⁻¹, twice daily for dogs and 50.00 mg kg⁻¹, once daily for cats; however, the prescription period varies depending on the infection.¹³ A 9-year-old dog diagnosed with fungal cystitis caused by *C. albicans* was managed and successfully

treated using itraconazole.³ However, in human medicine, the use of azole agents, such as itraconazole or ketoconazole, is not recommended for patients with *Candida* UTIs because these drugs are metabolized *via* the liver. Thus, only small amounts are excreted in the urine.¹¹ In contrast, fluconazole maintains high concentrations in the bladder because the active drug is excreted in the urine.¹⁴

In this case, although itraconazole was administered for 6 weeks, the number of fungal balls was not significantly reduced. Itraconazole was ineffective; thus, the drug was discontinued. Then, clinical symptoms such as dysuria and stranguria suddenly appeared, and fluconazole treatment was initiated; however, the symptoms of dysuria and stranguria persisted. Bladder lavage with normal saline was performed simultaneously to reduce the number of fungal balls, but the clinical symptoms did not improve noticeably. Therefore, it was tentatively judged to be an azole-resistant infection, and drug conversion was considered.

Caspofungin is a parenteral anti-fungal drug, and few reports exist on its use in veterinary medicine. It was initially prescribed for invasive aspergillosis or *Candida* infection.¹⁵ The recommended dose of caspofungin in dogs is unknown; however, Schultz *et al.*⁸ administered 1.00 mg kg⁻¹ intravenously (every 24 hr) in 250 mL of 0.90% sodium chloride for 1 hr. After the clinical symptoms improved, it was administered three times a week in dogs with systemic aspergillosis. In another study, when caspofungin was administered intravenously at a dose of 1.00 mg kg⁻¹, once daily, for 14 days, the clinical symptoms improved, but the infection persisted.⁶ In this case, a similar strategy to that used by Schultz *et al.* was used;⁸ caspofungin was administered for three consecutive days and then, three times a week. Finally, the fungal balls and clinical symptoms such as pollakiuria, stranguria, and urinary retention were completely disappeared. The side effects of caspofungin in humans include hypersensitivity

to the drug (*e.g.*, redness, facial swelling, and itching), pain at the injection site, and hepatic failure; however, it is considered relatively safe. Since the side effects of this drug in companion animals are not well known, the patient's condition was observed throughout drug administration, and no adverse reactions occurred during the treatment period.

Other related studies identified over-expression of the ATP transporter genes, *CDR1* and *PDH1*, in *Candida glabrata*, causing azole resistance by increasing drug efflux.⁶ In the present case, a dog with diabetes and UTI was treated using itraconazole and fluconazole, but the clinical symptoms did not improve. Therefore, we tentatively determined that the strain was resistant to azole drugs; however, an anti-fungal susceptibility test or genotyping was not performed. This is a limitation of this case study.

In the present case, caspofungin was successfully administered and no recurrence was observed. Treatment using caspofungin could be considered if there is no improvement in clinical symptoms using fluconazole. However, treatment protocols for *Candida* infections and the recommended dose of caspofungin have not yet been established in veterinary medicine and additional studies are needed.

Candida albicans is a rare opportunistic infection in veterinary medicine. Clinical symptoms such as dysuria, oliguria, and hematuria may be observed; therefore, if symptoms appear, treatment is necessary. In this case, caspofungin was successfully administered to a patient in whom azole drugs had minimal effect. Therefore, successful treatment with caspofungin is expected in patients with azole-resistant *Candida* infection. However, further studies on the pharmacological actions of caspofungin and clinical reports are needed to establish the dose and administration methods to be used in veterinary medicine.

Acknowledgments

The author thanks the staff at Animal Medical Center (Gyeonggi-do, South Korea) for their assistance with patient care.

Conflict of interest

No conflict of interest to declare.

References

- Greene CE, Sykes JE. Infectious diseases of the dog and cat. 4th ed. Philadelphia, USA: Saunders 2012; 666-671.
- Jang JI, Yoon WK, Hyun CH. *Candida albicans* urinary tract infection in a Shih Tzu dog with immune-mediated hemolytic anemia. Korean J Vet Res 2017; 57(2): 139-141.
- Choo D, Lee K, Yoon H. Fungal balls detected using ultrasonography in the urinary bladder of a dog. Vet Radiol Ultrasound 2022; 63(2): e1-e4. doi: 10.1111/vru.13034.
- Glińska K, Jankowski M, Kubiak K. et al. Fungal peritonitis in dog caused by *Candida albicans* - a case report and literature overview. Turk J Vet Anim Sci 2013; 37: 482-485.
- Reagan KL, Dear JD, Kass PH, et al. Risk factors for *Candida* urinary tract infections in dogs and cats. J Vet Intern Med 2019; 33(2): 648-653.
- Kim M, Lee H, Hwang SY, et al. Azole resistance caused by increased drug efflux in *Candida glabrata* isolated from the urinary tract of a dog with diabetes mellitus. Mycobiology 2017; 45(4): 426-429.
- Álvarez-Pérez S, García ME, Cutuli MT, et al. Acquired multi-azole resistance in *Candida tropicalis* during persistent urinary tract infection in a dog. Med Mycol Case Rep 2016; 11: 9-12.
- Schultz RM, Johnson EG, Wisner ER, et al. Clinico-pathologic and diagnostic imaging characteristics of systemic aspergillosis in 30 dogs. J Vet Intern Med 2008; 22(4): 851-859.
- Rodrigues CF, Rodrigues ME, Henriques M. *Candida* sp. infections in patients with diabetes mellitus. J Clin Med 2019; 8(1): 76. doi: 10.3390/jcm8010076.
- Goswami R, Dadhwal V, Tejaswi S, et al. Species-specific prevalence of vaginal candidiasis among patients with diabetes mellitus and its relation to their glycaemic status. J Infect 2000; 41(2): 162-166.
- Sobel JD, Kauffman CA, McKinsey D, et al. Candiduria: a randomized, double-blind study of treatment with fluconazole and placebo. Clin Infect Dis 2000; 30(1): 19-24.
- Kim SJ, Ryu JH, Kim YB et al. Management of candida urinary tract infection in the elderly. Urogenit Tract Infect 2019; 14(2): 33-41.
- MSD Manual Professional Version. Fungal urinary tract infections. Available at: <https://www.msdmanuals.com/professional/genitourinary-disorders/urinary-tract-infections-utis/fungal-urinary-tract-infections>. Accessed May 24, 2024.
- Pappas PG, Kauffman CA, Andes D, et al. Clinical practice guidelines for the management of candidiasis: 2009 update by the Infectious Diseases Society of America. Clin Infect Dis 2009; 48(5): 503-535.
- Plumb DC. Plumb's veterinary drug handbook. 8th ed. New Jersey, USA: Wiley Blackwell 2015; 224-225.