




1st International Congress of Veterinary Medicinal Plants and Traditional Medicine



Plant Products and Pharmacology
Effects of Plant Products on Animal and Zoonotic Pathogens
Plant Products and Food Science
Traditional Veterinary Medicine
Phytochemistry and Biotechnology in Medicinal Plants

Topics:

October
21 & 22
2024
Urmia - Iran



www.licvmp.urmia.ac.ir

www.licvmp.com

Comparative study of echocardiographic parameters in healthy and dilated cardiomyopathy-affected dogs

Pritish Rath^{1*}, Biswadeep Jena², Sidhartha Sankar Behera², Srinivas Sathapathy³, Prasana Kumar Rath⁴, Swetapadma Sarangi⁵

¹ Department of Veterinary Surgery and Radiology, Faculty of Veterinary and Animal Sciences, West Bengal University of Animal and Fishery Sciences, Kolkata, India; ² Department of Veterinary Surgery and Radiology, College of Veterinary Science and Animal Husbandry, Odisha University of Agriculture and Technology, Bhubaneswar, India; ³ Department of Veterinary Anatomy and Histology, College of Veterinary Science and Animal Husbandry, Odisha University of Agriculture and Technology, Bhubaneswar, India; ⁴ Department of Veterinary Pathology, College of Veterinary Science and Animal Husbandry, Odisha University of Agriculture and Technology, Bhubaneswar, India; ⁵ Department of Veterinary Preventive Medicine, Madras Veterinary College, Tamil Nadu Veterinary and Animal Sciences University, Chennai, India.

Article Info	Abstract
Article history: Received: 21 December 2023 Accepted: 07 April 2024 Available online: 15 August 2024	Echocardiography is a non-invasive and gold standard imaging tool for diagnosing dilated cardiomyopathy (DCM) in dogs. This study aimed to compare the echocardiographic parameters between healthy and DCM-affected dogs. A total of 52 client-owned dogs, comprising 38 males and 14 females, were included. Among these, 24 dogs (46.15%) were classified as healthy controls and 28 dogs (53.85%) were part of DCM group. On breed-wise prevalence, it was reported that Labrador Retriever breeds showed a higher incidence of DCM than the others. The comparative studies of echocardiographic parameters showed that DCM-affected dogs had significantly higher values in left ventricular long axis length at -end diastole (LVLdA4C) and -end systole (LVLsA4C), end diastolic volume (EDV), end systolic volume (ESV), left atrium (LA)/aorta diameter (Ao) ratio, left ventricular internal dimension at systole (LVIDs), and end point septal separation (EPSS), as well as significantly lower values in left ventricular contractility indices such as fractional shortening (FS) and ejection fraction (EF) compared to healthy dogs. Also, receiver operating characteristic curves were made to determine the optimal cut-off points for each echocardiographic parameter with specificity and sensitivity for diagnosing DCM. Significant areas under the curve were observed for parameters such as LVIDs, EF, FS, LA/Ao, EPSS, LVLdA4C, LVLsA4C, left ventricular EDV, left ventricular ESV, and ESV for DCM-affected dogs. This cut-off value can be used as an early diagnosis of DCM through echocardiography, facilitating timely clinical interventions and management strategies for improved quality of life in dogs.
Keywords: Cut-off value Dilated cardiomyopathy Dog Echocardiography Healthy	

© 2024 Urmia University. All rights reserved.

Introduction

Cardiac disease is a critical global health issue affecting animals; particularly domestic dogs are more vulnerable.^{1,2} The overall prevalence of both acquired and congenital cardiac diseases in dogs is estimated to be nearly 11.00% of the total dog population, making them a significant health concern.³ Extensive research has been conducted worldwide to understand cardiac illnesses in dogs. But there is a notable dearth of information in India. This knowledge gap stems from a lack of awareness and information among dog owners, as well as inadequate diagnostic facilities. As a result, the timely detection and proper management of canine cardiac disorders have been hindered; leading to their unfortunate negligence.⁴ Current

veterinary practice has a skewed interest in cardiac disease diagnosis and management, being aptly supported by modern diagnostic tests such as electrocardiography, cardiac biomarkers, and radiography. Additionally, echocardiography has been used as a safe, non-invasive, and gold standard imaging modality to diagnose the morphological and physiological status of the heart in various dog breeds.^{5,6}

The alternation in structural and functional remodeling of myocardial tissue leads to cardiomyopathies, which may be subdivided into dilated cardiomyopathy (DCM), hypertrophic cardiomyopathy, and arrhythmogenic cardiomyopathies.⁷ However, DCM is the most common cardiomyopathy in dogs, leading to myocardial systolic dysfunction, being characterized by cardiomegaly.^{8,9}

*Correspondence:

Pritish Rath. MVSc, PhD Scholar

Department of Veterinary Surgery and Radiology, Faculty of Veterinary and Animal Sciences, West Bengal University of Animal and Fishery Sciences, Kolkata, India

E-mail: pritish094@gmail.com



This work is licensed under a Creative Commons Attribution-NonCommercial-ShareAlike 4.0 International (CC BY-NC-SA 4.0) which allows users to read, copy, distribute and make derivative works for non-commercial purposes from the material, as long as the author of the original work is cited properly.

The etiological factors behind each of these cardiomyopathies are multi-factorial and complex, which can be both genetic and acquired in origin. Previously, different echocardiography studies have been established in healthy dogs, measuring the normal reference value of the dimensions of cardiac chamber and wall thickness correlated with body weight.¹⁰ However, there is very limited information regarding the comparative assessment of healthy and DCM dogs and the optimal cut-off value to declare the DCM. Therefore, the aim of our study was to establish mean values of different echocardiographic parameters along with corresponding reference intervals (RIs) in both healthy and DCM dogs, and furthermore, the accuracy in terms of area under the curve (AUC) and optimal cut-off values with sensitivity and specificity for each echocardiographic parameter were evaluated through the receiver operating characteristic (ROC) curve to differentiate DCM from healthy control dogs.

Materials and Methods

The present study was carried out during the period from November 2018 to April 2020 in Department of Veterinary Surgery and Radiology and Teaching Veterinary Clinical Complex, Odisha University of Agriculture and Technology, Odisha, India. The study included a total of 52 dogs, aged between 2 to 12 years, encompassing various breeds such as Labrador Retriever, German Shepherd, Spitz, Saint Bernard, Cocker Spaniel, Pug, and Doberman Pinscher. The study encompassed both genders and a range of body weights. Prior to echocardiography, written consent was obtained from dog owners, and a routine cardiac health checkup, including auscultation, radiography, and an electrocardiogram, was performed on all animals. Based on the recommendations of the American Society of Echocardiography, real-time B-mode (2D) and M-mode echocardiograms have been recorded and examined.¹¹ Following the published recommendations, complete right parasternal trans-thoracic echocardiographic studies were performed, including a long axis 4C (4-chambered) view and a short axis view at the levels of papillary muscles, mitral valve, and aortic valve.¹¹ The GE Logiq F8 Expert (GE Healthcare, Chicago, USA) ultrasound machine with a multi-frequency cardiac probe (3.00 to 4.00 MHz) and a micro-convex probe (4.00 to 11.00 MHz) was employed for echocardiographic examination. The M-mode echocardiographic measurements were recorded in the short axis at the level of papillary muscles, including left ventricle-inter-ventricular septal thickness at diastole and systole, left ventricular internal dimension at diastole (LVIDd) and systole (LVIDs), and left ventricular posterior wall dimensions at diastole and systole.¹⁰ From the aforementioned echocardiographic measurements, parameters like end systolic volume (ESV), end diastolic

volume (EDV), fractional shortening (FS), and ejection fraction (EF) were calculated based upon formulas reported earlier by Gugjoo *et al.*, and Saini *et al.*^{10,12} The left ventricular volume measurements were assessed using the modified Simpson's disc method in the right parasternal long-axis 4C view to measure the left ventricular long axis length at -end diastole (LVLdA4C) and -end systole (LVLsA4C), left ventricular end-diastolic volume (LVEDV), and end-systolic volume (LVESV).¹³ Furthermore, the end point septal separation (EPSS) dimension in M-mode was measured from the distance between the inter-ventricular septum and maximal opening of the mitral valve leaflet.¹⁴ The left atrial dimensions were measured from a short axis view at the level of aorta, resembling the Mercedes-Benz logo, and the left atrium (LA), aorta diameter (Ao), and LA/Ao ratio were recorded from this view.¹⁰

Twenty-four adult dogs of different breeds, ages, sexes, and body weights showing normal clinico-physiological signs (electrocardiogram and thoracic radiograph) in a general health check-up were selected as the healthy control group. Twenty-eight adult dogs of either sex, varying age, breed, and body weight showed clinical signs and a concurrent history of prolonged inappetence, chronic cough, dyspnea, weight loss, abdominal distension, exercise intolerance, syncope, and cyanosis, which were cardinal signs of cardiac insufficiency. They were subjected to an echocardiographic evaluation and diagnosed as DCM suffering dogs, being categorized into the DCM group.

Statistical analysis. The data obtained from the formation of groups were organized and categorized using Microsoft Excel (version 16.0; Microsoft Corp., Redmond, USA). Descriptive statistics including mean, standard error (SE), and 95.00% confidence interval or reference interval (RI) were calculated. Receiver operating characteristic curves were constructed to evaluate the AUC, determine optimal cut-off points, and assess specificity and sensitivity for distinct echocardiographic parameters in DCM and healthy control groups. For hypothesis testing, significance levels of $p < 0.01$ and $p < 0.05$ were considered, and the results were analyzed accordingly. The statistical analysis was performed using SPSS Software (version 29.0; IBM Corp., Armonk, USA).

Results

In total, fifty-two client-owned dogs of both sexes (38 males and 14 females) of different breeds, age ranging from 2 to 12 years and body weight ranging from 5.00 to 56.00 kg, were included in our study conducted over a period of 1.50 years. The mean age and body weight of both groups were recorded in Table 1. It showed that dogs diagnosed with DCM had an average age of 6.50 years and an average body weight of 25.00 kg. On gender-wise analysis, it was found that there was a higher prevalence of

DCM in male dogs compared to the female ones. Labrador Retriever breed dogs were highly affected by DCM among various breeds of dogs.

The mean and corresponding RIs of various echocardiographic measurements of healthy and DCM-diagnosed dogs are shown in Table 2. It was found that dogs affected by DCM exhibited significantly higher values of echocardiographic parameters such as LVLdA4C, LVLsA4C, EDV, ESV, LA, LA/Ao, LVIDs, and EPSS compared to the healthy control dogs ($p < 0.05$ and $p < 0.01$). However, left ventricular contractibility indices such as FS and EF in DCM-affected dogs were found to be significantly lower compared to the healthy controls ($p < 0.01$; Fig. 1).

Table 1. Demographics data of canine patients including 24 healthy and 28 dilated cardiomyopathy cases.

Parameters	Healthy	Dilated cardiomyopathy
Number of cases	24 (46.15%)	28 (53.85%)
Age (years)	5.58 ± 0.90	6.46 ± 0.68
Body weight (kg)	23.52 ± 3.01	25.07 ± 4.65
Gender		
Male	16 (66.67%)	22 (78.57%)
Female	8 (33.33%)	6 (21.43%)
Breeds		
Labrador Retriever	10 (41.67%)	12 (42.85%)
German Shepherd	4 (16.67%)	4 (14.29%)
Spitz	2 (8.33%)	4 (14.29%)
Saint Bernard	2 (8.33%)	2 (7.14%)
Cocker Spaniel	2 (8.33%)	2 (7.14%)
Pug	2 (8.33%)	4 (14.29%)
Doberman Pinscher	2 (8.33%)	0 (0.00%)

The ROC curve analysis was used to measure the AUC, establish optimal cut-off points, and evaluate specificity and sensitivity for different echocardiographic parameters in DCM and healthy control groups, as shown in Table 3. It was observed that parameters such as LVIDs, EF, FS, LA/Ao, EPSS, LVLdA4C, LVLsA4C, LVEDV, LVESV, and ESV showed significant AUC values ($p < 0.05$, and $p < 0.01$).

Discussion

Dilated cardiomyopathy is the most common cardiac disorder, representing 10.00% of all cardiac diseases in dogs.¹⁵ However, the ideal gold standard test for diagnosing DCM is a trans-thoracic echocardiography, being a real-time assessment of cardiac chambers, muscles, and valves. The present study was carried out to find out the prevalence of DCM in dogs and to standardize the different echocardiographic parameters with corresponding RIs to distinguish between healthy and DCM-diagnosed dogs. In the current study, a total of 52 client-owned dogs of different ages, sexes, and body weights were incorporated; out of them, 28 (53.85%) were diagnosed with DCM, aligning closely with the prevalence reported in previous studies.¹⁶⁻¹⁸ The mean age-wise prevalence of DCM in the dogs was found to be 6.46 ± 0.68 years. These findings align with the conclusions of several authors who observed that the dogs diagnosed with DCM fell within the age range of 4 to 8 years.¹⁶⁻¹⁸ The mean body weight of dogs diagnosed with DCM was found to be 25.07 ± 4.65 kg.

Table 2. Different echocardiographic measurements as mean ± SE (95.00% confidence interval) of 24 healthy and 28 DCM affected dogs.

Parameters	Healthy	Dilated cardiomyopathy
LVEDV (mL)	33.04 ± 4.36 (23.43 - 42.64)	79.72 ± 19.67 (35.21 - 124.22)
LVESV (mL)	13.38 ± 2.22 (8.49 - 18.27)	45.58 ± 12.65 (16.98 - 74.19)
LVLdA4C (cm)	5.39 ± 0.28 (4.77 - 6.00)	6.57 ± 0.48 (5.49 - 7.65)*
LVLsA4C (cm)	4.04 ± 0.26 (3.46 - 4.61)	5.35 ± 0.50 (4.23 - 6.47)*
EDV (mL)	53.96 ± 4.74 (43.40 - 64.52)	120.77 ± 24.78 (66.22 - 175.31)*
ESV (mL)	18.16 ± 1.98 (13.75 - 22.57)	87.22 ± 19.52 (44.25 - 130.19)**
SV (mL)	19.87 ± 3.19 (12.85 - 26.90)	37.67 ± 9.96 (14.71 - 60.64)
LA (cm)	2.34 ± 0.14 (2.01 - 2.67)	3.30 ± 0.36 (2.51 - 4.10)*
Ao (cm)	1.97 ± 0.08 (1.79 - 2.15)	2.00 ± 0.09 (1.80 - 2.20)
LA/Ao (cm)	1.20 ± 0.08 (1.01 - 1.39)	1.65 ± 0.15 (1.32 - 1.98)*
IVSd (cm)	0.78 ± 0.06 (0.65 - 0.91)	0.86 ± 0.06 (0.73 - 0.99)
LVIDd (cm)	3.45 ± 0.14 (3.14 - 3.76)	4.44 ± 0.46 (3.45 - 5.43)
LVPWd (cm)	0.96 ± 0.09 (0.76 - 1.15)	1.13 ± 0.11 (0.89 - 1.36)
IVSs (cm)	1.19 ± 0.06 (1.06 - 1.33)	1.07 ± 0.07 (0.91 - 1.23)
LVIDs (cm)	2.17 ± 0.13 (1.88 - 2.47)	3.80 ± 0.43 (2.86 - 4.74)**
LVPWs (cm)	2.43 ± 1.02 (0.19 - 4.67)	1.52 ± 0.30 (0.88 - 2.17)
EF (%)	68.28 ± 2.76 (62.21 - 74.36)	33.86 ± 4.16 (24.87 - 42.84)**
FS (%)	37.95 ± 2.42 (32.64 - 43.27)	15.40 ± 2.39 (10.23 - 20.57)**
EPSS (cm)	0.43 ± 0.06 (0.30 - 0.57)	1.48 ± 0.24 (0.92 - 2.04)**

LVEDV: Left ventricular end-diastolic volume; LVESV: Left ventricular end-systolic volume; LVLdA4C: Left ventricular long axis length at end diastole; LVLsA4C: Left ventricular long axis length at end systole; EDV: End diastolic volume; ESV: End systolic volume; SV: Stroke volume; LA: Left atrium; Ao: Aorta diameter; IVSd: Left ventricle-inter-ventricular septal thickness at diastole; LVIDd: Left ventricular internal dimension at diastole; LVPWd: Left ventricular posterior wall dimensions at diastole; LVIDs: Left ventricle-inter-ventricular septal thickness at systole; LVIDs: Left ventricular internal dimension at systole; LVPWs: left ventricular posterior wall dimensions at systole; EF: Ejection fraction FS: Fractional shortening; EPSS: End point septal separation.

* Significant at $p < 0.05$; and ** Significant at $p < 0.01$.

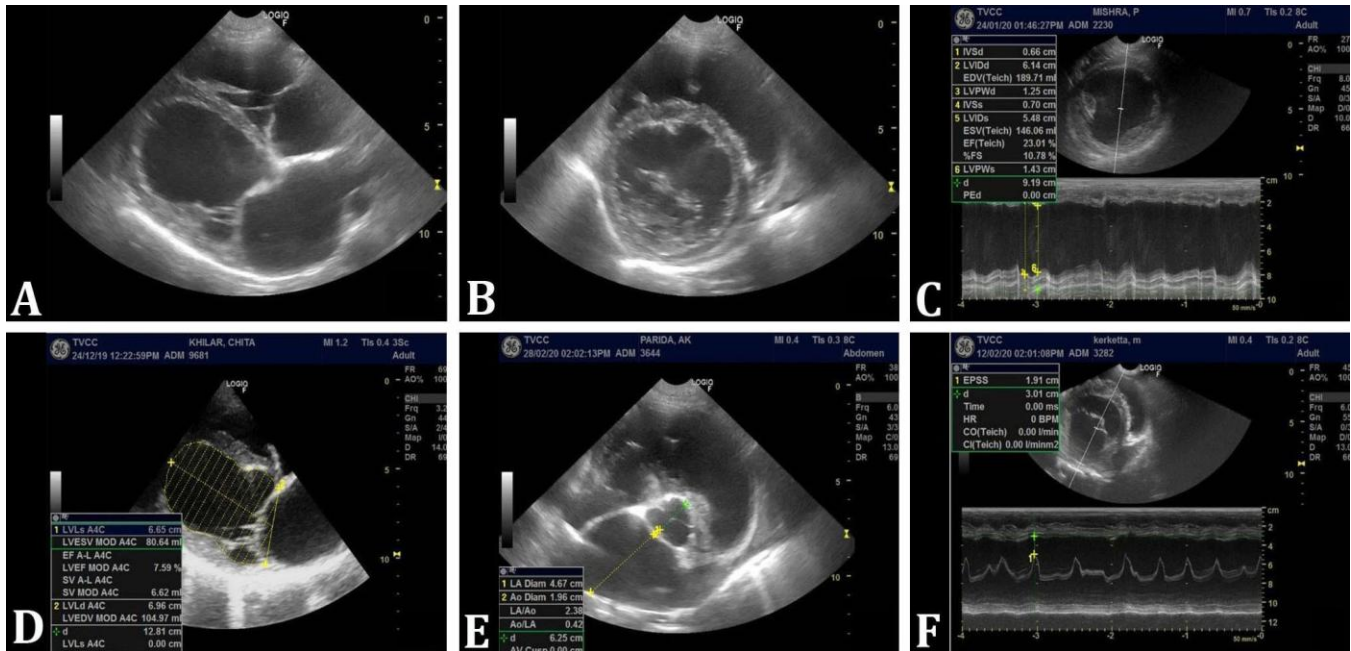


Fig. 1. B-mode and M-mode echocardiograms (right parasternal views) of dilated cardiomyopathy-affected dogs. **A)** Long axis (4C) view; **B)** Short axis view; **C)** M-mode echocardiographic parameters in short axis papillary muscle view; **D)** Left ventricular volume measurements using Simpson's disc method in long axis; **E)** measurement of left atrium (LA), aorta diameter (Ao), LA/Ao in short axis aorta level view; **F)** Measurement of end point septal separation (EPSS) in short axis mitral valve level view.

Table 3. Receiver operating characteristic curve analysis of echocardiographic parameters between healthy and DCM-affected dogs.

Parameters	AUC (%)	Sensitivity (%)	Specificity (%)	Cut-off value	p-value
LVEDV (mL)	74.70	70.00	87.50	43.475	0.037*
LVESV (mL)	73.40	70.00	81.20	16.825	0.048*
LVLdA4C (cm)	75.30	80.00	68.70	5.795	0.033*
LVLsA4C (cm)	80.90	80.00	68.70	4.530	0.009**
EDV (mL)	72.20	75.00	46.70	48.145	0.051
ESV (mL)	84.40	75.00	93.30	25.110	0.002**
SV (mL)	69.80	66.70	75.00	24.360	0.107
LA (cm)	73.70	72.70	66.70	2.400	0.074
Ao (cm)	49.00	72.70	44.40	1.910	0.939
LA/Ao (cm)	77.30	72.70	77.80	1.375	0.040*
IVSd (cm)	56.50	57.10	58.30	0.800	0.572
LVIDd (cm)	59.50	57.10	50.00	3.545	0.411
LVPWd (cm)	66.10	71.40	58.30	0.920	0.165
IVSs (cm)	65.80	83.30	57.10	1.020	0.173
LVIDs (cm)	78.90	71.40	91.70	2.620	0.013*
LVPWs (cm)	61.30	66.70	57.10	1.330	0.328
EF (%)	99.70	100.00	92.90	53.695	0.000**
FS (%)	99.70	100.00	92.90	26.600	0.000**
EPSS (cm)	88.30	77.80	100.00	0.865	0.006**

AUC: Area under the curve; LVEDV: Left ventricular end-diastolic volume; LVESV: Left ventricular end-systolic volume; LVLdA4C: Left ventricular long axis length at end diastole; LVLsA4C: Left ventricular long axis length at end systole; EDV: End diastolic volume; ESV: End systolic volume; SV: Stroke volume; LA: Left atrium; Ao: Aorta diameter; IVSd: Left ventricle-inter-ventricular septal thickness at diastole; LVIDd: Left ventricular internal dimension at diastole; LVPWd: Left ventricular posterior wall dimensions at diastole; IVSs: Left ventricle-inter-ventricular septal thickness at systole; LVIDs: Left ventricular internal dimension at systole; LVPWs: left ventricular posterior wall dimensions at systole; EF: Ejection fraction FS: Fractional shortening; EPSS: End point septal separation.

* Significant at $p < 0.05$; and** Significant at $p < 0.01$.

A similar study reported that 95 percent of dogs diagnosed with DCM weighed more than 15.00 kg.¹⁹ In the sex-wise prevalence of DCM, it was found that 78.57% of affected dogs were males. This finding is supported by Thirunavukkarasu, Parmar *et al.*, and Vishnurahav *et al.*, which observed a higher incidence of DCM in male dogs than female ones.^{16,18,20} However, another study reported that there was no sex predisposition in dogs affected by DCM.^{21,22} The preference of pet owners for male dogs over female dogs in the study may be one of the potential contributing factors; male dogs had a greater incidence of DCM in the current study. In breed-wise prevalence of DCM among different breeds, it was found that DCM was more prevalent in Labrador Retrievers (42.85%), followed by German Shepherds (14.29%), and Spitzes (14.29%). Meurs *et al.*, Wess *et al.*, Tidholm and Jönsson, Vollmar *et al.*, El Sharkawy *et al.*, and Dambach *et al.* have similarly reported the breed predisposition of dogs affected by DCM, such as Cocker Spaniels, Boxers, Dobermans, Newfoundlands, Irish Wolfhounds, Great Danes, and Portuguese Water Dogs.²¹⁻²⁶ The higher prevalence of Labrador Retrievers in both healthy and DCM-affected dogs in this study is attributed to the breed's popularity among dog owners and the stocky population in the locality. Moreover, the incidence of DCM in small-breed dogs, such as the Spitz, in this study was unusual and uncommon, which may be due to rampant inbreeding and failure to keep track of the dog's pedigree by an unlicensed dog breeder. It was reported that an autosomal dominant mode of inheritance was suspected in the majority of familial DCM; however, another author postulated various modes of inheritance in dogs affected by DCM, including autosomal recessive, autosomal dominant, mitochondrial, and X-linked modes.^{27,28}

The mean echocardiographic measurements of healthy controls along with their corresponding RIs are shown in Table 2. In our study, the mean and RIs of echocardiographic measurements of healthy control dogs were closely aligned with previous reports of healthy dogs of different breeds with similar body weights.^{10,12,14} However, there will be increased or decreased echocardiographic mean and RI values in DCM-affected dogs compared to healthy ones. The etiology of DCM typically remains unknown or has a genetic origin. Echocardiography plays a key role in diagnosing DCM with impaired myocardial contraction and left ventricular systolic dysfunction, accompanied by progressive chamber enlargement.⁹ In our study, B-mode real-time echocardiography showed that the majority of DCM-affected dogs exhibited an enlarged left ventricle, as well as ventricles wall hypo-kinesis, leading to a change in echocardiographic dimensions compared to the healthy controls. In M-mode, LVIDs were significantly higher in DCM-affected dogs (RI: 2.86 - 4.74 cm) compared to the healthy ones. In DCM, volume over-load results in an increase in preload, causing chamber dilation in the left

ventricle, leading to systolic myocardial failure. Similar findings have been reported, indicating an increase in left ventricular internal dimensions in systole and diastole in DCM-affected dogs.²⁹⁻³¹ The left ventricular volume parameters in DCM-affected dogs, such as ESV (RI: 44.25 - 130.19 mL) and EDV (RI: 66.22 - 175.31 mL), showed significantly higher values compared to the healthy ones. Left ventricular volume parameters, such as ESV and EDV values were estimated from LVIDs and LVIDd parameters.^{10,12} Increased dimensions of the left ventricle during both systole and diastole in DCM result in increased ESV and EDV measurements in DCM. These similar findings were reported in previous studies.^{30,31} The long axis lengths of the left ventricle on systole and diastole measured by Simpson's disc method in DCM-affected dogs (LVLsA4C (RI): 4.23 - 6.47 cm and LVLdA4C (RI): 5.49 - 7.65 cm) were significantly higher than healthy ones. As the volume overloads in DCM, there will be an increase in left ventricle longitudinal long axis length in systole and diastole. According to the European Society of Veterinary Cardiology, the screening of DCM was based on a geometric alternation of cardiac shape involving measurement of LVLd using the Simpson's disc method and LVIDd using M-mode echocardiography. Similar findings showed that an increase in the long axis length of the left ventricle coupled with an increased left ventricular internal dimension imparts a globular or rounded appearance of the heart, resulting in decreased ejection of blood into the systemic aorta, leading to the systolic myocardial failure.³² The left ventricular contractility indices in DCM-affected dogs, such as FS (RI: 10.23 - 20.57%) and EF (RI: 24.87 - 42.84%), were significantly lower than healthy ones. These findings align with the results reported in previous studies.^{9,31} In the current study, decreased values of FS and EF suggested impaired systolic functions and inadequate contractility of the ventricle. It was observed that FS < 25.00%, and EF < 45.00% were clinically used for measuring left ventricle systolic function.^{33,34} The LA (RI: 2.51 - 4.10 cm) and LA/Ao ratio (RI: 1.32 - 1.98 cm) in DCM-affected dogs showed significantly higher values compared to the healthy ones. Similar findings were reported a significant increase in LA and LA/Ao ratio in clinical DCM cases in comparison with apparently healthy dogs.²⁹⁻³¹ The increase in left atrial dimensions results in the presence of left atrial enlargement (LAE). A study showed that for assessment of LAE, the LA/Ao measurements are preferred over LA measurements, as Ao (aorta) serves as an internal reference, being unlikely enlarged as a result of common cardiac problems.³⁵ The LA/Ao is considered normal when it is < 1.60; the LAE is mild when LA/Ao is between ≥ 1.60 and < 1.80; moderate if LA/Ao is between ≥ 1.80 and < 2, and severe if LA/Ao is ≥ 2 .³⁶ The shortest distance between the E point of mitral valve and ventricular septum is called EPSS. The EPSS values (RI:

0.92 - 2.04 cm) of DCM- affected dogs showed significantly higher values compared to the healthy ones. The EPSS is a qualitative indicator of left ventricular function, being a clinical indicator of DCM. Due to the high-volume overload in DCM, there was a reduced blood flow from LA to left ventricle, which led to an increased EPSS value. Similar findings were reported, including a significant increase in EPSS in DCM-affected dogs.³¹

The ROC curves were analyzed to measure the AUC values and optimal cut-off points of different echocardiographic parameters, along with their sensitivity and specificity to differentiate DCM from healthy controls. It showed that there were significant AUC values in LVIDs, EF, FS, LA/Ao, EPSS, LVLdA4C, LVLsA4C, LVEDV, LVESV, and ESV. The optimal cutoff values with sensitivity and specificity to diagnose DCM were as follows: LVIDs > 2.62 cm (sensitivity: 71.40% and specificity: 91.70%), EF < 53.69% (sensitivity: 100% and specificity: 92.90%), FS < 26.60% (sensitivity: 100% and specificity: 92.90%), LA/Ao > 1.37 cm (sensitivity: 72.80%, and specificity: 77.80%), EPSS > 0.86 cm (sensitivity: 77.80% and specificity: 100%), LVLdA4C > 5.79 cm (sensitivity: 80.00% and specificity: 68.70%), LVLsA4C > 4.53 cm (sensitivity: 80.00% and specificity: 68.70%), LVEDV > 43.47 mL (sensitivity: 70.00% and specificity: 87.50%), LVESV > 16.82 mL (sensitivity: 70.00% and specificity: 81.20%), and ESV > 25.11 mL (sensitivity: 75.00% and specificity: 93.30%).

The present study aimed to find out the prevalence of DCM in dogs, as well as a comparative assessment of different echocardiographic parameters between healthy and DCM-diagnosed dogs. Demographically, it was found that Labrador Retriever dogs showed a higher predisposition to DCM. Furthermore, male dogs had a higher prevalence of DCM compared to the female ones. The mean age of occurrence of DCM was found to be 6.50 years. On echocardiography, it was found that DCM-affected dogs showed significantly higher LVLdA4C, LVLsA4C, EDV, ESV, LA, LA/Ao, LVIDs, and EPSS parameters, and lower EF and FS parameters than healthy ones. This comparative evaluation provides early detection and an accurate assessment of cardiac health in dogs. Furthermore, there were significant AUC values for LVIDs, EF, FS, LA/Ao, EPSS, LVLdA4C, LVLsA4C, LVEDV, LVESV, and ESV parameters, which helped identify the optimal cut-off values with specificity and sensitivity for DCM-affected dogs to be differentiated from healthy ones. The optimal cut-off value of DCM can be used for cardiac forecasting, which encourages general practitioners to use echocardiography in their daily routine practice. Despite this, there were some limitations in this study, namely that the sample size was too small for a reference range. In addition to this, the data obtained from the study population were not breed-specific; there may be variations in the reference range and cut-off value for a specific breed to be diagnosed as DCM. So, future studies

may be needed to obtain a large sample size and breed-specific reference range with suitable cut-off values to detect DCM earlier in its course and provide timely clinical interventions, as well as management strategies enhancing the quality of life in dogs.

Acknowledgments

The authors acknowledge the kind support of the Dean, College of Veterinary and Animal Sciences, and Vice-Chancellor of Odisha University of Agriculture and Technology, Bhubaneswar, India.

Conflict of interest

The authors declare no conflict of interest.

References

- Roth GA, Mensah GA, Johnson CO, et al. Global burden of cardiovascular diseases and risk factors, 1990-2019: update from the GBD 2019 study *J Am Coll Cardiol* 2020; 76(25): 2982-3021.
- Gaar-Humphreys KR, Spanjersberg TCF, Santarelli G, et al. Genetic basis of dilated cardiomyopathy in dogs and its potential as a bidirectional model. *Animals (Basel)* 2022; 12(13): 1679. doi: 10.3390/ani12131679.
- Aherne M. Cardiac disease and screening in breeding dogs. *Vet Clin North Am Small Anim Pract* 2023; 53(5): 985-1012.
- Devi S, Jani RG, Karlette Anne F, et al. Study on Clinical symptoms in canine cardiac diseases. *Vet World* 2009; 2(8): 307-309.
- Subramanian B, Arthanari K, Ramesh G, et al. Electrocardiographic and echocardiographic parameters in Chippiparai dog. *Int J Livest Res* 2019; 9(4): 49-57.
- Suh S, Lu TL, Choi R, et al. Echocardiographic features in canine myxomatous mitral valve disease: an animal model for human mitral valve prolapse. In: S. Firstenberg M, Lakshmanadoss U (Eds). *Advanced concepts in endocarditis - 2021*. London, UK: Intech Open 2021; 31-60.
- McNally EM, Mestroni L. Dilated cardiomyopathy: genetic determinants and mechanisms. *Circ Res* 2017; 121(7): 731-748.
- Sidhu S, Uppal SK, Saini N, et al. Diagnosis of cardiomyopathies in dogs - a clinical study of twenty three patients. *Intas Polivet* 2018; 19(1): 121-125.
- Bonagura JD, Visser LC. Echocardiographic assessment of dilated cardiomyopathy in dogs. *J Vet Cardiol* 2022; 40: 15-50.
- Gugjoo MB, Hoque M, Saxena AC, et al. Reference values of M-mode echocardiographic parameters and indices in conscious Labrador Retriever dogs. *Iran J Vet Res* 2014; 15(4): 341-346.

11. Thomas WP, Gaber CE, Jacobs GJ, et al. Recommendations for standards in transthoracic two-dimensional echocardiography in the dog and cat. *J Vet Intern Med* 1993; 7(4): 247-252.
12. Saini N, Uppal SK, Randhawa CS. Echocardiographic parameters and indices in healthy Labrador retriever dogs. *Isr J Vet Med* 2017; 72(4): 28-32.
13. Wess G, Bauer A, Kopp A. Echocardiographic reference intervals for volumetric measurements of the left ventricle using the Simpson's method of discs in 1331 dogs. *J Vet Intern Med* 2021; 35(2): 724-738.
14. Bodh D, Hoque M, Saxena AC. Echocardiographic study of healthy Indian Spitz dogs with normal reference ranges for the breed. *Vet World* 2019; 12(6): 740-747.
15. Simpson S, Edwards J, Ferguson-Mignan TF, et al. Genetics of human and canine dilated cardiomyopathy. *Int J Genomics* 2015; 2015: 204823. doi: 10.1155/2015/204823.
16. Thirunavukkarasu P. Prevalence of canine acquired heart diseases in Chennai, India. *Int J Livest Res* 2019; 9(3): 331-339.
17. Sagar RS, Narayana Bhat M, Ansar Kamran C, et al. Occurrence of canine cardiac diseases in Bangalore. *J Entomol Zool Stud* 2020; 8(6): 824-829.
18. Parmar SM, Patel MD, Vala JA, et al. Clinical features and incidence of dilated cardiomyopathy in dogs of South Gujarat, India. *Indian J Anim Health* 2022; 61(2): 329-334.
19. Martin MW, Stafford Johnson MJ, Celona B. Canine dilated cardiomyopathy: a retrospective study of signalment, presentation and clinical findings in 369 cases. *J Small Anim Pract* 2009; 50(1): 23-29.
20. Vishnurahav RB, Ajithkumar S, Usha NP, et al. Occurrence of cardiac diseases in dogs: a retrospective study. *J Entomol Zool Stud* 2018; 6(4): 1901-1903.
21. Meurs KM, Hendrix KP, Norgard MM. Molecular evaluation of five cardiac genes in Doberman Pinschers with dilated cardiomyopathy. *Am J Vet Res* 2008; 69(8): 1050-1053.
22. Wess G, Schulze A, Butz V, et al. Prevalence of dilated cardiomyopathy in Doberman Pinschers in various age groups. *J Vet Intern Med* 2010; 24(3): 533-538.
23. Tidholm A, Jönsson L. Dilated cardiomyopathy in the Newfoundland: a study of 37 cases (1983-1994). *J Am Anim Hosp Assoc* 1996; 32(6): 465-470.
24. Vollmar C, Vollmar A, Keene BW, et al. Dilated cardiomyopathy in 151 Irish Wolfhounds: characteristic clinical findings, life expectancy and causes of death. *Vet J* 2019; 245: 15-21.
25. El Sharkawy S, Dukes-McEwan J, Abdelrahman H, et al. Long-term outcome and troponin I concentrations in Great Danes screened for dilated cardiomyopathy: an observational retrospective epidemiological study. *J Vet Cardiol* 2023; 47: 1-13.
26. Dambach DM, Lannon A, Sleeper MM, et al. Familial dilated cardiomyopathy of young Portuguese water dogs. *J Vet Intern Med* 1999; 13(1): 65-71.
27. Ortiz-Lopez R, Schultz KR, Towbin JA. Genetic aspects of dilated cardiomyopathy. *Prog Pediatr Cardiol* 1996; 6(1): 71-82.
28. McEwan JD. Canine dilated cardiomyopathy 2. pathophysiology and treatment. In *Practice* 2000; 22(10): 620-628.
29. Saini N. Diagnosis and therapeutic management of myocardial and valvular diseases in dogs. Ph.D. Thesis, Guru Angad Dev Veterinary and Animal Sciences University. Punjab, India: 2014.
30. Jeyaraja K, Arun A, Hamsa YS, et al. Diagnostic evaluation of dilated cardiomyopathy in Labrador Retrievers. *Int J Adv Res* 2015; 3(12): 628-655.
31. Rault-Vaisse A, Vulpe V, Baisan RA. Echocardiographic evaluation in dogs with dilated cardiomyopathy. *Med Vet Timisoara (Romania)* 2020; 53(2): 64-72.
32. Wess G, Domenech O, Dukes-McEwan J, et al. European Society of Veterinary Cardiology screening guidelines for dilated cardiomyopathy in Doberman Pinschers. *J Vet Cardiol* 2017; 19(5): 405-415.
33. Vörös K, Hetey C, Reiczigel J, et al. M-mode and two-dimensional echocardiographic reference values for three Hungarian dog breeds: Hungarian Vizsla, Mudi and Hungarian Greyhound. *Acta Vet Hung* 2009; 57(2): 217-227.
34. Cornell CC, Kittleson MD, Della Torre P, et al. Allometric scaling of M-Mode cardiac measurements in normal adult dogs. *J Vet Intern Med* 2004; 18(3): 311-321.
35. Boon JA. *Veterinary echocardiography*. 2nd ed. New Jersey, USA: Wiley, Blackwell 2011; 172-185.
36. Rishniw M, Erb HN. Evaluation of four 2-dimensional echocardiographic methods of assessing left atrial size in dogs. *J Vet Intern Med* 2000; 14(4): 429-435.