

Histopathological evaluation of the viability of auto-transplanted ovary following vitrification-thawing process in rabbit as an animal model

Ensiye Sajadian Jaghargh¹, Mohammad Taghi Vajed Ebrahimi², Armin Attaranzadeh³, Abbas Parham², Ahmad Reza Mohammadnia^{1*}

¹ Department of Clinical Sciences, Faculty of Veterinary Medicine, Ferdowsi University of Mashhad, Mashhad, Iran; ² Department of Basic Sciences, Faculty of Veterinary Medicine, Ferdowsi University of Mashhad, Mashhad, Iran; ³ Life Science Research, Stanford University, Stanford, United States of America.

Article Info

Article history:

Received: 30 March 2024

Accepted: 29 June 2024

Available online: 15 October 2024

Keywords:

Autologous transplantation

Ovarian tissue

Rabbit

Vitrification

Abstract

Cryopreservation and re-transplantation of ovarian tissue is a relatively new technique to preserve fertility. This study evaluated the preservation of ovarian follicles after the vitrification-thawing procedure by implanting ovarian fragments into the gluteus muscle of rabbit. Bilateral ovariectomy was performed on each rabbit. The cortices were separated from the medullae of ovaries and divided into four fragments. One fresh cortical fragment was used as a control, fixed in 10.00% formalin. Three fragments underwent vitrification-thawing for two weeks. Two of these vitrified-thawed fragments were auto-transplanted into separate locations within the opened gluteus muscle, while the final fragment was fixed in 10.00% formalin. Eight weeks after re-implantation, biopsies were collected from the ovarian fragments and fixed in 10.00% formalin. The numbers and areas (μm^2) of morphologically normal follicles were evaluated on sections stained with Hematoxylin and Eosin through light microscopy. The follicular morphology in the ovarian fragments immediately after vitrification-thawing remained similar to that of the fresh ovary. The number of morphologically intact follicles was significantly lower in the ovarian fragments eight weeks after re-implantation than fresh ovary and ovarian tissue fragments after vitrification-thawing procedure. However, follicular development to the antral stage was observed in all samples eight weeks after re-implantation. There was no statistical difference in the areas (μm^2) of primordial, primary, pre-antral, and antral follicles in the ovarian fragments before cryopreservation, immediately after vitrification-thawing, and following re-implantation procedures. Auto-transplantation of ovarian tissue into the gluteus muscle of rabbits could be a viable approach for preserving ovarian follicles after vitrification-thawing procedure.

© 2024 Urmia University. All rights reserved.

Introduction

Recent advances in oncological therapy, such as aggressive chemotherapy, radiotherapy, and bone marrow transplantation, have cured roughly 90.00% of female patients with cancer and saved the lives of 75.00% of these patients for up to 10 years.^{1,2} These treatments can be gonadotoxic, threaten fertility, and lead to pre-mature ovarian failure or pre-mature ovarian insufficiency.¹⁻³ Cryopreservation and re-transplantation of ovarian tissue is a new method to preserve fertility and restore the endocrine function of the ovary.¹⁻³ The recently developed cryopreservation procedure is effective in preserving ovarian tissue in humans and might be a valid option for

ovarian tissue cryopreservation in animals, especially for fertility preservation in endangered species or genetically superior domestic animals.⁴ Cryobanking of ovarian tissue can be done using one of three techniques including vitrification, slow-freezing (conventional method)³ and ultra-rapid freezing.⁵ In the vitrification method, ovarian pieces are exposed to high concentrations of cryoprotective agents to prevent the formation of ice crystals during rapid cooling in liquid nitrogen. Slow-freezing is an effective and simple method based on a controlled cooling rate (1.50 °C per min).^{3,5} Ultra-rapid freezing is faster than slow freezing. Unlike slow-freezing, this procedure does not require a programmable machine. It uses lower levels of cryoprotective agents than other methods, also.⁵ Slow-

*Correspondence:

Ahmad Reza Mohammadnia. DVM, PhD

Department of Clinical Sciences, Faculty of Veterinary Medicine, Ferdowsi University of Mashhad, Mashhad, Iran

E-mail: mohamadnia@um.ac.ir



This work is licensed under a Creative Commons Attribution-NonCommercial-ShareAlike 4.0 International (CC BY-NC-SA 4.0) which allows users to read, copy, distribute and make derivative works for non-commercial purposes from the material, as long as the author of the original work is cited properly.

freezing has been introduced as a standard method for ovarian cryobanking, but the use of vitrification is a valid option due to no crystallization and the amorphous state of liquids.^{1,3} Slow-freezing causes cellular damage by promoting ice crystal formation.⁶ Moreover, this procedure increases costs and decreases accessibility because of the required time and expensive equipment.⁷ The success of cryopreservation of oocytes and blastocysts in the vitrification procedure encourages the study of this procedure in ovarian tissue cryo-preservation.¹ It has been shown that follicular survival with vitrification is higher than slow-freezing in an ewe model.⁸ Also, no significant difference between the conventional methods *versus* vitrification has been recorded regarding follicular quality and endocrine activity.^{1,9} Although the viability of ovarian tissue and follicular developmental competence have already been investigated following vitrification of human ovaries,¹ the data on the efficacy of vitrification remain conflicting.^{1,2} Viability of ovarian tissue was evaluated by hormonal assay, histological study, vaginal cytology or ovarian tissue culture after re-implantation.^{1,10-12}

The main aim of this study was to investigate the effect of vitrification-thawing cycle on cortex pieces of ovarian tissue in rabbits. In this investigation, the viability of ovarian tissue was evaluated by histopathological assessment next to auto-transplantation into the gluteus muscle of rabbits.

Materials and Methods

Six healthy mature female mixed breed rabbits, aged 8 - 24 months, mean weight of 3.20 kg, were selected for this experiment. The animals were individually housed in large cages in the Animal Center of the Faculty of Veterinary Medicine, Ferdowsi University of Mashhad, Mashhad, Iran, and maintained under a 12-hr light-dark cycle at 22.00 - 25.00 °C. The rabbits were acclimatized to their housing environment for a week with *ad libitum* access to food and water. All procedures were approved by the Animal Ethics Committee of Ferdowsi University of Mashhad, Mashhad, Iran (IR.UM.REC.1400.335).

Animal procedures and experimental design.

Anesthesia and anti-bacterial prophylaxis were performed using intra-muscular (IM) cocktail of ketamine (50.00 mg kg⁻¹; Alfasan, Woerden, The Netherlands) and xylazine (5.00 mg kg⁻¹; Alfasan) and IM cefazolin (100 mg; Jaber Ebne Hayyan Pharmaceutical Co, Tehran, Iran).¹³ Pain was controlled in all rabbits using subcutaneous (SC) meloxicam (0.20 mg kg⁻¹, q24hr; Rooyan Darou, Tehran, Iran) for 2 days after surgery.¹⁴ Following surgical preparation, bilateral ovariectomy was done using midline approach.¹³ Immediately after surgery the cortices of excised ovaries were separated from the medullae and divided into four fragments using a sharp scalpel blade. One fresh cortex fragment was fixed in 10.00% formalin

and three others were frozen-thawed for 2 weeks. Following freeze-thaw cycle, one ovarian fragment was fixed in 10.00% formalin and the two others were auto-transplanted into the opened gluteus muscle. Biopsies from the ovary fragments were taken eight weeks after re-implantation following anesthesia by surgical incision, and excised ovaries were fixed in 10.00% formalin. All fixed samples were prepared for histological study.¹¹

Vitrification-thawing procedure. All chemicals used in the vitrification and thawing procedures were prepared from the company of Sigma-Aldrich Chemie, Steinheim, Germany. For the vitrification procedure, ovarian fragments were placed in vitrification solutions. The vitrification solutions were prepared as vitrification solution 1 supplemented with 75.00% ethylene glycol (EG) + 75.00% dimethylsulphoxide (DMSO) in 10.00% Ham's tissue culture medium (HAMS) as a handling medium for 25 min at room temperature (25.00°C), and vitrification solution 2 consisted of 20.00% EG + 20.00% DMSO + 0.50 mol L⁻¹ sucrose in 10.00% 4-(2-hydroxyethyl)-1-piperazineethanesulfonic acid (HEPES; 3.50 mL) for 15 min (25.00 °C). The ovarian fragments from each rabbit were placed in separate cryovials plunged into liquid nitrogen (- 196 °C) and stored until thawing.¹⁵ For the thawing process, 2 weeks after vitrification, the cryovials were held at room temperature for 20 min, then the ovary fragments were placed in thawing solution 1 (1.00 mol sucrose and 10.00% HEPES with HAMS as base media), thawing solution 2 (10.00% HEPES and 0.50 mol sucrose), and thawing solution 3 (10.00% HEPES and 0.25 mol sucrose) for 1, 5, and 10 min (25.00°C), respectively.¹⁶

Histopathological study. The specimens were fixed in 10.00% formalin, processed through routine paraffin embedding technique, cut at 5.00 µm and stained with Hematoxylin and Eosin.¹¹ The numbers and the areas (µm²) of morphologically normal follicles were evaluated by light microscopy (BX-71; Olympus, Tokyo, Japan) equipped with a computer-controlled digital camera and imaging software DP2-BSW (Olympus; 10 contiguous microscopic fields over the cortex biopsy at 400×). Follicles were classified according to Tavana *et al.*,¹⁰ as primordial (oocytes surrounded by one layer of flattened granulosa cells), primary (surrounded by one layer of cuboidal granulosa cells), pre-antral (with two or more layers of granulosa cells without an antrum), or antral (with an antral cavity). In order to avoid recounting of the same follicle, follicles were only analyzed when an oocyte nucleolus was present.

Statistical analysis. All data were initially checked for normality using the Kolmogorov-Smirnov test. Data were analyzed by SPSS Software (version 26.0; IBM Corp., Armonk, USA). The numbers of morphologically intact follicles were compared using the Friedman test and the statistical significance was assessed by repeated measure ANOVA. A *p*-value < 0.05 was considered significant.

Results

After surgery, the rabbits were monitored daily. None of the animals under study missed. No macroscopic evidence of surgical complications was observed in surgical sides. All re-implanted ovarian fragments into the gluteus muscle were recovered.

Histological study of the fresh fragment of ovarian tissue revealed the presence of stroma and follicles in different stages of development (Fig. 1A). The follicular morphology and development in all ovarian tissue fragments after the vitrification and thawing procedure were similar to those of fresh ovarian fragments, and there was no difference in the number of follicles between fresh ovarian fragments and ovarian tissue fragments immediately after the vitrification and thawing procedure (Fig. 1B). Histological studies revealed that, the number of morphologically intact follicles was significantly lower in the ovarian fragments eight weeks after re-implantation than fresh ovary and ovarian tissue fragments after the vitrification and thawing procedure (Table 1; $p < 0.05$). Follicular development to the antral stage was recorded in all ovarian tissue fragments 8 weeks after re-implantation into the muscular location (Fig. 1C). Atretic follicles were

observed in all three stages of this study (fresh ovarian fragment, ovarian fragment after vitrification-thawing procedure, and ovarian fragment after re-implantation).

The areas (μm^2) of primordial, primary, pre-antral and antral follicles were measured in ovarian tissue fragments before cryopreservation, immediately after vitrification-thawing, and following re-implantation procedures. The areas (μm^2) of primordial, primary, pre-antral, and antral follicles among all ovarian fragments in these stages were not different (Table 2 and Fig. 2; $p > 0.05$).

Discussion

Slow-freezing is the first and most conventional method for fertility preservation.¹ Programmable freezer and use of high amounts of liquid nitrogen for several hr are among main disadvantages of this method.¹ Vitrification is considered as an easy and less expensive method for the simple and quick cryo-storage of ovarian tissue.^{2,17} Limited reports about ovarian tissue's viability and functional restoration after vitrification-thawing are available. Xiao *et al.*, showed that slow-frozen/thawed tissues had significantly lower proportions of morphologically normal follicles than vitrified/warmed tissues.¹⁸

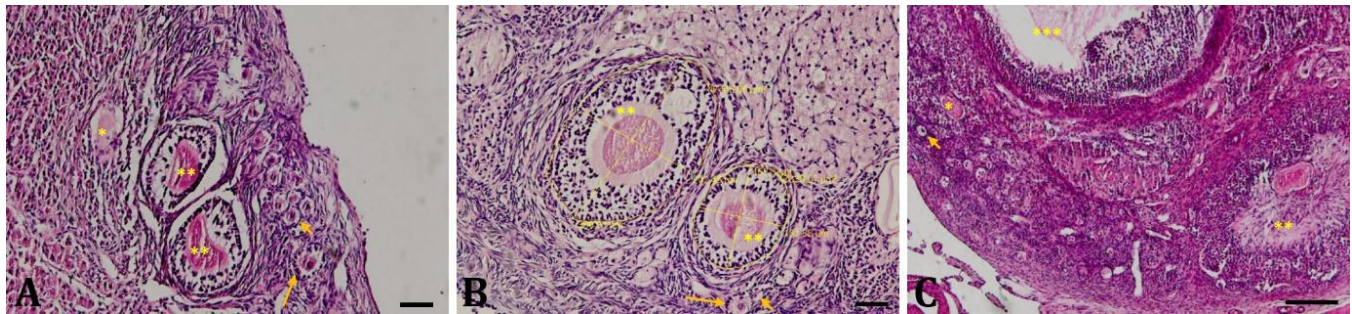


Fig. 1. Ovarian tissue sections stained with Hematoxylin and Eosin. **A)** Fresh ovarian tissue fragment (Bar = 50.00 μm). **B)** Ovarian tissue fragment after vitrification and thawing procedure (area measurement of pre-antral follicles; Bar = 50.00 μm); **C)** Ovarian tissue fragment after re-implantation into the gluteus muscle (Bar = 100 μm). *, **, and *** illustrate atretic, pre-antral and antral follicles, respectively. Short and long arrows demonstrate primordial and primary follicles, respectively.

Table 1. Number of morphologically intact follicles in each group. Data are presented as the median (Q1, Q3).

Type of follicles	Fresh	After vitrification -thawing	After re-implantation
Primordial follicle	107 (151, 67)	93.00 (119, 67)	49.50 (56, 34) *
Primary follicle	55.00 (78, 35)	52.50 (73, 32)	30.50 (46, 20) *
Pre-antral follicle	45.50 (64, 27)	39.50 (60, 33)	25.50 (32, 15) *
Antral follicle	15.00 (23, 12)	14.00 (22, 9)	7.00 (14, 2) *
Total	228.50 (280, 173)	209 (242, 165)	116 (138, 80)

There was a significant difference between number of morphologically intact follicles of ovarian fragment after re-implantation *versus* intact follicular number of the fresh ovary and ovarian fragments after vitrification and thawing procedure.

* Statistically different with other groups ($p < 0.05$).

Table 2. Area (μm^2) of morphologically intact follicles in each group. Data are presented as the mean \pm SD

Type of follicles	Fresh	After vitrification -thawing	After re-implantation
Primordial follicle	1,242.02 \pm 362.17	1,133.41 \pm 310.08	1,336.36 \pm 391.27
Primary follicle	4,236.62 \pm 1,181.02	3,814.63 \pm 1,281.50	3,897.97 \pm 1,184.38
Pre-antral follicle	27,068.28 \pm 4,953.37	30,807.36 \pm 10,003.84	25,986.51 \pm 9,429.05
Antral follicle	422,809.90 \pm 106,064.09	348,705.93 \pm 77,290.74	303,218.16 \pm 91,826.26

No significant difference was recorded among these groups ($p > 0.05$).

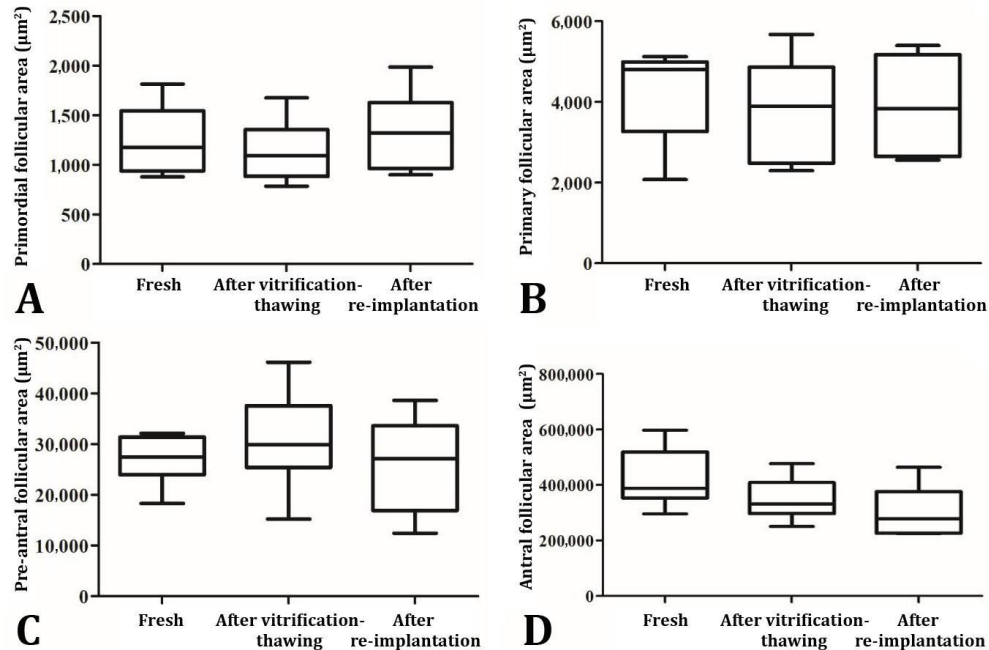


Fig. 2. Boxplot of intact follicular areas (μm^2) of ovarian tissues in all samples. **A)** Primordial follicular area (μm^2) of ovary in the fresh, after vitrification-thawing, and re-implantation samples; **B)** Primary follicular area (μm^2) of ovary in the fresh, after vitrification-thawing, and re-implantation samples; **C)** Pre-antral follicular area (μm^2) of ovary in the fresh, after vitrification-thawing, and re-implantation samples; and **D)** Antral follicular area (μm^2) of ovary in the fresh, after vitrification-thawing, and re-implantation samples. No significant difference between the fresh ovary and ovarian fragments after vitrification and thawing procedure, and following re-implantation was recorded in the intact follicles areas in different stages of development ($p > 0.05$).

No significant differences between the percentages of normal primordial and primary follicles rather than total follicles were recorded in the slow-freezing and vitrification groups.¹⁷ Also, no significant differences between follicular proportions of the primary and secondary stages in slow-frozen and vitrified tissues immediately after warming were reported.² Following short-term *in vitro* culture in a laboratory-based study, no significant differences between slow-frozen/thawed and vitrified/thawed ovarian tissues were found.¹⁹ It was shown that the ovarian tissue morphology and quality of the follicles did not differ among the ovarian tissues after slow-freezing/thawing and vitrification/warming, and non-cryopreserved ovarian tissue. Also, a similar estradiol production in culture was reported in slow-freezing and vitrification.¹ The cryopreservation by vitrification method can result in a good morphology because ice crystal formation in the sample could be avoided. Keros *et al.*, reported that the vitrification procedure preserved the morphological integrity of ovarian stroma much better than controlled-rate freezing.²⁰ The current histological study of ovarian tissue morphology illustrated that the follicular morphology and development in all ovarian tissue fragments immediately after vitrification/thawing were similar to those of fresh ovarian fragments, and there was no difference in the tissue stroma between fresh ovarian fragments and ovarian tissue fragments immediately after vitrification/thawing.

Klocke *et al.*, revealed that the follicular integrity immediately after freezing might not represent the physiological structure and health.¹ According to this information, the vitrified/thawed ovarian tissue was re-implanted into the gluteus muscle to assess the tissue viability and follicular health. Several previous studies have introduced muscle as a promising site for fresh or frozen/thawed ovarian tissue in animal models. The IM (the gluteus muscle) and SC sites effectively preserved follicles of fresh ovarian tissue three weeks after auto-transplantation in rats.¹⁰ Soleimani *et al.*, confirmed the better survival of follicles and higher numbers of blood vessels in the back muscle graft compared to the under kidney capsule graft.¹⁶ Xenotransplantation of frozen/thawed human ovarian tissue revealed the most prominent oval-shaped antral follicles containing a metaphase II oocyte obtained after re-implantation into the back muscle of mice with severe combined immunodeficiency.²¹ Transplantation of fresh ovarian tissue into the back muscle showed recovered morphological integrity of follicles on Day 7.²²

Ovarian samples after vitrification procedure compared to the fresh ovarian tissue did not exhibit histological damage, and the stroma of vitrified ovarian samples was not the same as the slow-frozen ovarian ones.²³ The light microscopy examination of ovarian tissue revealed that the vitrified/warmed ovary maintained the same morphological characteristics as the fresh one, except for

the follicles.²⁴ The high concentrations of EG and DMSO could preserve the morphological integrity and ultra-structure of follicles in the ovarian tissue against osmotic shock after vitrification.²⁵ The histology of re-implanted tissues showed the existence of follicles at different stages, especially ovulatory follicular morphological features similar to those in the fresh ovary, approving active folliculogenesis in the graft in this study. These features verified that vitrification procedure could preserve ovarian tissue fragments. However, the follicular number reduced after transplantation into the muscular locations that may be because of the lack of nutrients caused by delayed re-angiogenesis and ischemic conditions.¹⁰

There is an association between oocyte maturity and follicle size.²⁶ Scheffer *et al.*, reported that there is a good correlation between the number of antral follicles (2 - 10 mm in diameter) and regular cycles and normal fertility in women.²⁷ In this study, the vitrification-thawing process did not change the size of follicles in the different stages of development. Also, follicular development to the antral stage was observed in all Hematoxylin and Eosin-stained ovarian tissue slides.

In conclusion, the results of this investigation revealed that follicular development of auto-transplanted ovary into the gluteus muscle in rabbits occurred after cryopreservation using the ultra-rapid cooling vitrification method; however, high percentage of follicular reduction happened after re-implantation in comparison with fresh and vitrified/thawed tissues. Therefore, based on the previous reports and findings of this investigation, the vitrification-thawing procedure could be regarded practical to preserve ovarian tissue.

Acknowledgments

The authors gratefully acknowledge the support and guidance provided by the Physiology and Surgery Department of Veterinary Clinic of Ferdowsi University of Mashhad, Mashhad, Iran, throughout this research.

Conflict of interest

The authors declare that they have no conflict of interest.

References

1. Klocke S, Bündgen N, Köster F, et al. Slow-freezing versus vitrification for human ovarian tissue cryopreservation. *Arch Gynecol Obstet* 2015; 291(2): 419-426.
2. Kometas M, Christman GM, Kramer J, et al. Methods of ovarian tissue cryopreservation: is vitrification superior to slow freezing? - ovarian tissue methods. *Reprod Sci* 2021; 28(12): 3291-3302.
3. Hossay C, Donnez J, Dolmans MM. Whole ovary cryopreservation and transplantation: a systematic review of challenges and research developments in animal experiments and humans. *J Clin Med* 2020; 9(10): 3196. doi: 10.3390/jcm9103196.
4. de Costa MM, Gonçalves LP, Lemos MS, et al. Investigation on revascularization time and initial damage after transplantation of fresh and cryopreserved ovarian tissue in domestic cats. *Cell Tissue Bank* 2020; 21(2): 303-312.
5. Bahroudi Z, Zarnaghi MR, Izadpanah M, et al. Review of ovarian tissue cryopreservation techniques for fertility preservation. *J Gynecol Obstet Hum Reprod* 2020; 51(2): 102290. doi: 10.1016/j.jogoh.2021.102290.
6. Donnez J, Dolmans MM, Pellicer A, et al. Restoration of ovarian activity and pregnancy after transplantation of cryopreserved ovarian tissue: a review of 60 cases of reimplantation. *Fertil Steril* 2013; 99(6): 1503-1513.
7. Gamzatova Z, Komlichenko E, Kostareva A, et al. Autotransplantation of cryopreserved ovarian tissue-effective method of fertility preservation in cancer patients. *Gynecol Endocrinol* 2014; 30(suppl 1): 43-47.
8. Torre A, Vertu-Ciolino D, Mazoyer C, et al. Safeguarding fertility with whole ovary cryopreservation and microvascular transplantation: higher follicular survival with vitrification than with slow freezing in an ewe model. *Transplantation* 2016; 100(9): 1889-1897.
9. Isachenko V, Lapidus I, Isachenko E, et al. Human ovarian tissue vitrification versus conventional freezing: morphological, endocrinological, and molecular biological evaluation. *Reproduction* 2009; 138(2): 319-327.
10. Tavana S, Rezazadeh Valojerdi M, Eimani H, et al. Auto-transplantation of whole rat ovary in different transplantation sites. *Vet Res Forum* 2017; 8(4): 275-280.
11. Chen CH, Chen SG, Wu GJ, et al. Autologous heterotopic transplantation of intact rabbit ovary after frozen banking at -196°C. *Ferti Steri* 2006; 86(Suppl 3): 1059-1066.
12. Temur I, Ermutlu CŞ, Cihan M, et al. Allo and xenografted ovarian tissue transplantation in rabbits: assessment and comparison of the endocrine characteristics. *Adv Reprod Sci Reprod Health Infertil* 2020; 03: 110. doi: 10.29011/ARRHI110.100010.
13. Abramov Y, Webb AR, Botros SM, et al. Effect of bilateral oophorectomy on wound healing of the rabbit vagina. *Fertil Steril* 2011;95(4): 1467-1470.
14. Benato L, Rooney NJ, Murrell JC. Pain and analgesia in pet rabbits within the veterinary environment: a review. *Vet Anaesth Analg* 2019; 46(2): 151-162.
15. Tavakoli A, Azar AT, Taghizabet N, et al. The effect of kisspeptin on the maturation of human ovarian follicles in culture following vitrification-thawing processes. *JBRA Assist Reprod* 2023; 27(4): 668-676.

16. Soleimani R, Van der Elst J, Heytens E, et al. Back muscle as a promising site for ovarian tissue transplantation, an animal model. *Hum Reprod* 2008; 23(3): 619-626.
17. Zhao Q, Zhang Y, Su K, et al. Vitrification freezing of large ovarian tissue in the human body. *J Ovarian Res* 2019; 12: 77. doi: 10.1186/s13048-019-0553-x.
18. Xiao Z, Wang Y, Li LL, et al. In vitro culture thawed human ovarian tissue: NIV versus slow freezing method. *Cryo Letters* 2013; 34(5): 520- 526.
19. Wang TR, Yan J, Lu CL, et al. Human single follicle growth in vitro from cryopreserved ovarian tissue after slow freezing or vitrification. *Hum Reprod* 2016; 31(4): 763-773.
20. Keros V, Xella S, Hulthenby K, et al. Vitrification versus controlled-rate freezing in cryopreservation of human ovarian tissue. *Hum Reprod* 2009; 24(7): 1670-1683.
21. Soleimani R, Heytens E, Van den Broecke R, et al. Xenotransplantation of cryopreserved human ovarian tissue into murine back muscle. *Hum Reprod* 2010; 25(6): 1458-1470.
22. Youm HW, Lee JR, Lee J, et al. Transplantation of mouse ovarian tissue: comparison of the transplantation sites. *Theriogenology* 2015; 83(5): 854-861.
23. Jones ASK, Shikanov A. Ovarian tissue cryopreservation and novel bioengineering approaches for fertility preservation. *Curr Breast Cancer Rep* 2020; 12(4): 351-360.
24. Fabbri R, Vicenti R, Macciocca M, et al. Morphological, ultrastructural and functional imaging of frozen/thawed and vitrified/warmed human ovarian tissue retrieved from oncological patients. *Hum Reprod* 2016; 31(8): 1838-1849.
25. Tayefi Nasrabadi H, Gavami M, Akbarzadeh A, et al. Preservation of mouse ovarian tissue follicle morphology and ultra-structure after vitrifying in biotechnological protocols. *J Ovarian Res* 2015; 8: 7. doi: 10.1186/s13048-015-0137-3.
26. Bao RM, Taketsuru H, Miyano T. Histological and biological assessment of vitrified ovarian follicles from large animals. *Reprod Med Biol* 2011; 10(4): 211-219.
27. Scheffer GJ, Broekmans FJ, Looman CW, et al. The number of antral follicles in normal women with proven fertility is the best reflection of reproductive age. *Hum Reprod* 2003; 18(4): 700-706.