

Extensive subcutaneous emphysema secondary to axillary penetrating wound in a mule: a case report and literature review

Ghader Jalilzadeh-Amin^{1*}, Masoud Ahmadnejad-Asl-Gavvani², Amin Kheirolahzadeh-Maleki¹, Mahyar Hanafi¹

¹ Department of Internal Medicine and Clinical Pathology, Faculty of Veterinary Medicine, Urmia University, Urmia, Iran; ² Department of Clinical Sciences, Faculty of Veterinary Medicine, Razi University, Kermanshah, Iran.

Article Info	Abstract
Article history: Received: 16 August 2025 Accepted: 15 November 2025 Available online: 15 April 2026	Generalized subcutaneous emphysema (GSE) is an uncommon clinical presentation in equids, typically associated with penetrating trauma and rarely compromising systemic health. This case report documents a 4-year-old working mule presenting with diffuse subcutaneous emphysema secondary to an axillary penetrating wound in the right forelimb. Clinical examination revealed pronounced crepitus without concurrent ataxia, dyspnea, dehydration, or gastrointestinal dysfunction. Diagnostic investigations, including ultrasonography, radiography, complete blood count, paracentesis, and bacterial culture, yielded unremarkable hematological findings and no microbial growth. The wound was managed <i>via</i> local debridement, with adjunct systemic therapy, including penicillin G and flunixin meglumine. Complete resolution occurred within five days under stall rest. This case underscores that generalized subcutaneous emphysema in mules may represent a benign, self-limiting condition when infectious etiologies are excluded. Conservative management, including compulsory rest and anti-inflammatory therapy, can facilitate spontaneous resolution while mitigating risks of pneumothorax or gas gangrene. The rarity of non-infectious generalized subcutaneous emphysema in equids warrants further etiopathological investigation to establish species-specific prognostic criteria.
Keywords: Equine Mule Penetrating trauma Subcutaneous emphysema Wound management	

© 2026 Urmia University. All rights reserved.

Introduction

Axillary wounds in equids are a frequently encountered clinical presentation, with potential to precipitate severe and life-threatening complications, such as subcutaneous emphysema, pneumo-mediastinum, and pneumothorax.^{1,2} Subcutaneous emphysema arises when air infiltrates subcutaneous tissues through perforating wounds, creating palpable crepitus. While localized emphysema is often clinically insignificant, progression to generalized subcutaneous emphysema (GSE) is rare and may induce systemic compromise, including respiratory distress or pneumothorax.³

The pathophysiology of GSE can involve two distinct mechanisms, including gas production by anaerobic infections (*e.g.*, *Clostridium* spp.) or mechanical entrapment of ambient air through a one-way valve effect at the wound site, exacerbated by patient movement.⁴ The latter scenario permits continuous air migration along fascial planes, potentially culminating in pneumothorax or mediastinal emphysema.²

This report describes a rare condition of non-infectious, extensive subcutaneous emphysema in a mule secondary to an axillary penetrating wound. The absence of systemic infection or respiratory dysfunction, coupled with rapid resolution under conservative management, highlights the benign nature of such cases when gas-producing infections are excluded. The clinical trajectory of this case underscores the importance of differentiating infectious *versus* mechanical etiologies to guide therapeutic decisions in equine practice.

Case Description

A 4-year-old male working mule was referred to the Veterinary Teaching Hospital of Urmia University, Urmia, Iran, with an 8-day history of progressive extensive subcutaneous swelling. The owner reported unsuccessful empirical antibiotic therapy before presentation. On admission, the mule exhibited normal vital parameters (heart rate: 21 beats *per* min, temperature: 37.00 °C, and respiratory rate: 15 *per* min) and maintained a good appetite, with no signs of systemic illness. Physical

*Correspondence:

Ghader Jalilzadeh-Amin. DVM, DVSc

Department of Internal Medicine and Clinical Pathology, Faculty of Veterinary Medicine, Urmia University, Urmia, Iran.

E-mail: g.jalilzadeh@urmia.ac.ir



This work is licensed under a Creative Commons Attribution-NonCommercial-ShareAlike 4.0 International (CC BY-NC-SA 4.0) which allows users to read, copy, distribute and make derivative works for non-commercial purposes from the material, as long as the author of the original work is cited properly.

examination revealed diffuse, non-painful subcutaneous crepitus extending to the facial region (Fig. 1), along with a 3.00-cm penetrating axillary wound (Fig. 2) in the right forelimb surrounded by pitting edema.

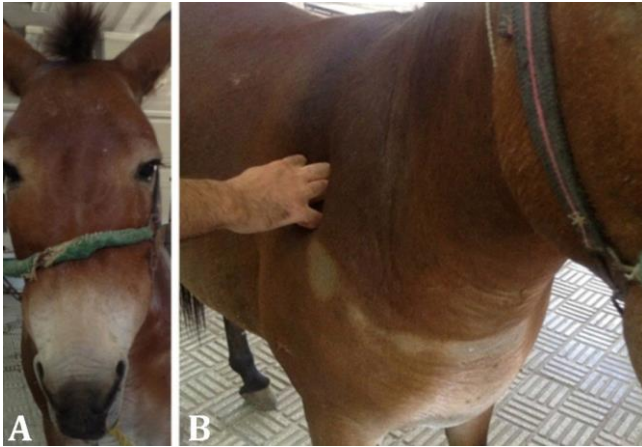


Fig. 1. Clinical presentation of extensive subcutaneous emphysema in a 4-year-old mule. **A)** Facial swelling and crepitus extending to the periorbital regions; **B)** Diffuse subcutaneous air accumulation affects the trunk and limbs, resulting in characteristic body distension.

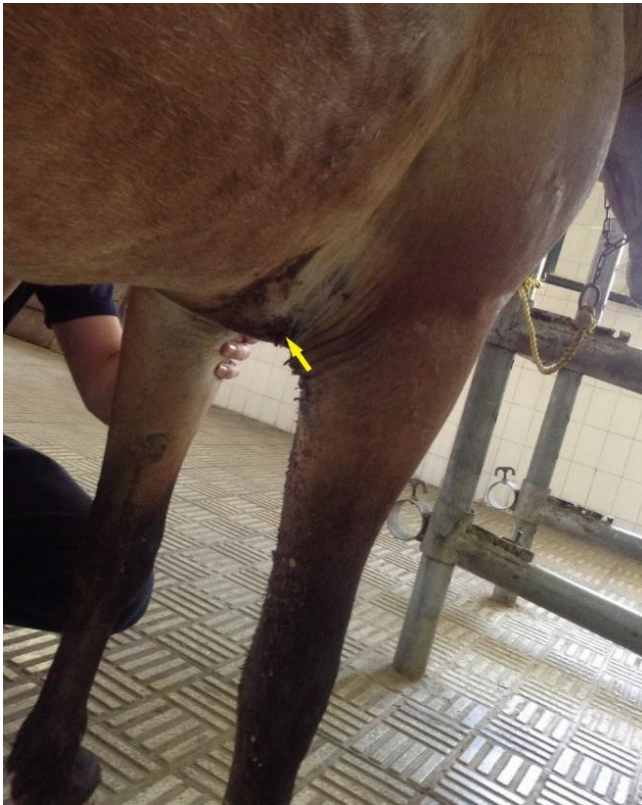


Fig. 2. Penetrating axillary wound (approximately 3.00 cm diameter; arrow) in the right forelimb, showing surrounding tissue edema without apparent purulent discharge.

A supplementary video demonstrates: 1) characteristic crepitus upon palpation of the affected areas, 2) the extent of subcutaneous air distribution throughout the body, 3)

the respiratory pattern and effort during initial examination, and 4) mobility assessment showing gait unaffected by the condition.

Diagnostic evaluation included ultrasonography (Q9 Vet; Chison Medical Technologies Co., Jiangsu, China), demonstrated subcutaneous air accumulation without fluid pockets, and thoracic radiography (Mobile Drive AR 30; Smam X-Ray Equipment, Milan, Italy) that ruled out pneumothorax or mediastinal involvement. Hematological analysis (Celltacc Hematology Analyzer; Nihon Kohden Corp., Tokyo, Japan) showed mild leukocytosis (8,100 *per* μ L) with neutrophilia (60.00%) and lymphocytosis (35.00%). Microbial culture of wound exudate was performed on blood agar (Merck, Darmstadt, Germany) and MacConkey agar (Condalab, Madrid, Spain) under aerobic conditions and incubated at 37.00 °C for 48 hr, yielded no bacterial growth. These findings supported a diagnosis of subcutaneous emphysema secondary to traumatic air entry through the axillary wound.

Treatment consisted of local wound management with saline lavage, povidone-iodine (Azar Arya Darou, Salmas, Iran) anti-sepsis, and topical oxytetracycline (Fanavari Zist Kimia, Arak, Iran) application. Systemic therapy included 20,000 IU kg^{-1} procaine penicillin G (Nasre Fariman, Mashhad, Iran) every 12 hr intramuscularly, administered as a prophylactic measure against secondary bacterial infection and tetanus, given the unknown vaccination status of the patient and high-risk nature of the penetrating wound, along with intravenous 1.10 mg kg^{-1} flunixin meglumine (Nasre Fariman, Mashhad, Iran) once daily for anti-inflammatory and analgesic effects. The mule was strictly confined to prevent further air migration through fascial planes during movement.

Complete resolution of the subcutaneous emphysema occurred within 5 days of treatment initiation. Follow-up examinations over 2 weeks confirmed no recurrence of emphysema or development of complications, such as pneumothorax or secondary infection. This case highlights the efficacy of conservative management for traumatic subcutaneous emphysema in equids when infectious etiologies are excluded, emphasizing the importance of stall rest in preventing disease progression.

Discussion

Generalized subcutaneous emphysema is an uncommon condition in equids, characterized by diffuse air accumulation in subcutaneous tissues, resulting in marked body distension. While localized emphysema often arises from traumatic wounds or surgical interventions, progression to GSE typically occurs when air migrates along fascial planes due to the persistent wound motion, particularly in axillary regions.^{3,5-8} This phenomenon, though rare in dogs, can lead to severe complications, such as pneumothorax or dyspnea.^{9,10} In equids, axillary

wounds are particularly prone to air entrapment due to the repetitive limb movement, creating a one-way valve effect, facilitating subcutaneous air migration to distant sites, including the neck, trunk, and perineum.^{1,2,11}

Clinical differentiation between sterile and infectious emphysema is critical. Gas-producing infections (*e.g.*, clostridial myonecrosis) present with systemic signs, tissue necrosis, and crepitus progressing within hours.⁴ In contrast, extensive emphysema, as observed in this case, manifests as non-painful crepitus without fever, leukocytosis, or bacteremia. Diagnostic imaging (ultrasonography and radiography) and microbial culture are essential to exclude infectious etiologies and complications, like pneumomediastinum or pneumothorax.⁶ The absence of these findings in our patient supported a diagnosis of traumatic GSE, warranting conservative management. It must be acknowledged that the pre-administration of empirical antibiotics by the owner before referral could have suppressed bacterial growth in culture. Therefore, while the clinical presentation, absence of systemic signs, and negative culture collectively support a diagnosis of non-infectious emphysema, a contributory infectious process being partially suppressed cannot be entirely ruled out.

Treatment of GSE focuses on eliminating air entry points and preventing further migration. Local wound care, systemic antibiotics (*e.g.*, penicillin G), and anti-inflammatories (*e.g.*, flunixin meglumine) address secondary infection risks, while strict stall rest is paramount to reduce tissue motion and promote spontaneous resolution.² This approach was proved to be effective in our case, with complete resolution within five days. Notably, early intervention is crucial to prevent progression to life-threatening conditions, as seen in gas gangrene or pneumothorax.^{3,4,12}

This report underscores that GSE in mules, though rare, can be a benign entity when infectious causes are excluded. Conservative management with compulsive rest and symptomatic therapy yields favorable outcomes. Further studies are needed to elucidate species-specific predispositions and optimize treatment protocols for traumatic emphysema in working equids.

Acknowledgments

We extend our gratitude to the veterinary staff at Urmia University, Urmia, Iran, for their assistance in the diagnostic and therapeutic management of this case.

Conflict of interest

The authors declare no conflict of interest.

References

1. Joswig A, Hardy J. Axillary wounds in horses and the development of subcutaneous emphysema, pneumomediastinum and pneumothorax. *Equine Vet Educ* 2012; 25(3): 139-143.
2. Hance SR, Robertson JT. Subcutaneous emphysema from an axillary wound that resulted in pneumomediastinum and bilateral pneumothorax in a horse. *J Am Vet Med Assoc* 1992; 200(8): 1107-1110.
3. Burbidge HM. Penetrating thoracic wound in a Hackney mare. *Equine Vet J* 1982; 14(1): 94-95.
4. Lemfers TR, Vonah RML, Gagliardi B, et al. Systemic clostridiosis due to clostridium perfringens infection in *Equus asinus* - case report. *Ars Vet* 2022; 38(4): 180-184.
5. Ali MA, Mahesha H. Management of subcutaneous emphysema. *Ann Clin Anal Med* 2012; 03(04): 59-60.
6. Caron JP, Townsend HG. Tracheal perforation and widespread subcutaneous emphysema in a horse. *Can Vet J* 1984; 25(9): 339-441.
7. Hassel DM. Thoracic trauma in horses. *Vet Clin North Am Equine Pract* 2007; 23(1): 67-80.
8. Laverty S, Lavoie JP, Pascoe JR, et al. Penetrating wounds of the thorax in 15 horses. *Equine Vet J* 1996; 28(3): 220-224.
9. Akhtardanesh B, Azari O, Vosough D. Uncomplicated generalized subcutaneous emphysema in a dog. *Iran J Vet Surg* 2007; 2(5): 93-98.
10. Nikahval B, Foroud M, Raayat Jahromi A, et al. Generalized subcutaneous emphysema caused by concurrent cricoid cartilage fracture and cricotracheal detachment in a German shepherd dog. *Iran J Vet Res* 2015; 16(2): 226-228.
11. Schoen LM, Al Naem M, Röcken M, et al. Pneumoperitoneum as an uncommon complication after an axillary laceration in a horse. *Vet Med Sci* 2022; 8(2): 546-552.
12. Zache E, Cajueiro JF, Andrade Neto AQ, et al. Anaphylactic shock with pulmonary eosinophilic infiltration due to honeybee attack in a donkey: case report. *Arq Bras Med Vet Zootec* 2021; 73(6): 1346-1350.