

Calculation of intracranial volume in Koçeri sheep by computed tomography scan and Cavalieri principle

Nida Karakaya^{1*}, Betül Kamık², Mustafa Sedat Arslan³

¹ Department of Laboratory and Veterinary Health, Technical Science Vocational High School, Batman University, Batman, Türkiye; ² Department of Anatomy, Faculty of Veterinary Medicine, Bingöl University, Bingöl, Türkiye; ³ Department of Anatomy, Faculty of Veterinary Medicine, Selçuk University, Konya, Türkiye.

Article Info

Article history:

Received: 16 May 2025
Accepted: 10 December 2025
Available online: 15 May 2026

Keywords:

Cavalieri's principle
Computed tomography scan
Intracranial volume
Koçeri sheep

Abstract

The calculation of the cranial cavity volume is important for brain development, pathologies and health status. In recent years, advancements in clinical applications have made volume calculation methods from radiological images more consistent. In this context, it was aimed to calculate the intracranial volume of the Koçeri sheep's skulls using three-dimensional models based on computed tomography (CT) scan sections and stereology. In the study, seven adult female and seven male Koçeri sheep were used. The skulls used were scanned with a 64-detector Multi-Detector CT device with a section thickness of 0.625 mm, 80.00 kV, 200 mA, and 639 mGy specifications. Using the MIMICS 20.1 software, three-dimensional models of the skull region were created and intracranial volumes were measured. The same reference points were measured using the Cavalieri principle. As a result of the study, measurements taken using CT scan showed that the cranial volume in females was $133.09 \pm 7.81 \text{ cm}^3$ and in males was $148.68 \pm 16.25 \text{ cm}^3$. The intracranial volume calculated using the Cavalieri principle was found to be $133.87 \pm 8.43 \text{ cm}^3$ in females and $149.77 \pm 16.74 \text{ cm}^3$ in males. The data were statistically analyzed in terms of two methods and sexual dimorphism. While no difference was found between the methods, a significant statistical difference was determined between the genders. In this context, our study believed to make significant contributions to clinical sciences through accurate management of cranial disease diagnosis and processes and to taxonomy through identification of interspecies differences.

© 2026 Urmia University. All rights reserved.

Introduction

The Koçeri sheep is a breed native to Turkey and is especially raised in the Eastern Anatolia and Southeastern Anatolia Regions. Sheep farming holds an important place in the regional economy. Sheep farming is one of the sources of livelihood for the local people.¹ This breed, a cross between Hamdani and Karakaş, can easily adapt to environmental conditions. Meat, milk, and reproductive yield are quite good. Their physical characteristics, including their heads, legs and necks are dark brown or black in color. Their tails are S-shaped and fatty due to the vertebral structure. They have long ears.²

The skull is examined in two sections: The neurocranium and the splanchnocranium. In vertebrates, it is a structure that mechanically protects the brain, the most important part of the central nervous system, while also supporting the organs that enable the perception of special senses such as vision, hearing, smell, and taste.^{3,4} The analysis of skull morphology allows for the detection of

anatomical relationships between the internal structures of the skull and any abnormal conditions. The analysis of skull morphology allows for the identification of anatomical relationships between the internal structures of the skull and the detection of any abnormal conditions. Additionally, these measurements play an important role in craniofacial development, the evaluation of various pathologies and surgical applications.⁵ The obtained measurements can also be used to calculate the general morphometric indices of the skull. These indices are of great importance in the comparative analysis of the skull structure of individuals or groups.⁶ The intracranial measurements of sheep provide important data for both health monitoring and the determination of genetic and nutritional strategies. These measurements are critical for a healthy sheep population and the sustainability of livestock farming.⁷ Cranium capacity is closely related to developmental characteristics. The understanding of evolutionary processes, the diagnosis of diseases, identification and the monitoring of growth and

*Correspondence:

Nida Karakaya. PhD
Department of Laboratory and Veterinary Health, Technical Science Vocational High School, Batman University, Batman, Türkiye
E-mail: nida.karakaya@batman.edu.tr



This work is licensed under a Creative Commons Attribution-NonCommercial-ShareAlike 4.0 International (CC BY-NC-SA 4.0) which allows users to read, copy, distribute and make derivative works for non-commercial purposes from the material, as long as the author of the original work is cited properly.

development processes have been used as an important parameter.⁸ Different methods have been used in cranium volume measurements and comparative analyses have been conducted.⁹ One of the cranial volume measurement techniques is the Cavalieri principle. The basis of this principle is the idea that the volumes of two objects which are cut by parallel surfaces and create sections with the same area are equal.¹⁰ Research shows that stereological methods are used in various fields in humans and animals.¹¹ It is known that stereological studies are conducted in disciplines such as clinical sciences,¹² anatomy,^{13,14} dentistry¹⁵ and neuroscience.¹⁶

In the fields of medicine and veterinary medicine, computed tomography (CT) scan is frequently used for the diagnosis, treatment, monitoring and management of diseases. Advancements in CT scan systems have enabled the widespread adoption of three-dimensional (3D) modeling studies.^{17,18} The 3D modeling capabilities facilitate volume and structural analyses in stereological studies by using 2D cross-sectional images, thereby enabling more accurate results.^{13,19,20} In the literature, cranial volume calculations have been conducted for different sheep breeds, but no such study has been found on Koçeri sheep. The aim of the study was to calculate the intracranial volumes of Koçeri sheep using CT scan and Cavalieri stereological methods, and to statistically examine the compatibility of the two methods with each other.

Materials and Methods

In the study, the skulls of seven adults male and seven adult female Koçeri sheep, approximately 2 years old, were used. The sheep used were obtained from private slaughterhouses in the provinces of Şanlıurfa and Batman and their surroundings. The animals to be used in the study were examined by veterinarians to ensure they did not have any health issues or anomalies, and healthy animals were preferred. The heads subjected to the maceration process were prepared for imaging. The study was approved by the ethical decision taken by the Harran University Animal Experiments Local Ethics Committee (Decision No. 2025/003/17).

The skulls used in the study were scanned using a 64-detector Multi-Detector CT General Electric - USA device with a slice thickness of 0.625 mm, 80.00 kV, 200 mA settings. The raw DICOM data were transferred to the MIMICS 20.1 Software (Materialise, Leuven, Belgium). The intracranial space boundaries in each section were manually defined using the "Edit Mask" option in the software interface. The intracranial space of each animal was modeled in 3D using the "Calculate Part" option in the software interface. The volume values were selected from the software interface and recorded. Cavalieri principle was applied using tomographic slices for intracranial

volume estimation. Systematic random sampling method was used to select 12 tomographic slices for each sheep cranium. ImageJ Software (National Institutes of Health, Bethesda, USA) was used for volume estimation. An area of 121 mm² was selected *via* the "Grid" option in the ImageJ Software interface. The number of points in each slice was recorded.

The formula " $V = \sum p \times t \times a(p)$ " was used to calculate the intracranial volume. The volume estimation formula based on the Cavalieri principle is used to calculate the volume of complex and irregularly shaped anatomical structures from parallel cross-sections. In this formula, V represents the total estimated volume, while the symbol $\sum p$ refers to the total number of points hitting the area of interest across all examined slices. The letter t denotes the section thickness or the interval between consecutive sections, and $a(p)$ represents the area associated with each point on the point-counting grid. By multiplying these components, the volume of the anatomical structure is mathematically determined.²¹

The coefficient of error was determined by taking the references of Sahin *et al*, Roberts *et al*.^{22,23}

Morphometric measurement points:

1. Maximum length of cranial cavity (MLCC): The distance from the Akrokranion (the highest point of the skull) at the intracranial border to the Lamina Cribrosa within the skull base.
2. Maximum width of cranial cavity (MWCC): The measurement from euryon to euryon (the widest points of the skull) at the intracranial border. This provided an indication of the lateral dimensions of the cranial cavity.
3. Maximum height of cranial cavity (MHCC): The vertical distance measured from the floor of the intracranial compartment to the roof of the intracranial cavity, giving insight into the vertical space available within the skull.
4. Cranial cavity index (Index 1) = $(MWCC \times 100) / MLCC$
5. Length width index (Index 2): $MLCC / MWCC$.^{13,24,25}

In data analysis, the SPSS Software (version 21.0; IBM Corp., Armonk, USA) package was used. After testing the normality of the data, the independent samples t-test was applied for normally distributed data and the Mann-Whitney U test for non-normally distributed data in intergroup comparisons. To evaluate the consistency between the methods, a paired t-test was used and the relationships between the variables were examined using Pearson correlation analysis.

Results

Intracranial volume results obtained using different methods are shown in Tables 1-3. There was no significant difference between the intracranial volumes estimated by Cavalieri's principle and those obtained from 3D models derived from CT scan sections (Fig. 1; $p > 0.05$). A high correlation was observed between the methods (Table 1).

Table 1. Computed tomography scan and Cavalieri principal measurement data (cm³).

Methods	No.	Min.	Max.	Mean	SD	p-value	Correlation
Computed tomography	14	123.22	177.32	140.89	14.68	0.87	0.996
Cavalieri's principle	14	123.00	179.20	141.82	15.17		

Table 2. Intracranial volume data for different sexes in Koçeri sheep using stereology and computed tomography scan methods (cm³).

Methods	Gender	No	Min.	Max.	Mean	SD	p-value	CE
Computed tomography	Female	7	123.22	146.81	133.09	7.81	0.041*	0.032
	Male	7	134.38	177.32	148.68	16.25		
Cavalieri's principle	Female	7	123.00	147.62	133.87	8.43	0.044*	
	Male	7	134.48	179.20	149.77	16.74		

*(p < 0.05): There is a significant difference between the sexes; CE: Coefficient of error.

Table 3. Parameters of intracranial space volume (mm).

Parameters	Gender	No.	Min.	Max.	Mean	SD	p-value
MLCC	Female	7	88.00	97.54	94.26	3.38	0.17
	Male	7	88.83	105.93	97.77	5.38	
MWCC	Female	7	54.00	62.43	60.54	3.03	0.216
	Male	7	58.32	67.54	62.64	2.99	
MHCC	Female	7	48.00	53.77	50.34	1.89	0.248
	Male	7	48.03	58.01	52.02	3.15	
Index 1	Female	7	61.36	67.27	64.21	1.97	0.53
	Male	7	60.54	71.76	65.29	3.93	
Index 2	Female	7	1.49	1.63	1.56	0.05	0.516
	Male	7	1.39	1.65	1.53	0.09	

MLCC: Maximum length of the cranial cavity; MWCC: Maximum width of the cranial cavity; MHCC: Maximum height of the cranial cavity; Index 1: Cranial cavity index; Index 2: Length width index.

The study found a statistical difference between males and females in the results obtained according to CT scan and Cavalieri's principle. The study found a statistical difference between males and females in the results obtained according to CT scan and Cavalieri's principle (Table 2). In the study, no statistically significant difference was found between males and females in intracranial measurements and indices obtained according to CT scan and Cavalieri's principle (Table 3; Fig. 2).

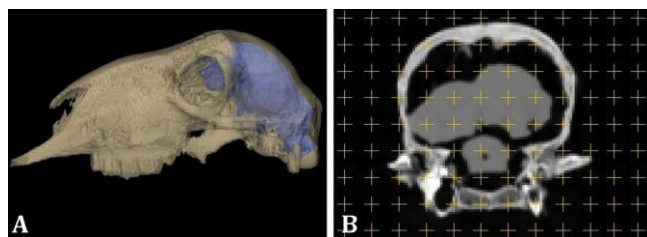


Fig. 1. A) Koçeri sheep intracranial three-dimensional model, B) Cavalieri's principle in a computed tomography scan figure.

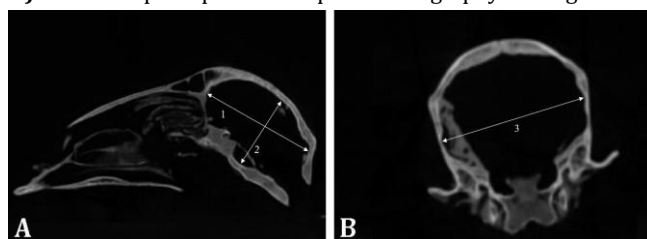


Fig. 2. Morphometric measurement of the cranial cavity. A) Lateral view and B) cranio-caudal view. 1 = Maximum length of the cranial cavity, 2 = Maximum height of the cranial cavity, and 3 = Maximum width of the cranial cavity.

Discussion

Intracranial measurements in sheep have been reported in various studies to understand the morphological features of the skull, evaluate pathological conditions, perform surgical interventions, provide data on the growth and development processes of sheep, compare the intracranial structures of different breeds and be used in the diagnosis and treatment of neurodegenerative diseases.^{12,26-29} Different animal species were used for intracranial volume measurements including 465 ± 80.98 cm³ in yaks,³⁰ 119.31 ± 12.21 cm³ in goats,³¹ it was reported as 28.17 ± 1.19 cm³ in male cats, 26.99 ± 0.57 cm³ in female cats,³² 116.48 ± 9.52 cm³ in Akkaraman sheep, 132.06 ± 8.08 cm³ in Kangal sheep²¹ and 80.51 ± 6.89 cm³ in gazelles.¹³

Computed tomography scan and magnetic resonance imaging methods are vital in the field of medical imaging and are used in many clinical situations. The interpretation of these images plays a critical role in disease diagnosis and the management of the treatment process.^{17,20} In a study measuring the skull volume of Saanen goats, it was reported as 423.60 ± 48.20 cm³ using the CT scan method.³³ The intracranial volume of red deer was reported to be 370 ± 39.00 cm³ using CT scan.³⁴ In our study, the intracranial volume of Koçeri sheep was measured by CT scan method as 133.09 ± 7.81 cm³ in females and 148.68 ± 16.25 cm³ in males.

In recent years, developments in clinical practice have provided better rates of radiological treatments and

volume programming methods. In this context, the Cavalieri Principle has emerged as a frequently used effective method.^{13,22} This principle has allowed for a more accurate calculation of brain volume and other important parameters in complex structures such as the intracranial cavity.^{13,35-38} In Koçyiğit's *et al.*,³⁹ study on Hamdani sheep, the intracranial volume was calculated to be an average of $129.54 \pm 12.16 \text{ cm}^3$ in CT scan models, and an average of $131.55 \pm 9.43 \text{ cm}^3$ in measurements made using the Cavalieri principle. It has been reported that the data from both methods are consistent. In another study, the intracranial volume of goats was determined to be $153.31 \pm 24.06 \text{ cm}^3$, while that of sheep was $128.07 \pm 7.93 \text{ cm}^3$, using 3D models created with CT scan. In the calculations made using the Cavalieri principle, the intracranial volume of goats was determined to be $152.73 \pm 22.73 \text{ cm}^3$, and the volume of sheep was $126.15 \pm 8.38 \text{ cm}^3$, with the results of the two methods found to be parallel.³² In the study conducted by Koçyiğit *et al.*,³² the intracranial volumes of male and female gazelles were determined separately on 3D models created with CT scan and using the Cavalieri principle, and the data were found to be close to each other. In our study, the intracranial volume measured in the 3D models was created using CT scan images of Koçeri sheep that was $140.89 \pm 14.68 \text{ cm}^3$, and the intracranial volume measured using the Cavalieri principle that was $141.82 \pm 15.17 \text{ cm}^3$, with the two methods found to be consistent with each other.

In a study conducted using the craniums of Kivircik sheep, the intracranial volume was calculated to be an average of $133.89 \pm 10.815 \text{ cm}^3$ in females and $136.10 \pm 17.281 \text{ cm}^3$ in males, with the data for both sexes being found to be similar.⁷ In another study conducted by Demircioğlu *et al.*,¹³ although the cranial cavity was measured to be longer in male deer, no significant difference was found between the sexes. In a different study where the intracranial volumes of cats were calculated using the stereological method, it was reported that the intracranial volume data showed statistically significant differences between genders.³⁵ In our study, intracranial volume was measured using computed CT, with females averaging $133.09 \pm 7.81 \text{ cm}^3$ and males $148.68 \pm 16.25 \text{ cm}^3$, and according to the Cavalieri principle, females averaged $133.87 \pm 8.43 \text{ cm}^3$ and males $149.77 \pm 16.74 \text{ cm}^3$. A statistically significant difference between the genders was analyzed.

Cranial morphometric measurement points are important for understanding skull morphology and evaluating the effects of this structure on various pathological conditions. In studies conducted on MLCC, it is one of the parameters measured to understand the skull morphology of different species. Koçyiğit *et al.*,³² measured this parameter as $96.11 \pm 6.77 \text{ mm}$ in Kil goats and $91.43 \pm 1.91 \text{ mm}$ in Tuj sheep, while Karimi *et al.*,⁴⁰ measured it as $9.80 \pm 0.29 \text{ cm}$ in Mehraban sheep, and $101.96 \pm 1.33 \text{ mm}$

in female and $102.67 \pm 1.59 \text{ mm}$ in male Hamdani breed.³⁹ In our study, it was measured as $94.26 \pm 3.38 \text{ mm}$ in female Koçeri breed and $97.77 \pm 5.38 \text{ mm}$ in males. The MWCC data, which is the measurement parameter for the widest part of the skull, were reported as an average of $64.62 \pm 3.90 \text{ mm}$ in male Hamdani breed and $60.26 \pm 1.07 \text{ mm}$ in females³⁹ and $53.40 \pm 1.38 \text{ mm}$ in female deer and $52.41 \pm 1.48 \text{ mm}$ in male deer.¹³ In our study, it was measured as $60.54 \pm 3.03 \text{ mm}$ in females and $62.64 \pm 2.99 \text{ mm}$ in males. The skull measurement parameter MHCC has been reported as $6.86 \pm 0.20 \text{ cm}$ in Mehraban sheep Karimi *et al.*,⁴⁰ and $51.17 \pm 2.12 \text{ mm}$ in female Hamdani sheep and $55.20 \pm 4.84 \text{ mm}$ in male.³⁹ In our study, the MHCC parameter was measured as $50.34 \pm 1.89 \text{ mm}$ in females and $52.02 \pm 3.15 \text{ mm}$ in males (Table 3).

The indices measured for the purpose of evaluating the shape and size of the skull are used in interspecies comparisons. Index1 was measured as $66.16 \pm 5.17 \text{ mm}$ in Kil goats and $67.39 \pm 1.40 \text{ mm}$ in tuj sheep, while in our study, it was measured as $64.21 \pm 1.97 \text{ mm}$ in females and $65.29 \pm 3.93 \text{ mm}$ in males. Index 2 was measured as $1.50 \pm 1.37 \text{ mm}$ in hair goats and $1.48 \pm 0.35 \text{ mm}$ in tuj sheep,³² while in our study, it was measured as $1.56 \pm 0.05 \text{ mm}$ in female ram sheep and $1.53 \pm 0.09 \text{ mm}$ in male ram sheep. When the data were analyzed, no statistically significant difference was observed in the measured parameters.

In the present study, when the intracranial volume data obtained from 3D models and the cavalieri principle were statistically compared, it was determined that both methods could serve as alternatives to each other. With the development of imaging techniques, the widespread use of such volume calculation methods is thought to not only enable the development of accurate and rapid decision-making approaches in clinical applications but also to be effective in determining racial and gender differences.

Conflicts of interest

The authors declare no conflicts of interest.

References

1. Taşkin T, Kandemir C. Current state and future of sheep breeds in Turkey: southeast anatolia region [Turkish]. *J Kadirli Fac Appl Sci* 2022; 2(1): 93-105.
2. Anonymous, Available at www.turkiyekoyunkeci.org/tr/IrkDetay/koceri/30093. Accessed March 15, 2025.
3. World Association of Veterinary Anatomists. *Nomina Anatomica Veterinaria*. 6th ed. Hannover, Germany: Editorial Committee 2017: 105-148.
4. König HE, Liebich HG. *Veterinary anatomy of domestic animals: textbook and color atlas*. Stuttgart, Germany: Schattauer, 2004; 397-414.
5. Schmidt MJ, Langen N, Klumpp S, et al. A study of the comparative anatomy of the brain of domestic

- ruminants using magnetic resonance imaging. *Vet J* 2012; 191(1): 85-93.
6. Canan S, Şahin B, Odaci E, et al. Estimation of the reference volume, volume density and volume ratios by a stereological method: Cavalieri's principle [Turkish]. *Turk Klinikleri J Med Sci* 2002; 22: 7-14.
 7. Omer H, Alpak H. Cranial volume estimation using stereological method in kivircik sheep and its correlations between skull parameters [Turkish]. *Acta Vet Eurasia* 2012; 38(2): 107-119.
 8. Adebisi S. Forensic anthropology in perspective: the current trend. *Int J Forensic Sci* 2009; 4(1): 1-6.
 9. Evin A, Baylac M, Ruedi M, et al. Taxonomy, skull diversity and evolution in a species complex of myotis (Chiroptera: Vespertilionidae): a geometric morphometric appraisal. *Biol J Linn Soc* 2008; 95(3): 529-538.
 10. Cruz-Orive LM, Weibel ER. Recent stereological methods for cell biology: a brief survey. *Am J Physiol* 1990; 258(4 Pt 1): L148-L156.
 11. Keleş AI. Quantitative method used in health field, stereology [Turkish]. *Dicle Med J* 2019; 46(3): 615-621.
 12. Eriksen N, Rostrup E, Andersen K, et al. Application of stereological estimates in patients with severe head injuries using computed tomography scan and magnetic resonance images. *Br J Radiol* 2010; 83(988): 307-317.
 13. Demircioğlu İ, Koçyiğit A, Aydoğdu S, et al. Calculation of the intracranial volume in gazelles (*Gazella subgutturosa*) by stereology and computed tomography [Turkish]. *Harran Uni J Fac Vet Med* 2021; 10(2): 178-183.
 14. Koçyiğit A, Demircioğlu İ, Demiraslan Y, et al. Determining orbital volumes of sheep, goats and gazelles via computed tomography. *Vet Med Sci* 2024; 10(5): e1579. doi: 10.1002/vms3.1579.
 15. Gomes FV, Mayer L, Massotti FP, et al. Low-level laser therapy improves peri-implant bone formation: resonance frequency, electron microscopy, and stereology findings in a rabbit model. *Int J Oral Maxillofac Surg* 2015; 44(2): 245-251.
 16. West MJ. Stereological methods for estimating the total number of neurons and synapses: issues of precision and bias. *Trends Neurosci* 1999; 22(2): 51-61.
 17. Özkadif S. Some veterinary anatomic studies fulfilled using three-dimensional reconstruction [Turkish]. *Batman Uni J Life Sci* 2015; 5(2): 288-295.
 18. Yılmaz O, Koçyiğit A, Kirbaş Doğan G, et al. Three-dimensional morphometric analysis of the metatarsal and phalangeal bones in Van cats. *Anat Histol Embryol* 2025; 54(1): e70006. doi: 10.1111/ah.70006.
 19. Koçyiğit A, Demircioğlu İ, Yılmaz O, et al. Morphometry of the thorax and three-dimensional modelling of the lower respiratory tracts with computed tomography in Van cats. *Acta Vet Brno* 2024; 93: 313-319.
 20. Güzel BC, Koçyiğit A, Demircioğlu İ, et al. Investigating metacarpi of Hamdani sheep via different measurement and modelling methods: a methodological study. *Anat Histol Embryol* 2022; 51(4): 484-491.
 21. Bas-Ekici H, Besoluk K. Calculation of intracranial volume in Akkaraman and Kangal Akkaraman sheep by stereology and computed tomography. *Eurasian J Vet Sci* 2024; 40(3):101-106.
 22. Sahin B, Emirzeoglu M, Uzun A, et al. Unbiased estimation of the liver volume by the Cavalieri principle using magnetic resonance images. *Eur J Radiol* 2003; 47(2): 164-170.
 23. Roberts N, Cruz-Orive LM, Reid NMK, et al. Unbiased estimation of human body composition by the Cavalieri method using magnetic resonance imaging. *J Microsc* 1993; 171(Pt 3): 239-253.
 24. Künzel W, Breit S, Oppel M. Morphometric investigations of breed-specific features in feline skulls and considerations on their functional implications. *Anat Histol Embryol* 2003; 32(4): 218-223.
 25. Onar V, Kahvecioglu KO, Çebi V. Computed tomographic analysis of the cranial cavity and neurocranium in the German shepherd dog (Alsatian) puppies. *Vet Arh* 2002; 72(2): 57-66.
 26. Gündemir O, Duro S, Jashari T, et al. A study on morphology and morphometric parameters on skull of the Bardhoka autochthonous sheep breed in Kosovo. *Anat Histol Embryol* 2020; 49(3): 365-371.
 27. Rubio RR, Bonaventura RD, Kournoutas I, et al. Stereoscopy in surgical neuroanatomy: past, present, and future. *Oper Neurosurg* 2020;18(2): 105-117.
 28. Silver I, Kim C, Mollanji R, et al. Cerebrospinal fluid outflow resistance in sheep: impact of blocking cerebrospinal fluid transport through the cribriform plate. *Neuropathol Appl Neurobiol* 2002; 28(1): 67-74.
 29. Suri S, Kalita A, Sarma K, et al. Craniometry in crossbred Rambouillet sheep of Jammu region. *Indian J Small Rumin* 2003; 9(2): 166-168.
 30. Archana A, Sudhakar LS, Sharma DN. Anatomical studies on the cranial cavity of yak (*Bos grunniens*). *Indian J Vet Anat* 1998; 10: 21-25.
 31. Rodrigues RTS, Matos WCG, Walker FM, et al. Dimensions of the cranium and of the cranial cavity and intracranial volume in goats (*Capra hircus* LINNAEUS, 1758). *J Morphol Sci* 2010; 27(1): 6-10.
 32. Koçyiğit A, Kanik B, Demircioğlu İ, et al. Determination of species-specific differences in intracranial volume of Tuj sheep and hair goats using stereology and computed tomography methods. *Vet Med Sci* 2024; 10(6): e70111. doi: 10.1002/vms3.70111.
 33. Tohidifar M, Goodarzi N, Masoudifard M. Anatomy of the head in the Saanen goat: a computed tomographic and cross-sectional approach. *Anat Sci Int* 2020; 95(3): 408-419.
 34. Logan CJ, Clutton-Brock TH. Validating methods for

- estimating endocranial volume in individual red deer (*Cervus elaphus*). *Behav Process* 2013; 92: 143-146.
35. Koçyiğit A, Demircioğlu İ, Yılmaz O. Calculation of intracranial volume in Van cats by stereological method. *J Erciyes Uni Fac Vet Med* 2024; 21(1): 50-54.
36. Mayhew TM, Gundersen HJ. 'If you assume, you can make an ass out of u and me': a decade of the disector for stereological counting of particles in three-dimensional space. *J Anat* 1996; 188(Pt 1): 1-15.
37. Aydoğdu S, Koçyiğit A. Volumetric calculation of cerebellum in Akkaraman sheep and Hair goat using Cavalieri's principle. *Vet Hekim Der Derg* 2023; 94(2): 144-155.
38. Odacı E, Bahadır A, Yıldırım Ş, et al. Volume estimation using the cavalieri principle on computerized tomography and magnetic resonance images and its clinical application [Turkish]. *Turkiye Klinikleri J Med Sci* 2005; 25(3): 421-428.
39. Koçyiğit A, Demircioğlu İ, Güzel BC. Stereological and computed tomography calculation of intracranial volume in Hamdani sheep. *Anat Histol Embryol* 2024; 53(2): e13021. doi: 10.1111/ahe.13021.
40. Karimi I, Onar V, Pazvant G, et al. The cranial morphometric and morphologic characteristics of Mehraban sheep in Western Iran. *Glob Vet* 2011; 6(2): 111-117.